



Bronchopleural cutaneous fistula due to *Eikenella corrodens*

Fístula cutânea broncopeural causada por Eikenella corrodens

Kin-Sun Wong,¹ Yhu-Chering Huang²

Abstract

Objective: The aim of this paper is to review the subject and to report on and discuss a case of bronchopleural cutaneous fistula due to *Eikenella corrodens*.

Description: A 16-year-old girl was brought to our hospital with fever and blood-tinged sputum 2 weeks prior to her admission. She suffered from neurologic sequelae of herpetic encephalitis and had been bed-ridden since 5 years of age. A longitudinal paraspinal soft mass had been noted in the previous week by her mother. She had been given oral feeding despite frequent choking for the past few years. On palpation, the mass can be squeezed to follow the least resistance of subcutaneous space longitudinally extending to the lower thoracic region. Chest computed tomography scan revealed right lower lobe necrotizing pneumonitis and a pleuro-cutaneous fistula leading to the subcutaneous air locules. A protracted course of antibiotics was prescribed and subcutaneous air trapping decreased in size over 8 weeks.

Comments: *Eikenella corrodens* has increasingly been implicated as a potential causative pathogen in pleuropulmonary infections. Pleuro-cutaneous fistula and abscess formation complicating empyema and necrotizing pneumonitis due to *E. corrodens* infection have not been reported. A bulging thoracic subcutaneous lesion waxes and wanes with respiration suggest the possibility of a pleuro-cutaneous fistula. Treatment of *Eikenella* empyema using antibiotics without surgical decortication requires a prolonged course of antibiotic therapy.

J Pediatr (Rio J). 2005;81(3):265-7: Cutaneous fistula, eikenella, infection, antibiotics.

Introduction

Eikenella corrodens has increasingly been implicated as a potential causative pathogen in pleuropulmonary infections.¹⁻³ However, pleuro-cutaneous fistula with abscess

Resumo

Objetivo: Fazer uma revisão sobre fistula cutânea broncopeural causada por *Eikenella corrodens* e relatar e discutir o caso de uma paciente.

Descrição: Paciente do sexo feminino, 16 anos de idade, foi encaminhada ao nosso hospital em estado febril com histórico de escarro com estrias de sangue há 2 meses; apresentava seqüelas neurológicas de encefalite herpética e estava confinada ao leito desde os cinco anos de idade. A mãe da paciente relatou ter detectado, dias antes, uma massa mole paraespinhal longitudinal. A paciente recebia alimentação via oral apesar da ocorrência de freqüentes engasgamentos nos últimos anos. À palpação, a massa podia ser pressionada até encontrar menor resistência do espaço subcutâneo, estendendo-se longitudinalmente até a região torácica inferior. A tomografia torácica revelou pneumonia necrotizante do lóbulo direito inferior e uma fistula pleurocutânea levando a áreas de cavitação subcutânea. A paciente foi submetida a tratamento prolongado com antibióticos com decrescentes coletas de ar por 8 semanas.

Comentários: A *Eikenella corrodens* tem sido cada vez mais indicada como potencial patógeno causador de infecções pleuropulmonares. Não há relatos de fistula pleurocutânea a formação de abscessos como complicadores de empiema e pneumonia necrotizante causada por infecção de *E. corrodens*. Presença de lesão torácica proeminente que aumenta e diminui com a respiração pode ser uma indicação de fistula pleurocutânea. O tratamento do empiema de *Eikenella* com antibióticos sem decorticação cirúrgica exige um tratamento prolongado com antibioticoterapia.

J Pediatr (Rio J). 2005;81(3):265-7: Fístula cutânea, eikenella, infecção, antibióticos.

formation following empyema and necrotizing pneumonitis (NP) due to *E. corrodens* infections have rarely been described.⁴ We report a 16-year-old girl with long-term malnutrition and recurrent pulmonary aspirations suffered from a paraspinal cold abscess due to pleural empyema and bronchopleuro-cutaneous fistula.

Case report

A 16-year-old girl was brought to our hospital due to fever and blood-tinged sputum 2 weeks prior to her admission. Her mother noted a newly evolving longitudinal paraspinal

1. MD. Assistant professor, Department of Pediatrics, Chang Gung Children's Hospital, Taoyuan, Taiwan.

2. PhD, MD. Associate professor, Department of Pediatrics, Chang Gung Children's Hospital, Taoyuan, Taiwan.

Manuscript received Nov 09 2004, accepted for publication Jan 17 2005.

Suggested citation: Wong KS, Huang YC. Bronchopleural cutaneous fistula due to *Eikenella corrodens*. *J Pediatr (Rio J)*. 2005;81:265-7.

mass in the thoraco-lumbar-sacral region waxing and waning during cough. She has been bed-ridden since 5 years of age after herpetic encephalitis. She had been given oral feeding despite frequent choking for the past several years. She was malnourished, had severe thoraco-lumbar scoliosis and rigid contracture of extremities. Auscultation of the chest showed bilateral crackles and decreased breath sounds in the right lower lung field. Chest radiograph showed infiltrations over bilateral lower lobes and right-sided loculated air in the subpulmonary region. A chest computed tomography (CT) scan revealed right lower lobe NP and pneumothorax. Fifteen ml of frank pus was aspirated from the paraspinal fluctuating mass. A repeated chest CT scan after aspiration and pigtail insertion demonstrated a persistent pleuro-cutaneous fistula leading to the subcutaneous air locules (Figure 1).

A mixed growth of *E. corrodens* and *Capnocytophaga sputigena* was obtained 5 days later. Because her parents refused surgical evacuation of empyema and pleural decortication, only parenteral clindamycin and gentamicin were given empirically. She was given a protracted course of antibiotic for 8 weeks with gradual resolution of subcutaneous air collections.

Discussion

This adolescent girl had cerebral palsy, swallowing dysfunction predisposed her to frequent aspirations and recurrent lower respiratory tract infections. Subsequent contagious spreading of NP and empyema attributed the formation of bronchopleural cutaneous fistula. In contrast to NP in adult patients with poor prognosis, pediatric patients with NP can be treated safely using antibiotic therapy with complete recovery.⁵ Surgical intervention of NP has been limited to decortication of entrapped lung, anaerobic bacteria, and empyema not responsive to chest tube drainage or persistent bronchopleural fistula.⁵

E. corrodens is a normal inhabitant of the human oral cavity, upper respiratory and gastrointestinal tracts and has been an uncommon pathogen of empyema in pediatric patients.^{3,4} Local trauma, chronic illness, neoplastic diseases, prior bowel surgery, Down syndrome, cerebral palsy or mental retardation predisposed to *E. corrodens* infections in such instances.^{3,4} In adult patients, *E. corrodens* were commonly seen in head and neck, pulmonary and intra-abdominal infections. Joshi et al. reported 24 cases of pulmonary infections due to *E. corrodens*, among whom 15 patients had pleural effusion but none had infiltration of the adjoining structures.² Killen et al. first described a 33-year-old man with parapneumonic empyema which was caused by *E. corrodens* with chest wall involvement.⁴

E. corrodens has been shown to have an unusual antibiotic susceptibility pattern, not susceptible to common antimicrobial agents active against most anaerobes, such as clindamycin and metronidazole. Timely surgical drainage of abscesses and adequate debridement of nonviable tissue should be considered in progressive infections caused by *E. corrodens*.⁶ A bulging thoracic subcutaneous lesion waxes and wanes with respiration suggest the possibility of a pleuro-cutaneous fistula, conservative antibiotic therapy and aspiration in such instance may require a prolonged course of antibiotics.

References

1. St John MA, Belda AA, Matlow A, Prober CG. *Eikenella corrodens* empyema in children. *Am J Dis Child*. 1981;135:415-7.
2. Joshi N, O'Bryan T, Appelbaum PC. Pleuropulmonary infections caused by *Eikenella corrodens*. *Rev Infect Dis*. 1991;13:1207-12.
3. Paul K, Patel SS. *Eikenella corrodens* infections in children and adolescents: case reports and review of literature. *CID* 2001;33:54-60.

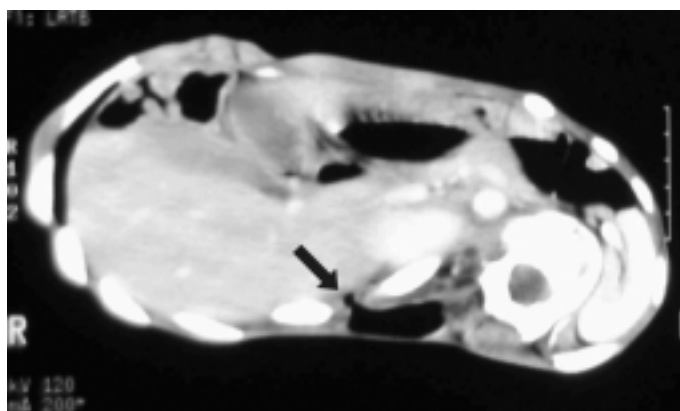


Figure 1 - Chest computed tomography scan demonstrates a pleuro-cutaneous fistula communicating the posterior costophrenic recess and subcutaneous air pocket at the back (arrow)

4. Killen JW, Swift GL, White RJ. Pleuropulmonary infection with chest wall infiltration by *Eikenella corrodens*. Thorax. 1996;51:871-2.
5. Wong KS, Chiu CH, Yeow KM, Huang YC, Liu HP, Lin TY. Necrotizing pneumonitis in children. Eur J Pediatr. 2000;159: 684-8.
6. Kosloske AM, Cushing AH, Shuck JM. Early decortication for anaerobic empyema in children. J Pediatr Surg. 1980;15:422-9.

Correspondence:

Kin-sun Wong
Chang Gung Children's Hospital
5 Fu Hsin Street, Taoyuan, Taiwan
E-mail: pchest@adm.cgmh.org.tw
Phone: 886-3-3281200
Fax: 886-3288957