



Report of the first Brazilian infantile Pompe disease patient to be treated with recombinant human acid alpha-glucosidase

Sandra J. Pereira,¹ Célia R. Berditchevsky,² Suely K. N. Marie³

Abstract

Objective: To describe the first case of infantile Pompe disease to be treated in Brazil.

Description: Pompe disease is a glycogen storage disease related to defects in the acid alpha-glucosidase enzyme, leading to an intracellular accumulation of glycogen, mainly in muscles. Two forms are described: infantile and juvenile. Since 2006, treatment with recombinant human acid alpha-glucosidase has been available. This article describes the first case of infantile Pompe disease treated in Brazil. A girl presented at 2.5 months of age with rapid disease progression, exhibiting severe hypotonia, loss of movements in both upper and lower limbs and hypertrophic cardiomyopathy, progressing to respiratory failure by the age of 7 months. After 10 months of treatment, she exhibited a good clinical response, with remission of the respiratory failure, partial recovery of arm and leg movements and improvement of cardiologic condition.

Comments: Despite its low incidence, infantile Pompe disease is lethal. The availability of an effective treatment has created an urgent need to improve knowledge and early diagnosis of this disease.

J Pediatr (Rio J). 2008;84(3):272-275: Pompe disease, infantile glycogen storage disease type II, myozyme, recombinant human acid alpha-glucosidase, treatment.

Introduction

Pompe disease, also known as glycogenosis type IIa, is characterized by autosomal recessive inheritance and lysosomal glycogen accumulation resulting from a deficiency in the acid alpha-glucosidase enzyme (AAG).^{1,2}

The initial manifestations may occur while still in the uterus or as late as the fifth decade of life and the speed of progression may be rapid and lethal (infantile onset) or extremely slow (late onset).^{1,3,4} Total incidence is estimated at 1:40,000 live births and the infantile form is less common (1:138,000) than the late form (1:57,000).^{1,5} The principal mechanism of Pompey disease is a build-up of intralysosomal glycogen, resulting in major intracellular accumulation. As the disease

progresses, lysosomes rupture and intracellular "glycogen lakes" form, stimulating secretion of other hydrolases into cytoplasm, causing autophagy and cell death.^{1,2} Muscle and nerve tissues are the most affected. In muscle tissues, myofibrils are substituted by glycogen, resulting in reduced contractility, hypotonia and a feeling of hardness on palpation.^{6,7} In nerve tissues, glycogen infiltration affects cerebral Purkinje cells, cortical neurons, the Schwann cells of small nerves in the diaphragm and, primarily, motor neurons in the ventral horn.⁷⁻⁹ Definitive etiologic diagnosis is achieved by AAG enzyme activity assay⁴ and by genotyping using molecular biology techniques. Oligosaccharide chromatography or detection of glycogen GLC4 in urine can also aid with diagnosis.^{1,10}

1. Chefe, Cardiologia Pediátrica, Hospital dos Servidores do Estado do Rio de Janeiro, Rio de Janeiro, RJ, Brazil. Coordenadora, Serviço de Cirurgia Cardíaca, Rede Perinatal Laranjeiras, Rio de Janeiro, RJ, Brazil.
2. Chefe, Setor de Metabolismo, Hospital dos Servidores do Estado do Rio de Janeiro, Rio de Janeiro, RJ, Brazil.
3. Professora associada, Departamento de Neurologia, Faculdade de Medicina, Universidade de São Paulo (USP), São Paulo, SP, Brazil.

Financial support: The patient's medication was donated by Genzyme of Brazil.

No conflicts of interest declared concerning the publication of this article.

Suggested citation: Pereira SJ, Berditchevsky CR, Marie SK. Report of the first Brazilian infantile Pompe disease patient to be treated with recombinant human acid alpha-glucosidase. *J Pediatr (Rio J)*. 2008;84(3):272-275.

Manuscript received Jan 18 2008, accepted for publication Mar 06 2008.

doi:10.2223/JPED.1793

The infantile form has onset within the first months of life and is lethal. On average, the first symptoms appear at 1.6 months of life, diagnosis is made at around 5.3 months and death occurs 2 months after diagnosis, generally within the first 8 months of life in the absence of treatment. Death results from the weakening of the diaphragm and accessory respiratory muscles, accumulated secretions and heart disease.^{1,3} The principal manifestations of the infantile form are: macroglossia, hypertrophic cardiomyopathy, hypotonia and progressive muscle weakness, areflexia, suction and deglutition disorders, pondero-statural growth deficits, progressive respiratory failure, hepatomegaly and retarded motor development. Increases in creatine phosphokinase and aminotransferases are also observed. Furthermore, AAG enzyme activity is less than 1% of normal.¹ Chest X rays reveal significant cardiomegaly, and in infants with hypotonia this is the first sign suggestive of the disease. Initially there is hypertrophic cardiomyopathy, which can progress to dilated cardiomyopathy as cardiac muscle fibers are destroyed, significantly reducing the ejection fraction. As a result of left ventricle hypertrophy, patients may suffer supraventricular tachyarrhythmia and sudden death, particularly in the presence of infection, fever, dehydration and general anesthetic.¹¹ Differential diagnosis of the infantile form should aim to rule out: spinal muscular atrophy type I; neuromuscular diseases; mitochondrial diseases; carnitine deficiency; glycogenosis types III and IV; idiopathic hypertrophic cardiomyopathy, endocardial fibroelastosis and myocarditis.^{1,3,12} The combination of hypertrophic cardiomegaly, hepatomegaly and hypotonia (limp baby) is strongly indicative of the infantile form of Pompe disease.

Until a few years ago, treatment was limited to supportive measures, which were unable to alter the natural history of the disease. Nowadays, Pompey disease is treated by enzyme replacement therapy (ERT) with recombinant human acid alpha-glucosidase (rhGAA, Myozyme[®], Genzyme Co., Cambridge, United States), which has already received approval from the regulatory agencies in Europe (European Medicines Agency) and the United States (Food and Drug Administration).¹³ Enzyme replacement therapy has demonstrated excellent recovery of both cardiac and skeletal muscle involvement, prolonging patient survival and reducing morbidity. The earlier treatment is started, ideally during the first 4 months of life, the better the results are, since the chances of irreversible damage occurring are lower.^{4,9,11,13,14} Trials studying safety have demonstrated that the majority of patients treated develop anti-rhGAA IgG antibodies. Correlations have not been established between these antibodies and mild adverse reactions (urticaria, redness, agitation, vomiting, tachypnea, tachycardia) or with inactivation of the enzyme. Mild allergic reactions can be controlled by reducing the velocity at which the medication is infused. In cases of severe reactions, it is necessary to interrupt infusion and treat symptoms.¹³ Motor physiotherapy is an important adjuvant

treatment since it can correct static and dynamic trunk and limb posture, preventing complications such as pathological fractures and deformities.⁸

Authorization was granted by the Ethics Committee at the Hospital dos Servidores do Estado do Rio de Janeiro, the National Research Ethics Commission and ANVISA.

Case description

A female patient, the daughter of consanguineous parents, was referred to the Pediatric Cardiology Clinic at the Hospital dos Servidores do Estado do Rio de Janeiro, Brazil, in February of 2005, aged to 2.5 months, presenting with tachypnea, tachycardia, hepatomegaly, gastroesophageal reflux and repeat pulmonary infections, in addition to malnutrition. An electrocardiogram showed short PR and wide and high amplitude QRS complexes. An echocardiogram showed hypertrophic cardiomyopathy and liver function test results were abnormal. Based on a suspicion of Pompey disease, the patient underwent a muscle biopsy from the brachial biceps muscle, which revealed vacuolar myopathy, with positive periodic acid-Schiff (PAS) staining and increased lysosomal activity by the acid phosphatase reaction, compatible with glycogen storage myopathy. This etiologic diagnosis was confirmed between 4 and 5 months of age by oligosaccharide chromatography in urine, AAG activation in blood on filter paper of less than 1% and by genotyping, which detected the c.2560C>T/Arg854X mutation in homozygosis.

The patient exhibited suction and deglutition deficits and was fed by nasogastric tube and later via gastrostomy. She progressed with accentuated motor development deficits over the next three to 4 months, with accentuated loss of muscle strength, loss of lower and upper limb movement and respiratory failure, requiring ventilatory support at 7 months of age. This girl was the first patient to be treated with ERT in Brazil, starting at 9 months of age when she already exhibited severe and generalized hypotonia, being only able to move the upper eyelids, rigid musculature and severe hypertrophic cardiomyopathy, with cardiac mass 16 times greater than normal. She was given rhGAA at a dosage of 20 mg/kg/dose via infusion intravenous every 15 days. In the 14th week of treatment (seventh infusion) she suffered a nosocomial infection and treatment was suspended for 6 weeks. At 13 months of age, after nine infusions, the patient demonstrated spontaneous respiratory movements, was able to move her arms and exhibit facial mimicry and both deglutition and cardiomyopathy had improved. There was regression of cardiac hypertrophy, muscle hardening, hepatomegaly, macroglossia and hepatic enzyme levels. After 10 infusions, the improvement in respiratory status was evident, with increased spontaneous respiratory movements and low mechanical ventilation parameters; after the 12th infusion the patient was breathing on noninvasive continuous positive airway pressure (CPAP) and could move her arms. After 10 months' treatment, ventricular mass index had been reduced

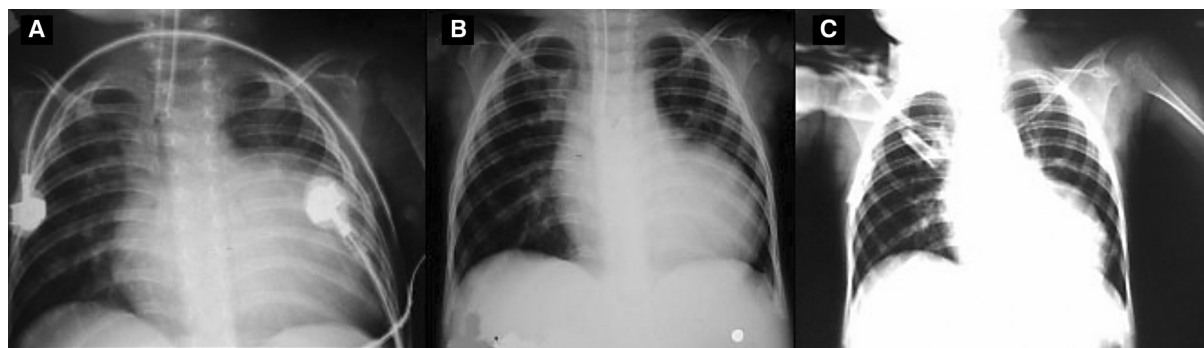


Figure 1 - Radiographic progression of cardiomegaly: A) chest X ray before start of treatment, demonstrating a cardiothoracic index of 0.8 and pulmonary congestion with increased vascularity to the lung apices; B) chest X ray during fourth month of treatment, demonstrating reduction in cardiac area and regression of pulmonary congestion; C) chest X ray from 10th month of treatment, with a cardiothoracic index very close to normal

nine times compared with treatment outset (Figure 1 and Table 1), and cardiac function parameters had almost returned to normal.

Discussion

It is estimated that there may be from 1,000 to 3,500 patients with Pompe disease in Brazil. Although it is uncommon, this disease has a significant impact, with high levels of morbidity and lethality in its infantile form and high morbidity in its late form.^{1,5} In 2006, the introduction of ERT with rhGAA changed the prognosis of this disease, proving capable of stabilizing or even reversing the injuries caused by intracellular glycogen accumulation. This new possibility of treating Pompe disease increases the need for diagnosis and early treatment in order to prevent the appearance of irreversible damage and achieve good patient survival with quality of life.^{12,14,15} We have described the first case of infantile Pompe disease treated with rhGAA in Brazil. Despite the clinical severity and the late institution of treatment, ERT exhibited good results, with regression of signs and symptoms during the 10th month of treatment. Reports in the literature

demonstrate that early initiation of treatment can result in total recovery from the signs and symptoms, allowing the patient a normal life.^{12,14,15}

In view of the new possibility of treatment, Pompe disease should always be considered in the differential diagnosis of severely hypotonic patients less than 6 years old with concomitant hepatomegaly and cardiomegaly and in all neuromuscular cases from 2 years on. Despite the good short term results related here, studies are needed that evaluate the efficacy and safety of this treatment over the long term.

Acknowledgements

The authors are grateful to the clinical team at the pediatric intensive care unit, Hospital dos Servidores do Estado do Rio de Janeiro, who helped with treating the patient, and also for the support of the management of the Pediatrics Department and the Hospital directors. The authors would also like to thank Genzyme of Brazil, who donated the medication used to treat this patient; Dra. Maria Lúcia Costa de Oliveira, from the Innate Errors of Metabolism Laboratory (LABEIM) at UFRJ,

Table 1 - Progression of echocardiographic parameters during treatment with recombinant human acid alpha-glicosidase

| Parameter/date | 7 Jul 2005 | 24 Nov 2005 | 22 May 2006 | 17 Aug 2006 | 8 Nov 2006 |
|---|------------|--------------|---------------|---------------|---------------|
| Age (months) | 5 | 9 | 15 | 18 | 20 |
| Treatment | Untreated | Start of ERT | 12th infusion | 17th infusion | 23rd infusion |
| Septum (mm)* | 15.3 | 21.1 | 13.2 | 12.1 | 10.4 |
| Posterior wall (mm) [†] | 12.7 | 20.2 | 11.5 | 9.5 | 9.3 |
| Ejection fraction (%) [‡] | 63.58 | 49.29 | 77.4 | 83 | 87.41 |
| Cardiac mass index (g/m ²) [§] | 445.8 | 931.9 | 244.0 | 193.3 | 105.8 |

ERT = enzyme replacement therapy.

* Septum = 6 mm.

[†] Posterior wall = 5 mm.

[‡] Ejection fraction ≥ 60%.

[§] Cardiac mass index < 60 g/m².

who carried out the urinary oligosaccharide assays; the Professor Nestor Chamoles Laboratory (Buenos Aires, Argentina), for blood on filter paper assays; and the Cellular and Molecular Biology Laboratory, Neurology Department, Medical Faculty (USP), for the genotyping.

References

- Hirschhorn R, Reuser AJJ. Glycogen storage disease type II. Acid alpha-glycosidase (acid maltase) deficiency. In: Scriver C, Beaudet A, Sly W, Valle D, editors. The metabolic and molecular bases of inherited disease. New York: MacGraw-Hill, 2001. p. 3389-420.
- Online Mendelian Inheritance in Man Glycogen storage disease II. <http://www.ncbi.nlm.nih.gov/entrez/dispomim.cgi?id=232300>. Access: 08/01/2008.
- van den Hout HM, Hop W, van Diggelen OP, Smeitink JA, Smit GP, Poll-The BT, et al. [The natural course of infantile Pompe's disease: 20 original cases compared with 133 cases from the literature](#). Pediatrics. 2003;112:332-40.
- Kishnani PS, Steiner RD, Bali D, Berger K, Byrne BJ, Case LE, et al. [Pompe disease diagnosis and management guideline](#). Genet Med. 2006;8:267-88.
- Martiniuk F, Chen A, Mack A, Arvanitopoulos E, Chen Y, Rom WN, et al. [Carrier frequency for glycogen storage disease type II in New York and estimates of affected individuals born with the disease](#). Am J Med Genet. 1998;79:69-72.
- Raben N, Plotz P, Byrne BJ. [Acid alpha-glycosidase deficiency \(glycogenosis type II, Pompe disease\)](#). Curr Mol Med. 2002;2:145-66.
- Lynch CM, Johnson J, Vaccaro C, Thurberg BL. [High-resolution light microscopy \(HRLM\) and digital analysis of Pompe disease pathology](#). J Histochem Cytochem. 2005;53:63-73.
- Case LE, Kishnani PS. [Physical therapy management of Pompe disease](#). Genet Med. 2006;8:318-27.
- Thurberg BL, Lynch Maloney C, Vaccaro C, Afonso K, Tsai A, Bossen E, et al. [Characterization of pre- and post-treatment pathology after enzyme replacement therapy for Pompe disease](#). Lab Invest. 2006;86:1208-20.
- Kroos MA, Pomponio RJ, Hagemans ML, Keulemans JL, Phipps M, DeRiso M, et al. [Broad spectrum of Pompe disease in patients with the same c.-32-13T->G haplotype](#). Neurology. 2007;68:110-5.
- Ansong AK, Li JS, Nozik-Grayck E, Ing R, Kravitz RM, Idriss SF, et al. [Electrocardiographic response to enzyme replacement therapy for Pompe disease](#). Genet Med. 2006;8:297-301.
- Kishnani PS, Howell RR. [Pompe disease in infants and children](#). J Pediatr. 2004;144:S35-43.
- European Medicines Agency. Myozyme. <http://www.emea.europa.eu/humandocs/Humans/EPAR/myozyme/myozyme.htm>. Acesso: 08/01/2008.
- Klinge L, Straub V, Neudorf U, Voit T. [Enzyme replacement therapy in classical infantile pompe disease: results of a ten-month follow-up study](#). Neuropediatrics. 2005;36:6-11.
- Koeberl DD, Kishnani PS, Chen YT. [Glycogen storage disease types I and II: treatment updates](#). J Inher Metab Dis. 2007;30:159-64.

Correspondence:

Sandra J. Pereira
 Av. Pref. Dulcídio Cardoso, 3080/301, Bloco 3
 CEP 22631-054 – Rio de Janeiro, RJ – Brazil
 Tel.: +55 (21) 2438.6072
 Fax: +55 (21) 2438.6072
 E-mail: sandrajpereira@superig.com.br