



REVISTA BRASILEIRA DE ANESTESIOLOGIA

Official Publication of the Brazilian Society of Anesthesiology
www.sba.com.br



REVIEW ARTICLE

Clinical application of thoracic paravertebral anesthetic block in breast surgeries



Sara Socorro Faria^a, Renato Santiago Gomez^{b,c,*}

^a Universidade Federal de Goiás (UFG), Goiânia, GO, Brazil

^b Department of Surgery, Faculdade de Medicina da Universidade Federal de Minas Gerais (UFMG), Belo Horizonte, MG, Brazil

^c Hospital das Clínicas da Faculdade de Medicina da Universidade Federal de Minas Gerais (UFMG), Belo Horizonte, MG, Brazil

Received 11 July 2013; accepted 29 July 2013

Available online 26 November 2014

KEYWORDS

Paravertebral block;
Breast cancer;
Postoperative
complications

Abstract

Introduction: Optimum treatment for postoperative pain has been of fundamental importance in surgical patient care. Among the analgesic techniques aimed at this group of patients, thoracic paravertebral block combined with general anesthesia stands out for the good results and favorable risk–benefit ratio. Many local anesthetics and other adjuvant drugs are being investigated for use in this technique, in order to improve the quality of analgesia and reduce adverse effects.

Objective: Evaluate the effectiveness and safety of paravertebral block compared to other analgesic and anesthetic regimens in women undergoing breast cancer surgeries.

Methods: Integrative literature review from 1966 to 2012, using specific terms in computerized databases of articles investigating the clinical characteristics, adverse effects, and beneficial effects of thoracic paravertebral block.

Results: On the selected date, 16 randomized studies that met the selection criteria established for this literature review were identified. Thoracic paravertebral block showed a significant reduction of postoperative pain, as well as decreased pain during arm movement after surgery.

Conclusion: Thoracic paravertebral block reduced postoperative analgesic requirement compared to placebo group, markedly within the first 24 h. The use of this technique could ensure postoperative analgesia of clinical relevance. Further studies with larger populations are necessary, as paravertebral block seems to be promising for preemptive analgesia in breast cancer surgery.

© 2014 Sociedade Brasileira de Anestesiologia. Published by Elsevier Editora Ltda. All rights reserved.

* Corresponding author.

E-mail: renatogomez2000@yahoo.com.br (R.S. Gomez).

PALAVRAS-CHAVE

Bloqueio
paravertebral;
Câncer de mama;
Complicações
pós-operatórias

Aplicação clínica do bloqueio anestésico paravertebral torácico em operações de mama**Resumo**

Introdução: O adequado tratamento da dor pós-operatória tem sido de fundamental importância nos cuidados com o paciente cirúrgico. Entre as técnicas de analgesia direcionadas para esse grupo de pacientes, o bloqueio paravertebral torácico combinado com a anestesia geral se destaca pelos bons resultados e pela favorável relação risco-benefício. Muitos anestésicos locais e outros fármacos adjuvantes vêm sendo investigados para uso nessa técnica, com vistas a melhorar a qualidade da analgesia e reduzir os efeitos adversos.

Objetivo: Avaliar a eficácia e a segurança do bloqueio paravertebral em comparação com outros regimes analgésicos e anestésicos em mulheres submetidas a cirurgias para câncer de mama.

Métodos: Revisão integrativa da literatura de 1966 a 2012, feita por meio de termos específicos nos bancos de dados informatizados, de artigos que investigaram as características clínicas e os efeitos adversos e benéficos do bloqueio paravertebral torácico.

Resultados: No período selecionado, foram identificados 16 estudos randomizados que preenchem os critérios de seleção estabelecidos para essa revisão bibliográfica. O bloqueio paravertebral torácico demonstrou uma redução significativa da dor pós-operatória, bem como diminuição da dor durante movimentos do braço após a cirurgia.

Conclusão: O bloqueio paravertebral torácico reduziu a necessidade pós-operatória de analgésicos quando comparado ao grupo placebo, notadamente dentro das primeiras 24 horas. O emprego dessa técnica poderia garantir uma analgesia pós-cirúrgica de relevância clínica. Novos estudos, com maiores grupos populacionais, fazem-se necessários, uma vez que o bloqueio paravertebral parece promissor em analgesia preemptiva para cirurgia de câncer de mama.

© 2014 Sociedade Brasileira de Anestesiologia. Publicado por Elsevier Editora Ltda. Todos os direitos reservados.

Introduction

In recent years, the number of new cases of breast cancer has increased, with an estimated risk of 52 cases per 100 thousand women.¹ Similar to that seen in the world population, breast cancer became the leading cause of mortality among women.^{2,3} About 40% of the patients experience clinically significant acute postoperative pain (>5 on the Visual Analog Scale). This indicates that, as in other surgical procedures, pain treatment is not sufficient. Moreover, acute postoperative pain is a major risk factor for chronic pain development in women following breast surgery.⁴ Therefore, a therapeutic approach to pain after breast cancer surgery is necessary.

Pain control after breast surgery procedures is critical. In addition, there is the need for treatment of postoperative comorbidities, as well as nausea and vomiting, considered as the three main variables related to restriction of hospital discharge in patients undergoing surgical procedures, such as quadrantectomy and mastectomy. Nausea and vomiting are relatively under control with the advent of new antiemetic agents. Paravertebral blockade has been shown to be a viable option to the classical multimodal analgesia, particularly in recent years with the use of opioids and anti-inflammatory drugs.⁵

With the advent of ultrasound to guide anesthetic blocks, its use has become a preoperative assessment tool that predicts the possibility of performing a neuraxial blockade.⁶ The use of this ancillary study can help prevent injury to

structures such as vessels and pleura, as well as allowing accurate injection of local anesthetic under direct visualization. A previous study reported that thoracic paravertebral block (TPVB) may be considered an efficient option that provides anesthesia and postoperative (PO) analgesia for breast surgery, as well as a reduction in pain intensity and nausea and vomiting drug consumption.⁷

Despite the growing number of articles assessing the postoperative management of acute and chronic pain, we found no integrative review assessing the topic in question. Thus, the aim of this study was to assess the efficacy and safety of TPVB, compared with other analgesics and anesthetic regimens, to control post-surgical pain in women undergoing breast cancer surgery.

Methods

Integrative literature review of randomized and/or double-blind studies, with population and hospital approaches. The search was conducted in the following computerized databases during February 2013: PubMed (<http://www.pubmed.gov>), Cochrane Controlled Trials Register (Central, The Cochrane Library – <http://www.thecochranelibrary.com.br>), Embase (<http://www.embase.com>), and Lilacs (<http://lilacs.bvsalud.org>).

The limits used for literature search were: English or Spanish publications, female human, surveyed from 1966 to 2012. The terms used to identify the studies were: breast surgery [MeSH],

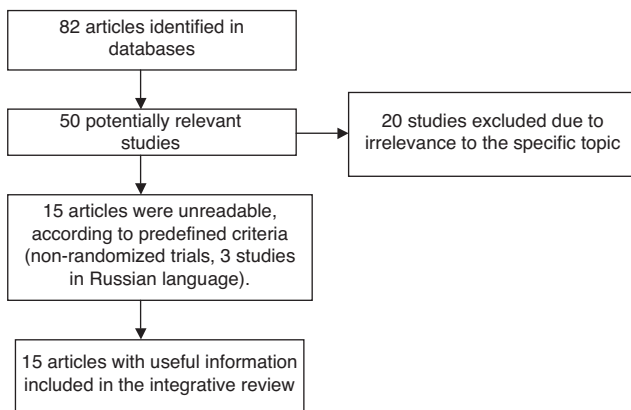


Figure 1 Systematization of the study selection process.

postoperative analgesia [MeSH], postoperative chronic pain [MeSH], paravertebral block [MeSH], and preincisional paravertebral block [MeSH]. The articles that answer the established guiding question and met the following inclusion criteria were adopted: studies assessing effects, clinical characteristics, efficacy, and safety of paravertebral block associated with general anesthesia (GA) and placebo-controlled in women undergoing breast cancer surgery; randomized trials indexed in the above mentioned database from 1966 to 2012, whose abstracts were available online. Exclusion criteria were non-randomized publications, editorials, reviews, and case reports.

The selected articles (Fig. 1) were read in full and analyzed based on a checklist considering the following characteristics: study type and design, year and place; assessment methods; number of participants (inclusion criteria, age group, type of surgery, anesthetic technique, study objectives, control algorithm for pain management, use of fixed drug for postoperative pain in both study groups – TPVB and GA or placebo, prophylaxis against postoperative vomiting); major clinical outcomes.

Results

In total, 82 studies were identified of which 15 met the inclusion criteria (Fig. 1). Selected articles were inserted in a table (Table 1) to be compared. Besides these, other documents have been cited throughout this review for theoretical basis and topic discussion. Studies that clearly did not meet the inclusion criteria were excluded and copies of texts that were potentially relevant were obtained.

Of the 15 studies included, 825 participants undergoing breast surgery were randomly assigned to intervention or control groups. Types of surgery were: tumor removal, mastectomy with or without axillary dissection, quadrantectomy, and mastectomy followed by immediate reconstruction. Only one investigator reported detailed surgical statistics and data operation.⁷ The main inclusion criteria for the research were: adults (over 18 years of age) and ASA physical status class I–III, according to the American Society of Anesthesiologists (ASA). Coagulation disorders, treatment with anticoagulants, allergy to local anesthesia, and infection at the site of injection were the exclusion criteria in all studies.

The technique described by Eason and Wyatt was used to establish TPVB.⁸ Local anesthetic was injected into the paravertebral space between the third and fourth thoracic levels. The most commonly administered local anesthetic was 0.25–0.5% bupivacaine^{7,9–12}; 2% lidocaine was used in one study,¹³ while another tested a mixture of 2% lidocaine, 0.5% bupivacaine with epinephrine, fentanyl, and clonidine.¹⁴ The addition of fentanyl (0.05%) was associated with nausea and vomiting, while clonidine resulted in hemodynamic changes (arterial hypotension).¹⁴ Levobupivacaine (0.1%) administered alone was not effective in the TPVB analgesia after breast surgery. Ropivacaine (0.5%) acted faster and offered increased anesthesia time.^{15–17} In most studies, the main agents used for induction of anesthesia were propofol, fentanyl or sufentanil. Thiopental was used in one study.¹³ Analgesia was provided by bolus administration of various opioids. Different additional analgesics (acetaminophen, traditional nonsteroidal anti-inflammatory drugs [NSAIDs], coxibs) were distributed in all works. In order to reduce the prevalence of PO nausea and vomiting, dexamethasone, ondansetron or both were used before the operation, according to the protocol of each institution. Patients were ventilated with carbon dioxide absorption anesthetic system and positive pressure mechanical ventilation.

There was a significant difference between TPVB and GA groups regarding the scores of “worst postoperative pain” <2 h, 2–24 h, and 24–48 h. Heterogeneity influenced the results at all times. Different data on levels of pain at rest were selected in two studies^{9,10} and there was only a slightly better pain score during all times evaluated in TPVB group, although not statistically significant. There was significant reduction in levels of pain at rest in the period of 2–24 h and at all times during movement. Five studies,^{10–14} which included data from 215 patients, compared levels of acute postoperative (VAS/NRS) pain in women undergoing surgery with TPVB and GA compared with GA alone in the treatment of acute postoperative pain. There was a significant difference in the levels of “worst pain during the postoperative period” between TPVB and control groups (<2 h). Data on the need for rescue analgesia were assessed in four surveys.^{11–14} Fewer patients required opioids during 0–24 h after surgery with TPVB and GA compared with GA alone. TPVB group also required a lesser amount of morphine during the interval of 0–24 h.

Four studies^{11–14} that included 248 women reported accurately the number of patients who suffered adverse effects after surgery with TPVB and GA compared with GA alone. There were no reports of nerve damage or accidental pneumothorax. It is noteworthy that TPVB may have prevented an increase in pain intensity in breast region after radiotherapy in patients who had no axillary dissection. Analgesic effect duration in TPVB and GA group was twice as high when compared to control group (GA).

Discussion

Insufficient and ineffective pain control after surgery for breast cancer may delay recovery, limit hospital discharge, and increase the care costs of surgery, as it can result in chronic pain. Several studies have investigated the

Table 1 Main characteristics of studies of paravertebral blockade in breast cancer surgery.

Author, year, place	Population (n)	Study type	Mean age	Assessment method	Study objective	Anesthetics Blockade route Anesthetic technique details	Complications	Main results
Pusch et al., 1999; Austria	86 42 – GA; 44 – TPVB	Prospective	GA: 53 years; TPVB: 51 years	VAS	Compare TPVB with GA in breast cancer surgery (quadrantectomy, simple mastectomy; mastectomy and axillary dissection)	(1) TPVB: injection of 5% bupivacaine (0.3 mL kg ⁻¹) in the T4 level (maximum dose of 150 mg); (2) GA: IV induction of propofol (2–3 mg kg ⁻¹) and fentanyl (2.3 mcg); (3) SPVB	Vomiting GA: 12 patients; TPVB: 4 patients	TPVB was a good alternative to breast cancer surgery, with good results
Klein et al., 2000; North Carolina	59 30 – GA; 29 – TPVB	Randomized, prospective, and double-blind	GA: 44 years; TPVB: 48 years	VAS; NRS	Compare TPVB with GA in patients undergoing breast reconstruction after breast cancer	(1) TPVB: injection of 4 mL of 0.5% bupivacaine with 1: 400,000 epinephrine in T1–T7 level; (2) GA: induction with propofol (1.5–2 mg kg ⁻¹), fentanyl with isoflurane (1–3 mcg kg ⁻¹), and NO in oxygen; (3) MPVB	Vomiting 30 min – TPVB × GA (p = 0.11); 1 h – TPVB × GA (p = 0.26); 24 h – TPVB × GA (p = 0.04)	TPVB was a surgical alternative to breast reconstruction, offering less pain and nausea compared to GA alone
Terheggen et al., 2002; Arnhem/Netherlands	25 10 – TPVB; 15 – GA	Randomized and prospective	TPVB: 48 years; GA: 51 years	VAS	Evaluate the effectiveness of TPVB with GA in patients undergoing quadrantectomy with or without sentinel lymph node	(1) TPVB: injection of 5% bupivacaine (15–20 mL) with 1: 200,000 epinephrine, through a catheter inserted at T3–T4 interspace. Catheter was removed after surgery; (2) GA: induction with fentanyl (1–1.5 mcg kg ⁻¹) and propofol infusion (3–5 mcg mL ⁻¹); with mixture of oxygen and NO (1:2); (3) SPVB	(1) Dyspnea and hypotension (1 TPVB patient); (2) Accidental pleural puncture (1 TPVB patient); (3) There was no complication in GA group	TPVB risk–benefit showed no favorable results for this type of surgery
Kairaluoma et al., 2004; Finland	60 30 – TPVB; 30 – GA	Randomized	TPVB: 52 years; GA: 55 years	VAS; Motion evaluation (flexion and abduction)	Assess the possible effects of TPVB with bupivacaine or saline before GA	(1) TPVB: bupivacaine 5 mg mL ⁻¹ in T3 level and lidocaine 2–5 mL; (2) GA: induction with propofol (2–3 mg kg ⁻¹). Sevoflurane and 40% oxygen (BIS monitoring). All patients were intubated and ventilated with PPVC; (3) SPVB	Vomiting GA: 17 patients; TPVB: 10 patients; p = 0.069	There was significant difference between groups. TPVB allowed greater movement of the shoulder; less pain (p = 0.019). There was rapid recovery of psychomotor function, as well as ocular control in TPVB group
Iohom et al., 2006; Ireland	29 15 – GA; 10 – TPVB	Randomized and prospective	GA: 59 years; TPVB: 65 years	VAS McGill Pain Questionnaire	Compare the effects of two analgesic regimens and the probability of chronic pain development after breast surgery; Associate plasma concentrations of NO and the likelihood of subsequent development of chronic pain	(1) TPVB: 1% lidocaine (2–5 mL) at T3 level; (2) GA: induction with 8% sevoflurane in 100% oxygen; (3) CPVB	One patient in group CPVB developed Horner's syndrome	There was no association between NO and the subsequent development of chronic pain after axillary dissection
Kairaluoma et al., 2006; Finland	60 30 – TPVB; 30 – GA	Randomized, prospective, and double-blind	–	VAS; POMS; NRS	Determine if TPVB would be associated with less neuropathic pain after surgery for breast cancer (axillary dissection and sentinel node)	(1) TPVB: 0.5% bupivacaine (1.5 mg kg ⁻¹) at T3 level; (2) GA: induction with propofol (2–3 mg kg ⁻¹). Sevoflurane and 40% oxygen (BIS monitoring). All patients were intubated and ventilated with PPVC; (3) SPVB	There were no reports of postoperative complications	Incidence of stiffness in surgical scar, sensory disorders, musculoskeletal symptoms, restriction of shoulder movement, and edema were not significantly different between groups. No patient reported phantom pain

Table 1 (Continued)

Author, year, place	Population (n)	Study type	Mean age	Assessment method	Study objective	Anesthetics Blockade route Anesthetic technique details	Complications	Main results
Burlacu et al., 2006; Ireland	52 (1) 13–19 mL of levobupivacaine – TPVB; (2) 19 mL of levobupivacaine and 0.25% fentanyl – TPVB; (3) 19 mL of levobupivacaine and 0.25% clonidine – TPVB; (4) Control group – GA	Group 1: 51 years; Group 2: 54 years; Group 3: 53 years; Group 4: 57 years	Randomized	VAS; OAA/S	Compare the different postoperative effects between GA and TPVB	(1) Group 1: 19 mL bolus levobupivacaine 0.25% plus 1 mL saline followed by an infusion of levobupivacaine 0.1%; (2) Group 2: 19 mL bolus levobupivacaine 0.25% plus fentanyl 50 mg mg (1 mL de volume) followed by infusion of levobupivacaine 0.05% with fentanyl 1 g mL ⁻¹ (3) Group 3: 19 mL bolus levobupivacaine 0.25% plus clonidine 150 mg (1 mL volume) before surgical incision, followed by an infusion of levobupivacaine 0.05% with clonidine (3 mg mL ⁻¹) at T3 level; (4) GA: induction with propofol (2–3 mg kg ⁻¹); (5) CPVB	Nausea (p = 0.04)	TPVB significantly decreased postoperative pain (quadrantectomy, mastectomy, and mastectomy followed by immediate reconstruction)
Moller et al., 2007; Denmark	79 38 – TPVB; 41 – GA	TPVB: 57.6 years; Placebo: 57.2 years	Randomized, double-blind	NRS; PONV	Examine whether TPVB along with propofol and laryngeal mask performed before GA improves postoperative analgesia in mastectomy with SNB or tumor resection	(1) TPVB: 0.5% ropivacaine (30 mL); lidocaine (5 mL) in transverse process at C7–T5 level; (2) GA: propofol (2–3 mg kg ⁻¹) and fentanyl; (3) MPVB	(1) Nausea – TPVB and GA (7)/placebo (9); (2) Vomiting – TPVB and GA (2)/placebo (1); (3) Sleep disorders – TPVB and GA (8)/placebo (7)	Fentanyl consumption was significantly lower in TPVB group during anesthesia. Pain severity was lower in TPVB group with p < 0.0001
Dabbagh, Elyasi; 2007; Iran	60 30 – TPVB; 30 – GA	–	Randomized	NRS	Compare whether TPVB intervenes positively in pain scores, morphine consumption as rescue analgesia, and length of hospital stay after simple mastectomy	(1) TPVB: injection of 2% lidocaine (15 mL) at T4 level; (2) GA: thiopental with halothane (4–5 mg kg ⁻¹) in a mixture of 1:1 NO and oxygen; (3) SPVB	There were no reports of postoperative complications	TPVB produced fewer complications, decreased pain intensity, can be an alternative method for breast surgery
Sidiripoulou et al., 2007; Italy	48 24 – TPVB; 24 – GA	TPVB: 64 years; GA: 67 years	Randomized	VAS; Motion evaluation (shoulder abduction and external/internal rotation)	Compare GA and TPVB regarding analgesic efficacy and morphine consumption after mastectomy	(1) TPVB: 2% lidocaine (5 mL) at T1–T5 levels; (2) GA: induction of propofol and sufentanil (0.3–0.5 mcg kg ⁻¹); (3) SPVB	Nausea and vomiting (1) TPVB and GA: 5 patients; (2) Placebo: 15 patients	Vomiting was more frequent in GA group. Morphine consumption did not differ between the two groups. Incidence of nausea and vomiting was lower in TPVB group
McElwain et al., 2008; Ireland	37 (1) 15 min: 19; (2) 30 min: 18	(1) 15 min: 55 years; (2) 30 min: 54 years	Prospective, randomized, double-blind	VAS	Compare pain scores between TPVB and GA	(1) 15 min – levobupivacaine – 0.2% (bolus: 3 mL); (2) 30 min – levobupivacaine – 0.2% (bolus: 8 mL); (3) GA: induction of 0.25% levobupivacaine 20 mL bolus (paracetamol 1 g; diclofenac 75 mg; ondansetron 4m; morphine 0.15 mg kg ⁻¹)	Horner's syndrome, asymptomatic bradycardia, infection, catheter disconnection	There were no significant differences in pain intensity and arm movements. There were fewer side effects and greater patient satisfaction with TPVB

Table 1 (Continued)

Author, year, place	Population (n)	Study type	Mean age	Assessment method	Study objective	Anesthetics Blockade route Anesthetic technique details	Complications	Main results
Boughey et al., 2009; United States	80 41 – GA; 39 – TPVB with GA	GA: 57.9 years; TPVB: 53 years	Prospective and randomized	NRS	Evaluate the effect of GA using TPVB. The objective is pain control after mastectomy without plastic reconstruction	(1) TPVB: 1% and 5% ropivacaine with 1:400,000 epinephrine at T1–T6 level; (2) GA: monitored cardiovascular parameters; 3–6 mL of 5% ropivacaine with 1:4,000,000 epinephrine; prophylaxis for nausea and vomiting (dexamethasone, ondansetron, and promethazine) (3) MPVB	There was no difference between groups in scores for nausea and vomiting and other complications	TPVB significantly decreased postoperative pain
Buckenmaier et al., 2010; Pennsylvania	73 (1) 23 – Placebo; (2) 27 – CPVB + GA; (3) 26 – CPVB + GA	(1) Placebo: 58.4 years; (2) 54.3 years; (3) 54.8 years	Prospective, randomized, double-blind, and placebo-controlled	Likert scale; Wong-Baker Faces Pain Rating Scale; McGill Pain Questionnaire; Profile of Mood States; Mc Crockle Symptom Distress Scale	Compare pain, nausea, and mood between TPVB and GA groups	(1) TPVB: 5 mL ropivacaine and 1:400,000 epinephrine at T1–T6 level; (2) GA: lidocaine 1% com epinefrina 1:200,000 (3) CBPV	Seroma (2); Lymphedema (2); Surgical site infection (1); Horner's syndrome (1)	TPVB use was not sustained with significance in this study
Ibarra et al., 2011; Spain	29 14 – GA 15 – GA +TPVB	–	Randomized	VAS; Neurostimulation for TPVB; telephone Interview	Determine the association between anesthetic technique, intensity of postoperative pain, and chronic pain development	(1) Balanced anesthesia with sevoflurane, remifentanyl; (2) Balanced anesthesia with sevoflurane, remifentanyl combined with TPVB	Group 1: (1) Neuropathic pain: 43%; (2) Phantom breast: 21%; (3) Myofascial pain: 33%; SDPM: 50% Group 2: Neuropathic pain: 6.7%; Phantom breast: 0%; Myofascial pain: 43%; SDPM: 6.7%	Neuropathic pain was more frequent in GA patients, with a greater tendency to develop phantom breast sensation
Bhuvanewari et al., 2012; India	48 (G1) 12; (G2) 12; (G3) 12; (G4) 12	G1: 50.7 years; G2: 49.1 years; G3: 48.7 years; G4: 49 years	Randomized	VRS; NRS; PONV	Evaluate the effectiveness of lower concentrations of bupivacaine with or without fentanyl in PVB in patients undergoing breast cancer surgery	(G1) 0.25% bupivacaine + bupivacaine 5 mg mL ⁻¹ ; (G2) 0.25% bupivacaine + bupivacaine 5 mg mL ⁻¹ + fentanyl – 2 mg mL ⁻¹ ; (G3) 0.5% bupivacaine + bupivacaine 5 mg mL ⁻¹ ; (G4) Saline	There were no complications	Results show that analgesic consumption, pain assessment, and duration of analgesia were comparable among patients receiving TPVB with 0.5% bupivacaine and 0.25% bupivacaine + fentanyl. 0.25% bupivacaine + epinephrine combined with fentanyl (2 µg mL ⁻¹) provides excellent postoperative analgesia comparable to 0.5% bupivacaine + epinephrine, with the advantage of a lower toxicity profile when used for a single level of TPVB for breast surgery

GA, general anesthesia; BIS, bispectral index; TPVB, thoracic paravertebral blockade; CPVB, continuous catheter – paravertebral blockade; VAS, Visual Analog Scale; MPVB, multiple injections – paravertebral blockade; mcg, micrograms; NRS, numeric scale; OAA/S, Observer's Assessment of Alertness and Sedation; POMS, Profile of Mood States; NO, nitric oxide; PO, postoperative; PONV, postoperative nausea and vomiting; PPVC, positive pressure controlled volume; SPVB, single injection – paravertebral blockade.

feasibility of TPVB in order to reduce pain after breast surgery.¹⁸ In the analysis of the included studies, we observe considerable evidence that TPVB followed with GA provided better PO analgesia with little adverse effects compared with other analgesic treatment strategies. This

indicates that perioperative TPVB is a viable method, as it reduces postoperative pain with fewer complications. Another important factor for the successful completion of a TPVB is the choice of appropriate anesthetic agents, as well as the technique to manage them and proper dosage.

By analyzing the present review data, it is perceived that there was variation in the concentration of drugs, in the combination with different adjuvants, and in local anesthetics administered into paravertebral space. A controlled study, which assessed 0.5% ropivacaine versus 0.5% bupivacaine in 70 women undergoing modified radical mastectomy, showed that the first offers a faster, broader and lasting sensory block than the second, but the analgesic efficacy of both local anesthetic was equipotent.¹⁹

Postoperative chronic pain, including paresthesia, intercostobrachial neuralgia, and phantom breast pain affect 25–50% of the patients after breast cancer surgery.²⁰ The predictive risk factors for the onset of persistent neuropathic pain after this type of surgery are the adjuvant radiotherapy and chemotherapy, pain prior to surgery, type of surgery, nerve damage – intercostobrachial nerve, psychosocial factors, anxiety, depression, and young women.²⁰ A moderate decrease²¹ was seen in the aforementioned studies in postoperative chronic pain between 6 and 12 months in patients who received GA with TPVB compared with GA alone. However, it must be analyzed with caution due to the limited number of included trials and heterogeneity. Therefore, there is need to develop further studies to investigate the possible preventive role of TPVB in the incidence of chronic postoperative pain in patients who underwent breast surgery.

The surgical tissue damage also results in spinal sensitization; for example, metabolic activation and hypersensitivity of the spinal cord nociceptive neurons, expansion of sensory receptive fields, and changes in processing innocuous stimuli. These postoperative neuroplastic changes underlie the development of “pathological” pain, which is characterized both by hyperalgesia (primary or secondary) and allodynia.²¹ Thus, an effective analgesia before the nociceptive stimulus could reduce the risk of chronic postoperative pain syndrome.

The pain experienced during movement was lower when COX-2 inhibitors were not administered and none of these patients developed mammary pain syndrome after surgery. The evidence suggests a substantial increase in the levels of COX-E in the spinal cord after peripheral damage.²² COX-2 inhibition, if applied immediately after surgery, can help reduce the prostanooids production and act on neuronal changes that may contribute to the development of chronic pain.^{12,22}

Nitric oxide (NO) is related to both the development and maintenance of hyperalgesia.²³ Three optional mechanisms have been proposed to explain the nociceptor sensitization induced by NO: (1) NO may increase the release of an algescic substance, such as prostaglandin E₂; (2) NO may inhibit the action of an endogenous antinociceptive substance that acts on peripheral nociceptors; or (3) NO may act directly on nociceptors.^{24,25} In addition, pharmacological studies indicate that central sensitization is at least partially mediated by the activation of N-methyl-D-aspartate receptors, which could lead, ultimately, to the production of NO, although the link between the local and systemic production is not defined. The perioperative profile of NO after breast surgery was similar to other profiles in different types of surgeries (18), with a marked decrease 12 h after the operation.¹² The fact that no other difference between groups was detected can be attributed to the small number of patients per group.

A retrospective analysis of 129 patients undergoing mastectomy and axillary dissection showed a low risk of cancer recurrence in those who received TPVB with GA compared with those who received GA alone. Relevant evidence indicates that the surgical procedure, which releases cancer cells directly into the circulation; volatile anesthetics, which weaken immunity; postoperative use of opioids; pro-angiogenic factors; and pain itself are all associated with cancer recurrence.²⁵ Studies have reported a reduced need for the use of postoperative morphine in patients of TPVB group,²⁶ indicating a potential pathophysiological mechanism for a lower recurrence of breast cancer. Added to these factors is the hypothesis that some local molecular mechanism in peripheral nerves may be responsible for increasing the duration quality of the local anesthetic block and pain control after addition of opioids. However, this result should be analyzed with caution,^{27–30} due to the limited number of included studies and significant heterogeneity.

The results of this review are limited because of the clinical heterogeneity of the included studies. First, pain levels were calculated both by Visual Analog Scale (VAS) and numerical rating scale (NRS). Only three studies explicitly detailed pain during rest and arm movement (flexion, abduction, external and internal rotations). Second, the pain scores depend on the extent of breast surgery. This indicates that less invasive operations, such as segment intersections, produced lower levels of pain than mastectomy with axillary dissection. Third, the type of local anesthetics and adjuvants, including clonidine or opioids, varied among studies, which may have influenced the assessment of pain severity. However, there is evidence that ropivacaine, bupivacaine, levobupivacaine, and lidocaine provide similar analgesia and the administration of adjuvants did not improve the analgesic efficacy. Nevertheless, data are lacking concerning the proper dosage of local anesthetic used in TPVB in breast surgery. Fourth, the different techniques for establishing paravertebral blockade (SPVB, MPVB, and TPVB – single injection paravertebral blockade, multiple injections paravertebral blockade, thoracic paravertebral blockade, respectively) may play an important role in the efficacy of analgesia. We found a trend toward more prolonged analgesia after the combination of GA and TPVB, which in turn generated a reduced need for opioid consumption, as it reduced the algesic sensation.

Conclusion

There is a number of evidence on the benefits offered by the combination of TPVB and GA in adequate control of postoperative pain, lower consumption of opioids, and few adverse effects (nausea, vomiting, pleural puncture, pneumothorax) compared with other treatment regimens with analgesics. However, these results are limited by clinical heterogeneity due to the application of different procedures (surgical, anesthetic and analgesic doses). Further studies are needed to determine the benefits of the technique.

Conflicts of interest

The authors declare no conflicts of interest.

References

1. Jemal A, Bray F, Center MM, et al. Global cancer statistics. *CA Cancer J Clin.* 2011;61:69–90, <http://dx.doi.org/10.3322/caac.20107>.
2. World Health Organization. International agency for research on cancer. *World Cancer Report.* Lyon: IARC Press; 2009.
3. Brasil. Ministério da Saúde. Estimativa 2012: incidência de câncer no Brasil. Rio de Janeiro: Instituto Nacional de Câncer José Alencar Gomes da Silva. Available from: <http://www.inca.gov.br/estimativa/2012/estimativa20122111.pdf> [accessed 2013].
4. Peuckmann V, Ekholm O, Rasmussen NK, et al. Chronic pain and other sequelae in long-term breast cancer survivors: nationwide survey in Denmark. *Eur J Pain.* 2009;13:478–85.
5. Vila H Jr, Liu J, Kavasmanek D. Paravertebral block: new benefits from an old procedure. *Curr Opin Anaesthesiol.* 2007;20:316–8.
6. Chin KJ, Chan V. Ultrasonography as a preoperative assessment tool: predicting the feasibility of central neuraxial blockade. *Anesth Analg.* 2010;110:252–3.
7. Pusch F, Freitag H, Weinstabl C, et al. Single-injection paravertebral block compared to general anaesthesia in breast surgery. *Acta Anaesthesiol Scand.* 1999;43:770–4.
8. Eason MJ, Wyatt R. Paravertebral thoracic block – a reappraisal. *Anaesthesia.* 1979;34:638–42.
9. Kairaluoma PM, Bachmann MS, Korpinen AK, et al. Single-injection paravertebral block before general anesthesia enhances analgesia after breast cancer surgery with and without associated lymph node biopsy. *Anesth Analg.* 2004;99:1837–43.
10. Kairaluoma PM, Bachmann MS, Rosenberg PH, et al. Preincisional paravertebral block reduces the prevalence of chronic pain after breast surgery. *Anesth Analg.* 2006;103:703–8.
11. Terheggen MA, Wille F, Borel Rinkes IH, et al. Paravertebral blockade for minor breast surgery. *Anesth Analg.* 2002;94:355–9.
12. Iohom G, Abdalla H, O'Brien J, et al. The associations between severity of early postoperative pain, chronic postsurgical pain, and plasma concentration of stable nitric oxide products after breast surgery. *Anesth Analg.* 2006;103:995–1000.
13. Dabbagh A, Elyasi H. The role of paravertebral block in decreasing postoperative pain in elective breast surgeries. *Med Sci Monit.* 2007;13:CR464–7.
14. Burlacu CL, Frizelle HP, Moriarty DC, et al. Fentanyl and clonidine as adjunctive analgesics with levobupivacaine in paravertebral analgesia for breast surgery. *Anaesthesia.* 2006;61:932–7.
15. Moller JF, Nikolajsen L, Rodt SA, et al. Thoracic paravertebral block for breast cancer surgery: a randomized double-blind study. *Anesth Analg.* 2007;105:1848–51.
16. Sidiropoulou T, Buonomo O, Fabbi E, et al. A prospective comparison of continuous wound infiltration with ropivacaine versus single-injection paravertebral block after modified radical mastectomy. *Anesth Analg.* 2008;106:997–1001.
17. Boughhey JC, Goravanchi F, Parris RN, et al. Prospective randomized trial of paravertebral block for patients undergoing breast cancer surgery. *Am J Surg.* 2009;198:720–5.
18. Klein SM, Bergh A, Steele SM, et al. Thoracic paravertebral block for breast surgery. *Anesth Analg.* 2000;90:1402–5.
19. Schnabel A, Reichl SU, Kranke P, et al. Efficacy and safety of paravertebral blocks in breast surgery: a meta-analysis of randomized controlled trials. *Br J Anaesth.* 2010;105:842–52.
20. Hura G, Knapik P, Misiolek H, et al. Sensory blockade after thoracic paravertebral injection of ropivacaine or bupivacaine. *Eur J Anaesthesiol.* 2006;23:658–64.
21. Gartner R, Jensen MB, Nielsen J, et al. Prevalence of and factors associated with persistent pain following breast cancer surgery. *J Am Med Assoc.* 2009;302:1985–92.
22. Brennan TJ. Frontiers in translational research. *Anesthesiology.* 2002;97:535–7.
23. Samad TA, Sapirstein A, Woolf CJ. Prostanoids and pain: unravelling mechanisms and revealing therapeutic targets. *Trends Mol Med.* 2002;8:390–6.
24. Salter M, Strijbos PJ, Neale S, et al. The nitric oxide-cyclic GMP pathway is required for nociceptive signaling at specific loci within the somatosensory pathway. *Neuroscience.* 1996;73:649–55.
25. Sun MF, Huang HC, Lin SC, et al. Evaluation of nitric oxide and homocysteine levels in primary dysmenorrheal women in Taiwan. *Life Sci.* 2005;76:2005–9.
26. Sessler DI. Long-term consequences of anesthetic management. *Anesthesiology.* 2009;111:1–4.
27. Buckenmaier CC 3rd, Kwon KH, Howard RS, et al. Double-blinded, placebo-controlled, prospective randomized trial evaluating the efficacy of paravertebral block with and without continuous paravertebral block analgesia in outpatient breast cancer surgery. *Pain Med.* 2010;11:790–9.
28. Bhuvanewari V, Jyotsna W, Preethy JM, et al. Post-operative pain and analgesic requirements after paravertebral block for mastectomy: a randomized controlled trial of different concentrations of bupivacaine and fentanyl. *Indian J Anaesth.* 2012;56:34–9.
29. Ibarra Martí ML, S-Carralero G-Cuenca M, Vicente Gutiérrez U, et al. Comparación entre anestesia general con o sin bloqueo paravertebral preincisional con dosis única y dolor crónico postquirúrgico, en cirugía radical de cáncer de mama. *Rev Esp Anestesiol Reanim.* 2011;58:284–90.
30. McElwain J, Freir NM, Burlacu CL, et al. The feasibility of patient-controlled paravertebral analgesia for major breast cancer surgery: a prospective, randomized, double-blind comparison of two regimens. *Anesth Analg.* 2008;107:665–8.