

# Diagnosis and treatment of hyperfiltering blebs

## *Diagnóstico e tratamento de bolsas fistulantes hiperfuncionantes*

Sebastião Cronemberger<sup>1</sup>, Daniela Silveira de Faria<sup>2</sup>, Jamile Moreira Reimann<sup>3</sup>, Heloisa Andrade Maestrini<sup>4</sup>, Nassim Calixto<sup>1</sup>

### ABSTRACT

**Purpose:** To report on a new treatment for hyperfiltering bleb as well as its diagnostic criteria. **Methods:** Twenty eyes with hypotony due to hyperfiltering bleb caused by trabeculectomy with mitomycin C were treated with bleb resection. The diagnosis of hyperfiltering bleb followed these criteria: intraocular pressure lower than six mmHg (Goldmann tonometer); no inflammation in the anterior segment; presence of an elevated and/or diffuse and avascular bleb with or without microcysts; negative Seidel test; no ciliochoroidal detachment found with ultrasound biomicroscopy. We registered the following data pre and post operatively: type of glaucoma, visual acuity, bleb aspect and fundoscopic findings. A successful resolution of hypotony was achieved when intraocular pressure ranged from six to 14 mmHg with or without antiglaucomatous medication. **Results:** At a minimum follow-up of 19 months ocular hypotony had been reversed in all eyes. At the last exam, intraocular pressure varied from eight to 14 mmHg in 18 (90%) eyes; 12 (66.7%) eyes had no medication and six (33.3%) used antiglaucomatous medication. In two (10%) eyes, another trabeculectomy was necessary to control intraocular pressure. Hypotonic maculopathy developed preoperatively in seven eyes and was reversed after bleb resection. Visual acuity improved in 15 (75%) eyes but did not change in five (25%). **Conclusion:** Bleb resection is a safe and adequate treatment for ocular hypotony due to hyperfiltering bleb. It also restores vision in a considerable number of patients. The diagnosis of hyperfiltering bleb must follow rigorous criteria.

**Keywords:** Trabeculectomy/adverse effects; Mitomycin/therapeutic use; Ocular hypotension; Treatment outcome.

<sup>1</sup>Full Professor, Faculdade de Medicina da Universidade Federal de Minas Gerais – UFMG – Belo Horizonte (MG), Brazil;

<sup>2</sup>MD, Glaucoma service, Hospital São Geraldo – Hospital das Clínicas, Universidade Federal de Minas Gerais – UFMG – Belo Horizonte (MG), Brazil;

<sup>3</sup>Especialista em Oftalmologia pelo Hospital São Geraldo - Hospital das Clínicas da Universidade Federal de Minas Gerais – UFMG – Belo Horizonte (MG), Brazil;

<sup>4</sup>PhD, Faculdade de Medicina, Universidade Federal de Minas Gerais – UFMG – Belo Horizonte (MG), Brazil;

Study carried out at Department of Ophthalmology, Glaucoma Service, Hospital São Geraldo, Hospital das Clínicas, Universidade Federal de Minas Gerais – UFMG – Belo Horizonte (MG), Brazil;

**The authors have no commercial interest in the products and equipment used in this study**

Recebido para publicação em: 24/9/2010 - Aceito para publicação em 27/4/2011

## RESUMO

**Objetivo:** Relatar os resultados de uma nova técnica para o tratamento de bolsa hiperfuncionante, assim como seus critérios diagnósticos. **Métodos:** Vinte olhos (20 pacientes) com hipotonia ocular causada por bolsa hiperfuncionante após trabeculectomia com mitomicina C foram tratados com ressecção da bolsa. O diagnóstico de bolsa hiperfuncionante obedeceu aos seguintes critérios: pressão intraocular inferior a seis mmHg (tonometria de Goldmann); ausência de inflamação do segmento anterior ocular; presença de bolsa fistulante elevada e/ou difusa e avascular com ou sem microcistos; teste de Seidel negativo; ausência de descolamento ciliocoroidiano ao exame de UBM. Foram registrados no pré e pós-operatório: o tipo de glaucoma, a acuidade visual, o aspecto da bolsa e os achados oftalmoscópicos. A resolução da hipotonia foi alcançada quando a pressão intraocular variou de seis a 14 mmHg sem ou sob medicação tópica antiglaucomatosa. **Resultados:** No seguimento mínimo de 19 meses, a hipotonia ocular foi revertida nos 20 olhos. No último exame, a pressão intraocular variou de oito a 14 mmHg em 18 (90%) olhos; 12 (66,7%) olhos sem medicação e seis (33,3%) olhos sob medicação tópica. Em dois (20%) olhos foi necessário nova trabeculectomia para controle da pressão intraocular. Maculopatia hipotônica foi diagnosticada no pré-operatório em sete olhos e foi revertida em todos eles após a ressecção da bolsa. A acuidade visual melhorou em 15 (75%) olhos e não se alterou em cinco (25%). **Conclusão:** A ressecção da bolsa é eficaz no tratamento da hipotonia ocular consequente a sua hiperfunção. Esse procedimento também recupera a visão num considerável número de pacientes. O diagnóstico de bolsa hiperfuncionante deve obedecer a critérios rigorosos.

**Descritores:** Trabeculectomia/efeitos adversos; Mitomicina/uso terapêutico; Hipotensão ocular; Resultado de tratamento

## INTRODUCTION

**T**rabeculectomy has proved effective in reducing intraocular pressure (IOP) and delaying the progression of glaucoma<sup>(1-4)</sup>. This surgery can bring benefits such as improvement in quality of life resulting from the reduction or total discontinuation of medications. It may even lead to lower and safer IOP levels, particularly for patients in an advanced stage of glaucoma<sup>(1)</sup>. In cases of refractory glaucoma, antimetabolites are used to improve trabeculectomy results. However, antimetabolites can cause complications such as postoperative ocular hypotony, which may be associated with shallow or a flat anterior chamber, ciliochoroidal effusion, cataract and maculopathy<sup>(5)</sup>.

To date, the correct diagnosis and ideal treatment of hyperfiltering bleb have not been conclusively established.

Intrableb autologous blood injection<sup>(6-9)</sup>, free conjunctival autografts<sup>(10)</sup>, free conjunctival patch<sup>(11)</sup>, fascia lata<sup>(12)</sup>, Nd:YAG laser<sup>(13,14)</sup>, compression suture<sup>(15)</sup>, and wide-diameter contact lenses<sup>(16-18)</sup> have all been used to treat ocular hypotony with varied degrees of effectiveness, thereby proving a lack of consensus on this subject.

The surgical approach to hyperfiltering bleb dates back to the 1960s<sup>(19-22)</sup>. In 2004 we published a five-case pilot study of ocular hypotony<sup>(23)</sup> in which criteria for the correct diagnosis of hyperfiltering bleb and its treatment were established.

The purposes of this study are: 1) to report results

of treatment in a series of patients with ocular hypotony caused by hyperfiltering bleb who underwent bleb resection; 2) to substantiate criteria<sup>(23)</sup> for the correct diagnosis of hyperfiltering bleb.

## METHODS

Twenty eyes (20 patients) with ocular hypotony after trabeculectomy with mitomycin C (MMC) were diagnosed with hyperfiltering bleb (HB) after being examined by the same doctor (SC). Five eyes in this paper were included in a smaller pilot study previously published.<sup>(23)</sup> This study was performed according to the tenets of the Declaration of Helsinki and approved by the ethics committee of the Federal University of Minas Gerais. All patients were informed of the purposes of the study and gave informed consent. The diagnosis of HB was made with the following criteria: IOP lower than six mmHg;<sup>(23)</sup> no inflammation in the anterior segment; elevated and/or diffuse and avascular bleb with or without microcysts (Figure 1A); negative Seidel test (absence of aqueous humour leakage in the Seidel test, even after slight compression of the ocular globe); no ciliochoroidal detachment (CCD) found on the ultrasound biomicroscopy (UBM) carried out in the superior, inferior, nasal and temporal quadrants. Once criteria had been fulfilled, we attempted to normalize the IOP with 1% atropine (one drop every 12 hours) and 0.1% dexamethasone (one drop every six hours) for at least 30 days<sup>(24)</sup>. As clinical treatment failed to reverse ocular hypotony, all patients were submitted to HB resection by the same surgeon (SC).

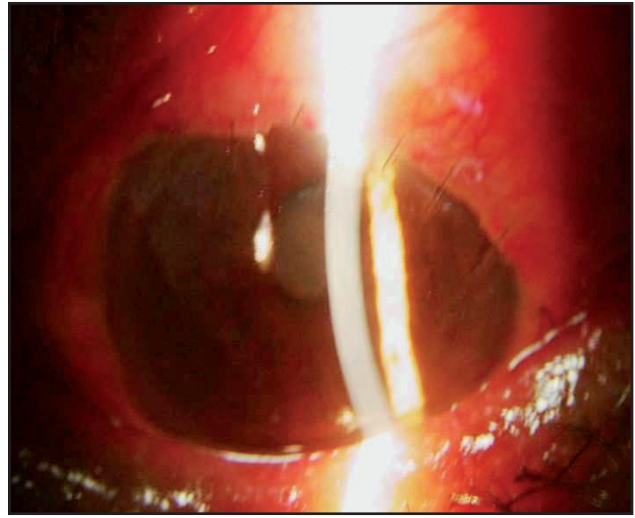



Figure 1: (Patient 1) A -Elevated and avascular bleb (HB) following trabeculectomy with MMC; B - Aspect of the bleb (1<sup>th</sup> postoperative day) following HB resection

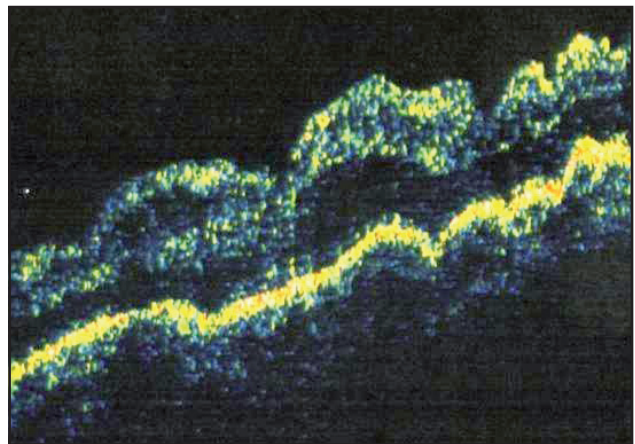
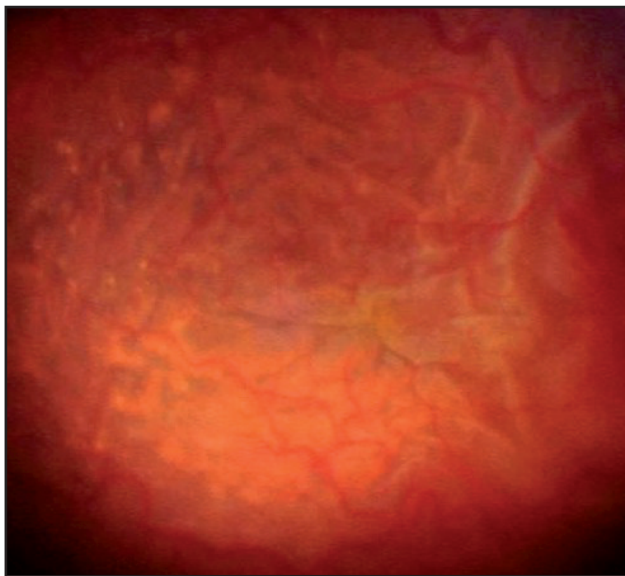


Figure 2: A - Hypotonic maculopathy (streaks and choroidal folds) (patient 1) demonstrated by retinography; B - OCT image showing the aspect of a hypotonic maculopathy (patient 12); Note the severity of retinal and choroidal folds and the increase of retinal thickness

**Surgical procedure**

Each patient underwent peribulbar block anesthesia with 2% lidocaine (2 ml) and 0.75% bupivacaine (4 ml) associated with 0.1 ml of hyaluronidase 200 UI. After inserting a lid retractor, HB resection was performed by means of an incision using a #15 scalpel blade around the perimeter on the junction between the avascular bleb and the normal conjunctiva. Afterwards, the surgeon proceeded with a large fornix-based division of the normal conjunctiva using blunt scissors. Finally, the healthy conjunctiva was anchored on the cornea's periphery with four to five separate 10.0 nylon buried sutures (figure 1B). Patients were released

with a patch after application of an antibiotic plus corticosteroid ointment. No complications occurred. Postoperatively, patients used an association of ofloxacin and 0.1% prednisolone (three to four drops a day until the disappearance of inflammation). Sutures were removed under topical anesthesia at a slit-lamp one month after surgery. A successful resolution of hypotony was achieved when IOP ranged from six to 14 mmHg with or without antiglaucomatous medication. Only patients with a minimum 19-months postoperative follow-up were included. We registered: the operated hypotonic eye, age, gender, race, glaucoma type, the best corrected visual acuity (BCVA), IOP, number of prior antiglaucomatous surgeries, including the latest one in



Table 1

## Demographic and clinical data of 20 hypotonic eyes before and after HB resection

Patient #/Eye	Age/ Gender	Race	Glaucoma	BCVA before	BCVA after	IOPb before	IOP after	Fundoscopy before	Fundoscopy after	Follow-up
1/LE	21/M	White	Uveitic	0.1	0.7	zero	12 (W/O)	Hypot mac	Normal	91
2/RE	6/M	Mulatto	Congenital	0.05	0.2	zero	10 (W/O)	Invisible	C/D=0.8	26
3/RE	25/M	White	Congenital	LP	LP	2	14 (WM)	C/D=0.9	C/D=0.9	72
4/LE	50/F	Mulatto	Traumatic	0.1	0.3	3	10 (W/O)	Hypot mac	Normal	36
5/LE	11/M	Mulatto	Congenital	HM	CF 0.5 m	2	12 (WM)	Hypot mac	Normal	63
6/LE	10/M	Mulatto	Congenital	CF 1 m	0.05	3	14 (W/O)	Normal	Normal	67
7/RE	25/M	Mulatto	Traumatic	0.1	0.8	2	14 (W/O)	Hypot mac	Normal	30
8/LE	75/M	Mulatto	POAG	0.05	0.3	2	10 (WM)	Invisible	0.8	58
9/LE	30/M	Mulatto	Traumatic	CF 0.3 m	1.0	zero	10 (WM)	Normal	Normal	48
10/RE	15/M	Mulatto	Congenital	1.0	1.0	2	9 (W/O)	Normal	Normal	51
11/RE	13/M	White	Congenital	0.25	0.8	3	10 (WM)	Normal	Normal	67
12/RE	22/M	White	Late-onset Congenital	0.2	0.8	zero	10 (W/O)	Hypot mac	Normal	31
13/LE	38/F	Mulatto	Pigmentary	0.3	0.3	zero	12 (W/O)	C/D=0.9	C/D=0.9	34
14/LE	73/M	Mullato	POAG	LP	HM	2	10 (W/O)	C/D=0.9	C/D=0.9	37
15/LE	50/M	Mullato	POAG	HM	0.05	2	10 (W/O)	C/D=0.9	C/D=0.9	19
16/RE	12/M	White	Congenital	0.05	0.2	zero	8 (W/O)	Hypot mac	Normal	26
17/RE	66/F	Mullato	POAG	0.2	0.2	2	10 (WM)	C/D=0.8	C/D=0.8	25
18/LE	42/F	Mullato	Uveitic	0.25	0.7	zero	12 (WM)	C/D=1.0	C/D=1.0	36
19/RE	85/F	White	POAG	0.3	0.7	zero	10 (W/O)	Hypot mac	Normal	38
20/LE	68/M	White	POAG	0.3	0.3	zero	10 (W/O)	C/D=1.0	C/D=1.0	21

HB: hyperfiltering bleb; BCVA: best corrected visual acuity; IOP: intraocular pressure; RE: right eye; LE: left eye; M: male; F: female; Hypot mac: hypotonic maculopathy; LP: light perception; HM: hand movements; W/O: without medication; WM: with medication; CF: counting fingers; C/D: cup/disc ratio; m: meter; POAG: primary open angle glaucoma; TREC: trabeculectomy

which MMC was used, bleb aspect, the Seidel test result, fundoscopic and UBM findings, medications used after surgery and complications.

## RESULTS

Fifteen (75%) patients were male and five (25%) female. Thirteen (65%) patients were mulatto and seven (35%), white. The average age was  $35.5 \pm 19.03$  years (six to 85). Patients had the following types of glaucoma: congenital glaucoma: seven (35%) eyes; open-angle glaucoma: six (30%) eyes; traumatic glaucoma: three (15%) eyes; uveitic glaucoma: two (10%) eyes; late-onset congenital glaucoma: one (5%) eye and pigmentary glaucoma: one (5%) eye.

Preoperatively, the BCVA in hypotonic eyes was  $\geq 0.05$  in six (30%) eyes and  $< 0.05$  in 14 (70%) eyes (Table 1). The average preoperative IOP was  $1.28 \pm 1.1$

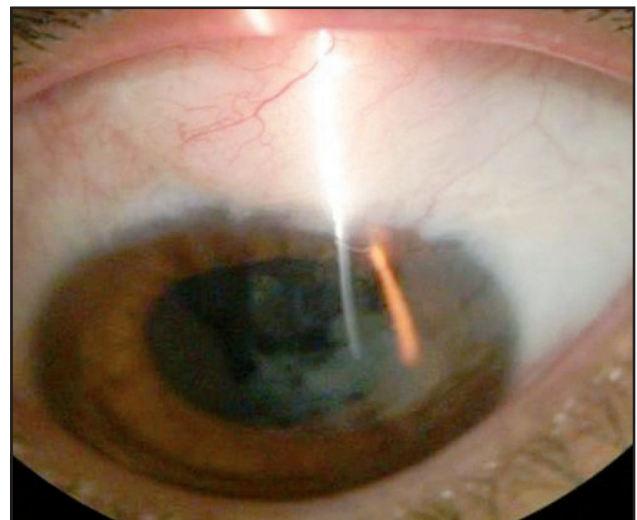


Figure 3: Elevated and slightly anemic bleb 91 months after HB resection (patient 1); Note the healed conjunctiva over the periphery of the cornea

mmHg. The number of previous antiglaucomatous surgeries, including the last trabeculectomy with MMC ranged from one to four ( $1.9 \pm 1.0$ ). Seventeen (85%) out of 20 patients were operated at our Service using 0.25 mg/ml MMC for 5 minutes. Three (15%) patients (1, 2 and 3) underwent trabeculectomy with MMC in other hospitals. Patient 1 underwent trabeculectomy which included 0.33 mg/ml MMC for 3 minutes. The other 2 patients also underwent trabeculectomy with MMC, however, it was impossible to collect information on the MMC concentration and the time period. All hypotonic eyes had elevated and/or diffuse and avascular bleb along with a negative Seidel test. Hypotonic maculopathy was diagnosed in seven (35%) eyes (Figures 2A and 2B). One eye (5%) presented a cup/disc ratio of 0.8; four (20%) eyes presented a cup/disc ratio of 0.9 and two (10%) had a cup/disc ratio of 1.0 without hypotonic maculopathy. Four (20%) eyes presented a normal fundus. A fundoscopic examination was impossible before bleb resection in patient 2 because of extreme opacity of the cornea and in patient 8 due to a cataract. UBM did not show CCD in any of the hypotonic eyes' four quadrants. After HB resection, patients were followed up from 19 to 91 months ( $43.8 \pm 19.8$ ). At the last examination, the BCVA improved in 15 (75%) eyes and was unchanged in five (25%) (Table 1). The last average postoperative IOP was  $11.05 \pm 1.8$  with the IOP ranging from 8 to 14 mmHg in 13 (65%) eyes, without medication. In five (25%), IOP ranged from 10 to 14 mmHg with topical antiglaucomatous medication. In two patients (8 and 11), another trabeculectomy was necessary to normalize IOP. The postoperative bleb aspect changed in relation to what it was prior to resection. In 12 (60%) eyes, the bleb was elevated and slightly anemic, but not avascular (figure 3), as it was in the preoperative period (figure 1A). In five (25%), the bleb was slightly elevated and anemic. Only one (patient 4) had an elevated and avascular bleb with a similar aspect to that of the preoperative period, despite the fact that hypotony was reversed (IOP=10 mmHg without medication). In two patients (8 and 11) the bleb was slightly elevated and vascular. IOP was not normalized (22 and 26 mmHg respectively) even under medication. These patients underwent another trabeculectomy without MMC respectively two years and three months and one year and four months after HB resection. Afterwards, IOP remained normal (10 mmHg) without medication at the last examination, respectively for 31 (patient 8) and 51 months (patient 11). They were the only two unsuccessful HB resections in this study. Reversion of hypotonic maculopathy followed by improved vision was obtained in seven eyes.

## DISCUSSION

Ocular hypotony may cause serious consequences for neuroretinal physiology, particularly in patients who have had it a long time<sup>(22)</sup>. Antimetabolites in trabeculectomy frequently provoke hypotony which demands adequate treatment to curb the potential gravity of complications they may unleash<sup>(4)</sup>.

Hyperfiltering bleb is one cause of ocular hypotony after trabeculectomy with MMC. It is characterized by an elevated and/or diffuse and avascular bleb, a negative Seidel test, no anterior chamber inflammation and no signs of CCD seen on the UBM.

The cause of ocular hypotony due to HB is controversial. In our opinion, a combination of factors exists. A reduction of aqueous humor is possible due to the toxic effects of MMC on ciliary processes along with HB. In relation to the diagnosis of ocular hypotony, we must acknowledge that hyperfiltration is subclinical. Hyperfiltering bleb causing ocular hypotony after trabeculectomy with MMC can only be diagnosed with certainty after other causes of hypotony have been eliminated, such as: a positive Seidel test (aqueous humor leakage through the bleb), presence of inflammatory signs in the anterior chamber (anterior uveitis) and CCD detected by UBM.

This study confirms, through the analysis of a great number of patients, the criteria we established for correct diagnosis of HB<sup>(23)</sup>. In a recent study<sup>(25)</sup> which reported the outcomes of surgical bleb revision due to complications of trabeculectomy, diagnosis of hypotony was based on the surgeon's clinical judgment. The eyes had various combinations of symptoms and signs and the authors did not perform UBM for the diagnosis of hypotony without leakage. Revision surgery consisted of conjunctival dissection with or without excision of the conjunctiva, followed by resuturing or reinforcing the sclera flap.

In this paper, diagnosis of ocular hypotony was not based on the surgeon's clinical judgment. We considered only patients whose ocular hypotony was caused by HB based on definitive criteria. Other authors<sup>(7-9,16)</sup> have mistakenly reported a positive Seidel test as an indication of HB causing ocular hypotony. In our opinion, they commit a grave error since that HB is only diagnosed with a negative Seidel test.

It is important to point out that 10 (50%) out of 20 patients in this study were young (ranging from six to 25 years old). Young patients are known to be refractory to trabeculectomy without MMC. However, they seem to be

more prone to ocular hypotony<sup>(26)</sup> and other serious retinal complications when MMC is used, particularly hypotonic maculopathy, as was seen in patients 1, 5, 7, 12 and 16. In one paper in which nine patients had undergone primary trabeculectomy with MMC, the authors reported chronic hypotonic maculopathy in five (55.6%) eyes<sup>(15)</sup>. The patients were relatively young, two were 18 years old in a group where the average age was 33.2. This average is higher than that of the five young patients with hypotonic maculopathy in this study. The prevalence of hypotonic maculopathy was very high if taken into account the fact that, except for one (patient 12), the patients had refractory glaucoma. Therefore, there is an urgent need to find other alternatives for the treatment of refractory glaucoma in young patients. We suggest that MMC not be used for primary trabeculectomy in children with congenital glaucoma nor in young patients with late-onset congenital glaucoma or open-angle glaucoma. If MMC is indispensable, minimum concentrations should be used for a short period of time and placed far from the scleral flap as Khaw<sup>(5)</sup> established. The patients' follow-up must be done on a regular basis in order that complications be detected in adequate time.

The present study demonstrates that HB resection yields satisfactory results in cases of ocular hypotony caused by hyperfiltration. The other options for treatment of ocular hypotony due to other causes, such as conjunctival patch<sup>(10,11)</sup>, fascia lata patch<sup>(12)</sup>, compression suture<sup>(15)</sup>, or conjunctival advancement with bleb preservation<sup>(21)</sup> have not presented the successful results we have obtained. This may be due to factors that are inherent to each technique but the failure of a correct diagnosis for HB is the most serious. Establishing the true cause of hypotony is indispensable for choosing the best procedure for its treatment. Hypotony may also be caused by aqueous humor leakage through the bleb (positive Seidel test), inflammatory reaction in the anterior chamber (anterior uveitis) and primary CCD. In the presence of a positive Seidel test, along with performing the bleb resection, it is necessary to attach a scleral patch on the place where the bleb was present in order to protect the newly forming bleb and thus prevent recurring leakage. Intense anterior chamber inflammation must be treated with cycloplegic (1% atropine, one drop every 8 hours) associated with the use of corticosteroid (0.1% dexamethasone or betamethasone or 1% prednisolone one drop every 6 hours)<sup>(24)</sup> and, sometimes, systemic corticosteroid. If a primary or secondary CCD is diagnosed through UBM and conventional clinical treatment fails, we can try to suture the ciliary body<sup>(27)</sup> or drain the suprachoroidal fluid while simultaneously injecting a viscoelastic substance

into the anterior chamber. An HB resection provides elimination of the very thin and necrotic conjunctiva and restoration of the bleb with potentially healthy tissue (figure 2). This reverses ocular hypotony and is completely different from what occurs when the conjunctival advancement technique is used to preserve the bleb<sup>(21)</sup>.

Hypotonic maculopathy was reversed in all seven patients (table 1). It must be made clear that the reversion of choroidal folds and maculopathy due to ocular hypotony is fully dependent on the correct diagnosis and adequate treatment of its cause. This occurred in patients 1, 4, 7, 12 and 19 at three, four, two, three and two months respectively after the diagnosis. On the other hand, in patients 5 and 16 who had a long time of hypotonic maculopathy (more than two years in the former and one year and six months in the latter), the IOP was normalized by HB resection. However, there was little improvement in BCVA of the patient 5 and the BCVA of the patient 16 remained the same despite the reversion of maculopathy. These patients also had nystagmus and amblyopia. Therefore, at the last examination only three out of the eight patients with congenital glaucoma had normal or nearly normal visual acuity. This may be due not only to functional changes (nystagmus, amblyopia, etc.) resulting from the refractory nature of congenital glaucoma, but also because of the delay of procedures for the reversion of ocular hypotony (four years for patient 2; five years for patient; two years for patient 5 and one year and six months for patient 16). However, patients 6, 11 and 12 (congenital glaucoma), for whom the time span between the diagnosis of ocular hypotony and the resection of the HB was respectively six, four and three months, presented a significant BCVA improvement. Patient 8 also had substantial eyesight improvement after a phacoemulsification and implantation of an intraocular posterior chamber lens.

The chorioretinal changes in ocular hypotony can sometimes occur rapidly, unlike what takes place in the development of open-angle glaucoma. The amount of time of the presence of ocular hypotony may be responsible for a bad prognosis.

## CONCLUSION

Bleb resection is an effective and safe procedure, capable of reversing ocular hypotony caused by HB. It also restores vision in a considerable number of patients. The diagnosis of HB must follow rigorous criteria. The results of this study substantiate the criteria for the correct diagnosis of a HB after trabeculectomy with mitomycin C.

## REFERENCES

1. Jay JL, Murdoch JR. The rate of visual field loss in untreated primary open angle glaucoma. *Br J Ophthalmol.* 1993;77(3):176-8.
2. Migdal C, Gregory W, Hitchings R. Long-term functional outcome after early surgery compared with laser and medicine in open-angle glaucoma. *Ophthalmology.* 1994;101(10):1651-6; discussion 1657.
3. The effectiveness of intraocular pressure reduction in the treatment of normal-tension glaucoma. Collaborative Normal-Tension Glaucoma Study Group. *Am J Ophthalmol.* 1998;126(4):498-505. Comment in: *Am J Ophthalmol.* 1998;126(4):578-81. *Am J Ophthalmol.* 1999;127(5):623-5. *Am J Ophthalmol.* 1999;127(5):625-6. *Am J Ophthalmol.* 1999;128(6):776-7.
4. Shigeeda T, Tomidokoro A, Araie M, Koseki N, Yamamoto S. Long-term follow-up of visual field progression after trabeculectomy in progressive normal-tension glaucoma. *Ophthalmology.* 2002;109(4):766-70.
5. Khaw PT, Wilkins M. Antifibrotic agents in glaucoma surgery. In: Yanoff M, Duker JS, editors. *Ophthalmology.* London: Mosby; 1999. p. 1-7.
6. Wise JB. Treatment of chronic postfiltration hypotony by intrableb injection of autologous blood. *Arch Ophthalmol.* 1993;111(6):827-30.
7. Leen MM, Takahashi Y, Li Y, Stewart JF, Chen PP, Mills RP. Mitotic effect of autologous blood injection and diode laser bleb revision on rabbit filtration blebs. *Arch Ophthalmol.* 1999;117(1):77-83.
8. Leen MM, Moster MR, Katz LJ, Terebuh AK, Schmidt CM, Spaeth GL. Management of hyperfiltering and leaking blebs with autologous blood injection. *Arch Ophthalmol.* 1995;113(8):1050-5. Comment in: *Arch Ophthalmol.* 1996;114(5):633-4.
9. Choudhri SA, Herndon LW, Damji KF, Allingham RR, Shields MB. Efficacy of autologous blood injection for treating overfiltering or leaking blebs after glaucoma surgery. *Am J Ophthalmol.* 1997;123(4):554-5.
10. Buxton JN, Lavery KT, Liebmann JM, Buxton DF, Ritch R. Reconstruction of filtering blebs with free conjunctival autografts. *Ophthalmology.* 1994;101(4):635-9.
11. Wilson RM, Kotas-Neumann R. Free conjunctival patch for repair of persistent late bleb leak. *Am J Ophthalmol.* 1994;117(5):569-74.
12. Hughes BA, Shin DH, Birt CM. Use of fascia lata in revision of filtration surgery. *J Glaucoma.* 1996;5(3):207-9.
13. Lynch MG, Roesch M, Brown RH. Remodeling filtering blebs with the neodymium:YAG laser. *Ophthalmology.* 1996;103(10):1700-5.
14. Bettin P, Carassa RG, Fiori M, Brancato R. Treatment of hyperfiltering blebs with Nd:YAG laser-induced subconjunctival bleeding. *J Glaucoma.* 1999;8(6):380-3.
15. Guedes VRF, Simmons RB, Pakter H, Simmons RJ. Persistent hypotony after primary trabeculectomy with mitomycin C. *Arq Bras Oftalmol.* 2000;63(3):179-83.
16. Sugar HS. Complications, repair and reoperation of antiglaucoma filtering blebs. *Am J Ophthalmol.* 1967;63(4):825-33.
17. Cohen JS, Shaffer RN, Hetherington J Jr, Hoskins D. Revision of filtration surgery. *Arch Ophthalmol.* 1977;95(9):1612-5.
18. Fitzgerald JR, McCarthy JL. Surgery of the filtering bleb. *Arch Ophthalmol.* 1962;68:453-67.
19. Grostern RJ, Torczynski E, Brown SV. Surgical repair and histopathologic features of a dissecting glaucoma filtration bleb. *Arch Ophthalmol.* 1999;117(11):1566-7. Comment in: *Arch Ophthalmol.* 2001;119(6):927.
20. La Borwit SE, Quigley HA, Jampel HD. Bleb reduction and bleb repair after trabeculectomy. *Ophthalmology.* 2000;107(4):712-8.
21. Catoira Y, Wudunn D, Cantor LB. Revision of dysfunctional filtering blebs by conjunctival advancement with bleb preservation. *Am J Ophthalmol.* 2000;130(5):574-9.
22. Haynes WL, Alward WL. Combination of autologous blood injection and bleb compression sutures to treat hypotony maculopathy. *J Glaucoma.* 1999;8(6):384-7.
23. Cronemberger S, Santos DVV, Oliveira ACM, Maestrini HA, Calixto N. Ressecção de bolsa hiperfuncionante para tratamento de hipotonia ocular crônica: relato de casos. *Arq Bras Oftalmol.* 2004;67(4):637-44.
24. Becker B. Intraocular pressure response to topical corticosteroids. *Invest Ophthalmol.* 1965;4:198-205.
25. Radhakrishnan S, Quigley HA, Jampel HD, Friedman DS, Ahmad SI, Congdon NG, McKinnon S. Outcomes of surgical bleb revision for complications of trabeculectomy. *Ophthalmology.* 2009;116(9):1713-8.
26. Cronemberger S, Santos DVV, Ramos LFF, Oliveira ACM, Maestrini HA, Calixto N. Trabeculectomia com mitomicina C em pacientes com glaucoma congênito refratário. *Arq Bras Oftalmol.* 2004;67(3):475-9.
27. Lopes Filho JG, Costa VP, Goldbaum M. Hipotonia ocular secundária à ciclodíálise: descrição de 4 casos e revisão de literatura. *Arq Bras Oftalmol.* 1997;60(6):626-30.

---

**Correspondence to:**  
**Sebastião Cronemberger**  
**Rua Martim de Carvalho, nº 410/501**  
**Santo Agostinho**  
**CEP 30190-090 – Belo Horizonte (MG), Brasil**  
**Telefone: (31) 9185-0103**  
**Email: secronem@gmail.com**