

Unilateral enophthalmos induced by the unilateral use of topical Bimatoprost

Enoftalmia causada por uso tópico unilateral de Bimatoprost

Guilherme Herzog Neto

ABSTRACT

The author describes a case report of a patient with unilateral enophthalmia and deep palpebral sulcus probably induced by the topical use of Bimatoprost on the side of the collateral effects described.

Keywords: *Glaucoma/drug therapy; Ophthalmic solutions/adverse effects; Ophthalmic solutions/therapeutic use; Enophthalmos/chemically induced; Case reports*

RESUMO

O autor descreve o caso de uma paciente que apresenta o olho direito com o sulco palpebral profundo e enoftalmia deste lado, tratado durante uma década com Bimatoprost tópica. Concluem que os achados clínicos são provavelmente efeitos colaterais do medicamento.

Descritores: *Glaucoma/quimioterapia; Soluções oftálmicas/efeitos adversos; Bimatoprost tópico; Enoftalmia/induzido quimicamente; Relato de casos*

Professor associado da Universidade Federal Fluminense (UFF) - Niterói (RJ), Brazil;
Hospital Universitário Antonio Pedro (HUAP) – Niterói (RJ), Brazil.

The authoes declare no conflicts of interests.

Received for publication 13/07/2012 - Accepted for publication 20/01/2013

INTRODUCTION

Clinical and experimental studies have recently shown a deepening association between the upper eyelid crease and enophthalmos as a side effect of topical use of Bimatoprost and prostaglandin analogues. A probable cause would be an adipocyte apoptosis induced by eyedrops⁽¹⁻⁴⁾.

We present an 80-year-old woman using topic Bimatoprost once a day for 9 years just in the right eye, and who developed an asymmetry between the eyes by a deepening of the upper eyelid crease and a mild enophthalmos on the side under treatment associated to the unilateral growth of the eyelashes, as well as a slight hyperpigmentation of the iris on the same side of enophthalmos.

CASE REPORT

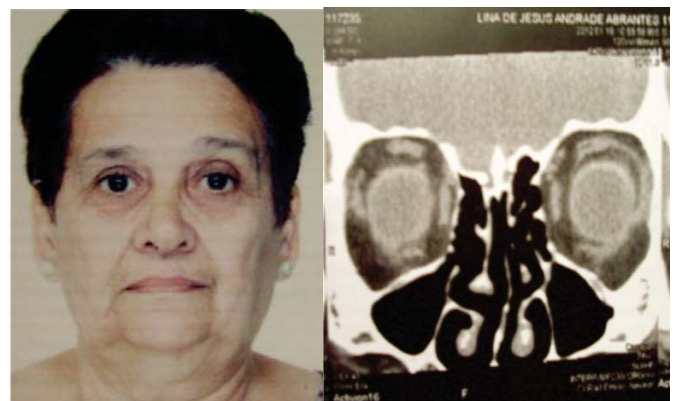Female patient (LJAA), 61 years old at the time, underwent facelift with bilateral intraocular lens implant, the right eye was operated in 1994 and the left eye in 1997. The anesthesia for the two phacoemulsification procedures was peribulbar injection of 5 ml of 0.75% marcaine with 500 UTR Hyalozima. The post-operative visual acuity is currently of 20/40 and 20/30, with correction in the left and right eyes, respectively. The right eye developed a slight complication with partial lens capture two months after the intervention and a slight discoria associated to a secondary glaucoma that manifested in 1997. It was controlled with the topical use of Timolol 0.5% and dorzolamide twice a day only on the right side with secondary glaucoma. In 2002 the treatment of secondary glaucoma in the right eye was changed to Bimatoprost once a day with proper control of glaucoma, symmetrizing the IOP in 15 mm in BE. After two years it was considered stopping the treatment with Bimatoprost due to the growth of eyelashes just in the right eye, which was evident in the comparison with the normal side. The patient chose to continue with the same eyedrops, since this side effect did not bother her. Eight years afterwards, it was possible to note a difference in aesthetics between both eyes, with the right eye showing a darker iris and a deeper eyelid crease than the left eye, and an enophthalmos was seen on the right side. The exophthalmometry measures 13 and 16 mm respectively (RE and LE), and therefore the right eye is 03 mm deeper than the left eye. Figure 1 shows the patient 20 years ago, before the cataract surgeries, with a more pronounced eye crease on the left side, probably due to the fact of the left orbit being slightly larger than the right one, as shown in the computed tomography (Figure 2). Figures 3, 4 and 5 show the current asymmetry with deepening of the right eye crease, enophthalmos with increasing size of the eyelashes and darkening of the iris on the right side with the topical use of Bimatoprost. The axial computed tomography (Figure 5) shows the enophthalmos on the right side. The diagnostic ultrasound of both eyes was normal, and the echobiometry showed that both eyes have the same axial length (22.60 mm RE and 22.09 mm LE), showing that the asymmetry of the crease was not caused by the difference in the size of the eyes.

DISCUSSION

The exophthalmos probably caused by atrophy of orbital adipocytes is one of the complications recently described by the

use of prostaglandin analogues for treating glaucoma. This was clinically and experimentally observed⁽¹⁻⁴⁾. This enophthalmos develops slowly, and it is difficult to understand something is changing in this sense due to the slowness with which this change occurs, and especially when the same drug treatment is bilateral and changes are symmetrical. However, the use of this drug only on one side causes a gradual change of symmetry that is perceivable because of the deepening of the eye crease on side using eyedrops. This change plus the growth of eyelashes and the iris pigmentation makes it easier for the asymmetry to be perceived. In the old picture, our patient presented a deeper eye crease on the left side due to the bigger orbit on this side (Figures 1 and 2). Therefore, in order to cause the asymmetry of the crease, the atrophy of fat on the right side needed to be more pronounced first to balance the appearance of the crease between both eyes and then for only later become more pronounced on the right side than on the left side. This process took some years, as described (Figures 3, 4 and 5). As seen in Figure 5, the only difference that could be responsible for this enophthalmos is a lower amount of fat on this side, since the other orbital structures had similar volume between the two orbits. The surgery probably has nothing to do with these changes because the procedures were equal on both sides and held by the same professionals.

We concluded that Bimatoprost may be associated to enophthalmos and deepening of the eye crease in eyes treated with chronic use of the drug, and that users of this drug should be warned about this side effect when starting the treatment.



Figures 1 e 2: Patient photographed 15 years ago (before the use of Bimatoprost) with the eye crease of the left eye deeper than the right one due to the orbit on this side be slightly larger, as can be seen on the computed tomography in the coronal section below.

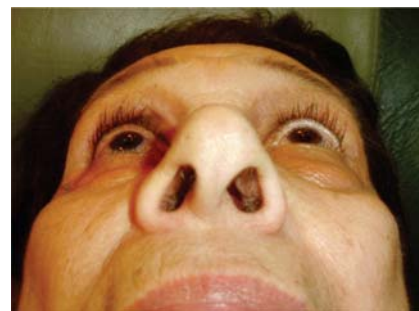

Figure 3. Current picture. Right eye with the use of Bimatoprost showing longer eyelashes and enophthalmos on this side.

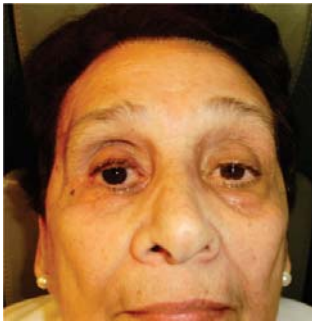

Figure 4. Current picture with a deeper eye crease on the right and slightly darker iris on the right eye

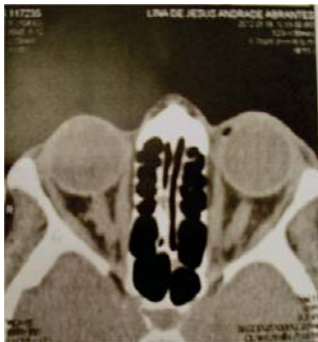


Figure 5. Mild enophthalmos (3 mm) on the right eye in relation to the left eye. Both eyes have the same diameter.

ACKNOWLEDGEMENT

The author acknowledges the cooperation and consent of the patient described for the publication of this case.

REFERENCES

1. Tappeiner C, Perren B, Iliev ME, Frueh BE, Goldblum D. [Orbital fat atrophy in glaucoma patients treated with topical bimatoprost — can bimatoprost cause enophthalmos?]. *Klin Monbl Augenheilkd.* 2008;225(5):443-5. German.
2. Filippopoulos T, Paula JS, Torun N, Hatton MP, Pasquale LR, Grosskreutz CL. Periorbital changes associated with topical bimatoprost. *Ophthal Plast Reconstr Surg.* 2008;24(4):302-7.
3. Aydin S, İpýklýgil I, Tek°en YA, Kir E. Recovery of orbital fat pad prolapsus and deepening of the lid sulcus from topical bimatoprost therapy: 2 case reports and review of the literature. *Cutan Ocul Toxicol.* 2010;29(3):212-6.
4. Jayaprakasam A, Ghazi-Nouri S. Periorbital fat atrophy - an unfamiliar side effect of prostaglandin analogues. *Orbit.* 2010;29(6):357-9.

Corresponding author:

Rua Jorge Dodsworth Martins 151, Barra da Tijuca,
Rio de Janeiro, ZIP Code: 22793-321,

Fax: 3329-3673.

E-mail: gherzogneto@gmail.com