

Unilateral floppy eyelid syndrome with ipsilateral intolerance to brimonidine

Síndrome da pálpebra flácida unilateral com intolerância a brimonidina ipsilateral

Leidiane Adriano Pereira¹, Sidney Julio Faria-e-Sousa¹, Gleiton Carlos Mendonça¹, Jailton Vieira Silva^{2,3}, Amanda Alexia Rodrigues Vieira³

ABSTRACT

The authors report a case of unilateral floppy eyelid syndrome with ipsilateral intolerance to brimonidine in a 65-year-old man. The singularity of this case is the combination of two rare illnesses of great phlogistic potentiality in the same eye. The purpose of this article is to report a case of unilateral floppy eyelid syndrome with ipsilateral intolerance to brimonidine, emphasizing a possible relation between them. The result was a unilateral keratopathy that emulated an intraepithelial neoplasia. The key to solving the problem was an unexplained anterior uveitis that raised the suspicion of drug toxicity. The upper eyelid eversion of the affected eye during sleep seemed to be the common denominator of both ailments. The bizarre aspect of the epitheliopathy most likely resulted from the combination of trauma, insufficient lubrication, and drug intolerance.

Keywords: Brimonidine tartrate; Uveitis; Uvea/drug effects; Eyelids/abnormalities; keratitis; Case reports

RESUMO

Os autores relatam um caso de síndrome da pálpebra flácida unilateral com intolerância ipsilateral à brimonidina em um homem de 65 anos de idade. A singularidade deste caso é a combinação de duas doenças raras de grande potencialidade inflamatória no mesmo olho. O objetivo deste artigo é relatar um caso de síndrome da pálpebra flácida com intolerância ipsilateral à brimonidina, enfatizando uma possível relação entre eles. O resultado foi uma ceratopatia unilateral que simulou uma neoplasia intra-epitelial. A chave para resolver o problema foi uma uveíte anterior inexplicável que levantou a suspeita de toxicidade medicamentosa. A eversão da pálpebra superior do olho afetado durante o sono parece ser o denominador comum de ambas as doenças. O aspecto bizarro da epiteliopatia provavelmente resultou da combinação de trauma, lubrificação insuficiente e intolerância ao medicamento.

Descritores: Tartarato de brimonidina; Uveite; Úvea/efeitos de drogas; Olho/anormalidades; Ceratite; Relato de casos

¹Faculdade de Medicina de Ribeirão Preto, Universidade de São Paulo, Ribeirão Preto, SP, Brazil.

²Universidade Federal do Ceará, Fortaleza, CE, Brazil.

³Universidade de Fortaleza, Fortaleza, CE, Brazil.

Project number in the Research Ethics Committee: 11132/2008 approved by Hospital das Clínicas da Faculdade de Medicina de Ribeirão Preto da Universidade de São Paulo.

Institution: Faculdade de Medicina de Ribeirão Preto, Universidade de São Paulo, Ribeirão Preto, São Paulo, SP, Brazil.

The authors declare no conflicts of interest.

Received for publication: 14/06/2016 - Accepted for publication: 20/08/2016.

INTRODUCTION

Floppy eyelid syndrome (FES) is a disorder manifested by a flaccid upper eyelid that easily everts upon upward traction. The friction of the tarsal conjunctiva against the pillow, when the patient sleeps face down, seems to be the cause of conjunctival inflammation. Treatment consists of preventing the upper eyelid eversion during sleep.⁽¹⁾ Brimonidine is an alpha2-adrenoreceptor agonist used for the topical treatment of glaucoma.⁽²⁾ Sporadically it can also cause a granulomatous anterior uveitis.⁽³⁾ When not associated with conjunctivitis, the uveitis tends to be asymptomatic and without vision reduction. Its resolution ranges from four days to eight weeks after the cessation of the topical use.⁽⁴⁾ The purpose of this article is to report a case of unilateral floppy eyelid syndrome with ipsilateral intolerance to brimonidine, emphasizing a possible relation between them.

Case report

A 65-year-old obese man complained of foreign-body sensation, photophobia and low vision in the left eye that started six months earlier. Fifteen days after the beginning of the symptoms, an ophthalmologist diagnosed bilateral glaucoma and punctate keratopathy in the left eye. He prescribed eye drops of timolol maleate 0.5%/brimonidine tartrate 0.2% and an antibiotic/steroid ophthalmic preparation for the left eye for ten days. Symptoms worsened over time. Three months later, another ophthalmologist prescribed eye drops of fluorometholone acetate 0.1% for 30 days. As the clinical condition continued to deteriorate, he referred the patient to our service.

When we first saw the patient, he was using only glaucoma medication. The best correct visual acuity was 20/25 in the right eye and 20/400 in the left eye. Intraocular pressure (IOP) was 14 mmHg in both eyes. Lash ptosis, dermatochalasis, blepharoptosis and mild blepharitis were present bilaterally. Both upper eyelids were flaccid and rubbery. Any traction on the skin of the left upper eyelid would evert it, unveiling its conjunctival surface covered with large confluent papillae. The right upper eyelid could not be everted this way, and its conjunctival lining was normal.

Slit-lamp examination of the left eye revealed a diffusely hyperemic bulbar conjunctiva with a mild follicular reaction in the lower fornix. The cornea was covered by a thick opalescent epithelium, without vascularization, coarsely stained with rose bengal (Figure 1). The right eye was normal in all aspects except for a mild follicular reaction in the lower fornix.

Working with the hypothesis of a combination of FES and deficient ocular surface lubrication, we oriented the patient never to lie face down and to protect the left eye with a plastic shield while sleeping. We also prescribed eye drops of carboxymethylcellulose 0.5% six times daily for the left eye and kept unchanged glaucoma treatment. Two weeks later the epithelium transparency of the left eye had improved enough to allow us to disclose mutton-fat keratic precipitates on the endothelium. We made the diagnosis of presumed brimonidine induced uveitis and discontinued this medication, leaving only timolol 0.5% twice daily for controlling of the IOP.

Seven days later the keratic precipitates had disappeared. The intraocular pressure rose to 16 mmHg. The patient reported substantial relieve of his signs and symptoms, from this period onwards. Nine weeks after our first examination we considered the patient cured. The best corrected visual acuity was 20/25 in both eyes. We advised the patient to have plastic surgery to correct

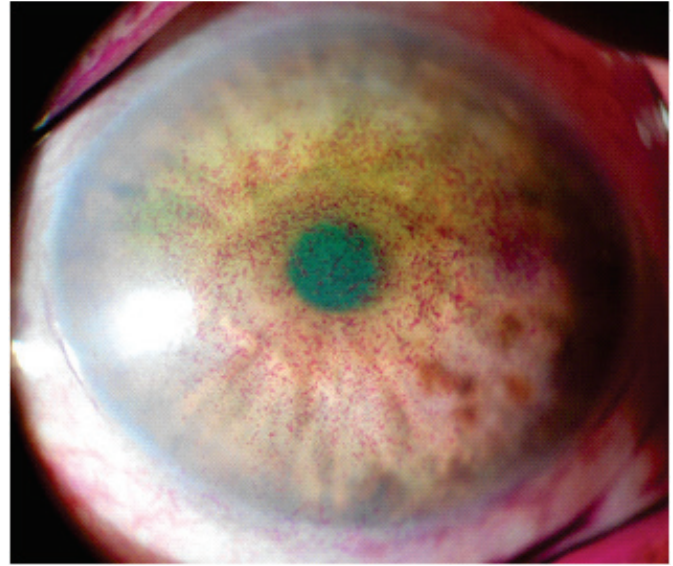


Figure 1: Left eye keratopathy

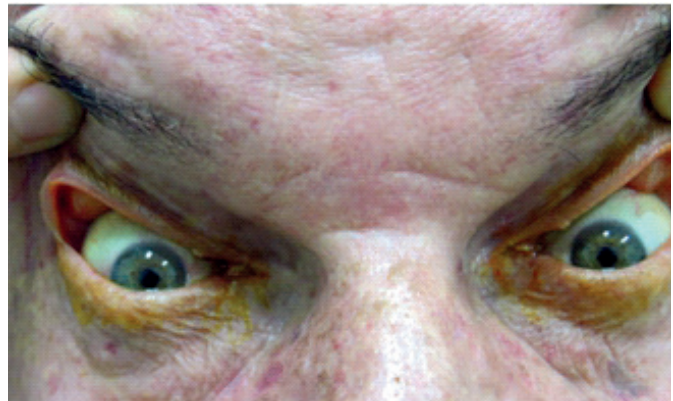


Figure 2: Floppiness of the upper eyelids one year later

the tarsal floppiness.

One year later the eyes had no signs of inflammation. Both eyelids were still very elastic, but none of them everted under upward traction (Figure 2). He had had only a surgical correction of the dermatochalasis of the upper eyelids, seven months earlier.

DISCUSSION

The singularity of this case is the combination of two rare illnesses of great phlogistic potentiality in the same eye. Brimonidine conjunctivitis is well-known, but the association of this drug with anterior uveitis is less notorious.⁽⁴⁻⁶⁾ The literature contains only 12 previous publications describing this association.⁽⁴⁾

Upper eyelids that easily evert upon upward traction coupled with a papillary reaction of the corresponding conjunctival lining are the main features of FES. Dermatochalasis, blepharitis, corneal epithelial keratitis and male obesity are common comorbidities.⁽⁷⁾ Therefore, this case could be considered a quintessential example of FES, except for the unusual pattern of the eye inflammation. More specifically, the conjunctivitis of FES is primarily superior; it does not involve the entire bulbar conjunctiva. The epithelial keratopathy is a punctate epithelial

defect and not a thick opalescent layer of epithelium emulating neoplasia.⁽⁸⁾ Despite these oddities, anterior uveitis was the key to solving this diagnostic puzzle. Since it could not be explained by FES, and by any other ailment of the eye, we suspected of drug intolerance to brimonidine. The rapid disappearance of the keratic precipitates with the discontinuation of brimonidine is an evidence of drug-induced uveitis. The substantial relieve of signs and symptoms was probably due to the remission of conjunctivitis as the uveitis seems to be asymptomatic.⁴ The bizarre aspect of the epitheliopathy most likely resulted from the combination of trauma, insufficient lubrication, and drug intolerance.

The patient was using brimonidine in both eyes, but the side-effects were confined to the left eye. We think this is a consequence of the FAS being unilateral. The friction of the everted upper eyelid against the bed linen, typical of this syndrome, caused chronic inflammation that enhanced the contact of topical medications with the inner tissues of the eye surface. The preserved surface of the contra-lateral eye averted this problem. The bilateral follicular reaction on the inferior conjunctival fornices could have been an initial sign of bilateral drug toxicity.

Surgical treatment of FES includes a variety of strategies to tighten and anchor the upper eyelid.⁽⁷⁾ None of them were used in this case. Thus, the control of the inflammation and the re-education of the sleeping habits of the patient seemed to be crucial for the outcome of this case. We do not know if the dermatochalasis correction had any influence on it.

REFERENCES

1. Culbertson WW, Ostler HB. The floppy eyelid syndrome. *Am J Ophthalmol.* 1981;92(4):568-75.
2. Greenfield DS, Liebmann JM, Ritch R. Brimonidine: a new alpha-2-adrenoreceptor agonist for glaucoma treatment. *J Glaucoma.* 1997;6(4):250-8.
3. Byles DB, Frith P, Salmon JF. Anterior uveitis as a side effect of topical brimonidine. *Am J Ophthalmol.* 2000; 130(3):278-91.
4. Beltz J, Zamir E. Brimonidine induced anterior uveitis. *Ocul Immunol Inflamm.* 2016; 24(2):128-33.
5. Katz LJ. Brimonidine tartrate 0.2% twice daily vs. timolol 0.5% twice daily: 1-year results in glaucoma patients. *Am J Ophthalmol.* 1999;127(1):20-6.
6. Blondeau P, Rousseau JA. Allergic reactions to brimonidine in patients treated for glaucoma. *Can J Ophthalmol.* 2002;37(1):21-6.
7. Ezra DG, Beaconsfield M, Colli R. Floppy eyelid syndrome: stretching the limits. *Surv Ophthalmol.* 2010;55(1):35-46.
8. Arffa R.C. Floppy eyelid syndrome. In: Grayson's diseases of the cornea. St. Louis: Mosby Year Book; 1991. p. 134-6.

Corresponding author:

Jailton Vieira Silva.

Rua Professor Costa Mendes, 1608, CEP 60430140 - Fortaleza, Ceará, CE, Brazil.

Phone: +5585 33668062 / +5585 999446869.

Email: jailtonvieira@gmail.com