

# Orbital myositis in a patient with Behçet's disease

## *Miosite orbitária em paciente com doença de Behçet*

---

Aiessa Fedrigo<sup>1</sup>, Thiago A. Gomes dos Santos<sup>1</sup>, Ana Paula B. Campos<sup>2</sup>, Marcelo Gehlen<sup>3</sup>, Luisa Moreira Hopker<sup>4</sup>, Thelma L Skare<sup>5</sup>

### ABSTRACT

*The etiological diagnosis of orbital myositis (OM) is a challenge. Although it has been associated with previous infectious disease, diseases with autoimmune background, thyroidopathies or with paraneoplastic syndrome, most of them still remain as idiopathic. We describe here a case of OM uncovering a Behçet disease that is considered a rare cause for this kind of eye involvement.*

**Keywords:** *Orbital myositis; Exophthalmus; Behçet's disease; Case reports.*

### RESUMO

Trata-se de um caso de ceratite bilateral e simultânea por *Acremonium* relacionada ao uso intermitente e sem respeitar a lateralidade. O diagnóstico etiológico da miosite orbitária (MO) é desafiador. Embora ela tenha sido relacionada com doenças infecciosas prévias, doenças associadas à autoimunidade, tireoidopatias ou síndromes para neoplásicas, a maioria delas ainda permanece como idiopática. Descreve-se aqui, um caso de MO revelando o diagnóstico de doença de Behçet, doença considerada como uma causa pouco comum para este tipo de envolvimento ocular.

**Descritores:** Miosite orbitária; Exoftalmia; Doença de Behçet; Relatos de casos.

---

<sup>1</sup> Rheumatology Unit, Hospital Universitário Evangélico de Curitiba, Curitiba, PR, Brazil.

<sup>2</sup> Spondyloarthritis Outpatient Department, Rheumatology Unit, Hospital Universitário Evangélico de Curitiba, Curitiba, PR, Brazil.

<sup>3</sup> Rheumato-Ophthalmology Unit, Hospital Universitário Evangélico de Curitiba, Curitiba, PR, Brazil.

<sup>4</sup> Pediatric Ophthalmology and Strabismus Department, Ophthalmology Unit, Hospital Universitário Evangélico de Curitiba, Curitiba, PR, Brazil.

<sup>5</sup> Rheumatology Unit, Hospital Universitário Evangélico de Curitiba, Curitiba, PR, Brazil.

**Os autores declaram não haver conflito de interesses.**

Recebido para publicação em 14/08/2017 - Aceito para publicação em 08/09/2017.

## INTRODUCTION

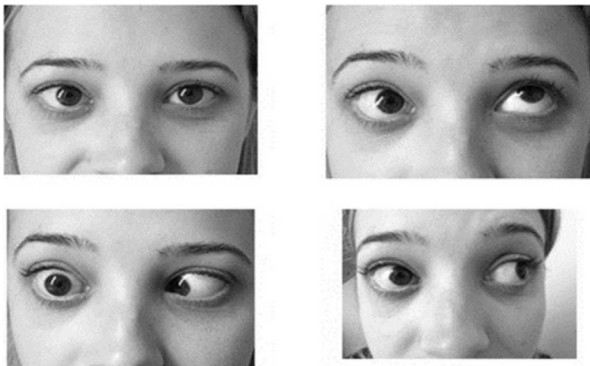
**O**rbital myositis (OM) is an unusual subset of inflammatory syndromes that primarily involves extraocular muscles and most commonly affects young adults with a female predilection.<sup>(1)</sup> It may cause periorbital pain, proptosis, eyelid edema, conjunctival redness and diplopia due to eyeball movement restriction.<sup>(1)</sup> The onset is acute and the process is, usually, unilateral although bilateral involvement has been found in up to 18% of cases.<sup>(2)</sup> Associated pupillary or visual acuity changes are infrequent.<sup>(3)</sup> The most commonly involved muscles are the horizontal recti.<sup>(1)</sup> Ultrasonography, computed tomography or magnetic nuclear resonance of the orbit shows edema of one or more extra ocular muscles.<sup>(1,2)</sup> The biopsy rarely contributes to clarifying the etiology and it is indicated in recurrent or refractory cases or when a malignant process is suspected.<sup>(3)</sup> Additional investigation is usually made in order to search for associated diseases.

The etiology of OM is unknown but, in several cases, it has been associated to a previous infectious disease, autoimmune diseases or tumors.<sup>(1,4)</sup> However, in the majority of circumstances, they are considered idiopathic.<sup>(1)</sup>

The authors describe a rare case of OM associated to Behçet's disease and draw attention to this possibility when the differential diagnosis of diseases associated with orbitopathies is done.

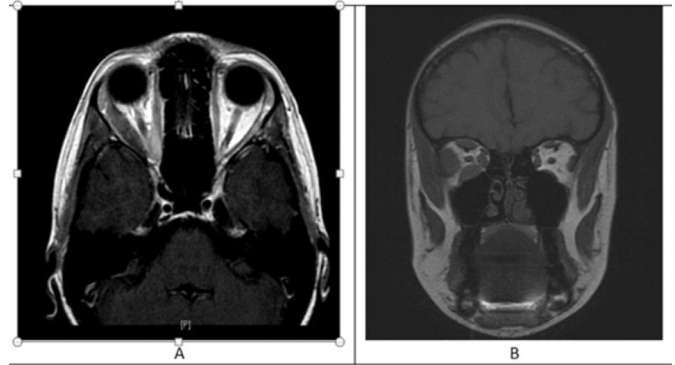## CASE REPORT

A 26 years old white female was referred to our hospital because of retro orbital pain and diplopia on right gaze of one year duration. She had been treated with oral prednisone (20 mg/day) and nonsteroidal anti-inflammatory eye drops without relief. Upon questioning she recalled having arthralgias and arthritis when she was younger but never had received a definitive diagnosis. There was a history of periodic bouts of acne, frequent multiples mouth and genital ulcers that used to recur at least three times a year. At that time, ophthalmologic examination disclosed visual acuity of 20/20 in both eyes and the biomicroscopy was unremarkable. The intra ocular pressure was of 15 mmHg in both eyes. The extra ocular motility examination showed no deviation in primary position; abduction limitation was of -4, adduction limitation of -3, elevation and depression limitation of -2. There was an esotropia of 20 PD in primary position with right hypotropia of 8 PD as seen in figure 1. The fundoscopy examination showed that optic nerve, macula and retina were unremarkable.



**Figure 1:** Hypofunction of superior and medial rectus and paralysis of lower and lateral rectus in the right eye.

A visual field was performed and was within normal range. An orbital magnetic resonance (MRI) was done and showed an increase of volume of all 4 rectus muscles of the right eye and muscle oedema (with low intensity on T1-weighted images) as seen in figure 2.



**Figure 2:** Orbital magnetic resonance (a)- axial T1 fat sat and (b) coronal T1 fat sat showing: enlargement of all four rectus muscles at right.

Sedimentation rate was of 37 mm, and C-reactive protein was <6 mg/dL (normal <6mg/dL). C-Anca, p-Anca, rheumatoid factor and antinuclear factor were negative. Sorologies for B and C hepatitis and for HIV were also negatives. Thyroid function tests (TSH, free T4) were normal as well as TRAB, antithyroglobulin and antiperoxidase antibodies and IgG4 levels.

With diagnosis of OM secondary to Behçet's syndrome the patient received treatment with high dose corticosteroids. Three weeks after this treatment she remained unchanged so it was decided to perform botulinum toxin injection on medial rectus of right eye. She had a brief improvement followed by return to initial situation in about 10 weeks. Azathioprine was started. The patient's status remained unaltered, and as soon as oral prednisone was tapered, the pain during eye movement restarted and she noted worsening of diplopia. A new MRI showed increase in volume of right lateral and superior rectus. An eye muscle biopsy to rule out tumor was done and disclosed infiltration of lymphocytes CD3 positives in the muscle, suggesting myositis. The steroid dose was increased and an anti-TNF drug (infliximab) was added. Upon anti-TNF treatment the steroid were tapered successfully and the patient remained asymptomatic until now (one year of observation).

## DISCUSSION

Efforts to identify an etiologic diagnosis of OM are critical as it may direct treatment and prognostic evaluation. Several systemic inflammatory diseases are found in association, including polymyositis, thyroid-related eye disease, psoriatic arthropathy, rheumatoid arthritis, Kawasaki disease, scleroderma, systemic lupus erythematosus, Crohn's disease, ankylosing spondylitis, and giant cell arteritis.<sup>(1-3)</sup> The association with Behçet is rare.<sup>(4,5)</sup>

Behçet's disease (BD) is a systemic inflammatory vascular disorder characterized by recurrent oral and genital ulcers, eye lesion, arthritis and skin lesions.<sup>(6)</sup> Behçet diagnosis is clinical and based on classification criteria as no single laboratory test is specific for this disease. One of the most accepted criteria are the ISG (International Study Group) Criteria published in 1990,

that has high sensitivity and specificity. <sup>(6)</sup> Table 1. The reported patient had recurrent oral ulcers (a major criteria), genital ulcers and acne (two minor criteria) fulfilling the requirement for Behçet's diagnosis.

**Table 1**  
**Diagnostic criteria for Behçet's syndrome**

<b>Major criteria</b>	Recurrent oral ulceration (at least 3 episodes /year; observed by physician or patient)
<b>Minor criteria</b>	Recurrent genital ulceration (observed by physician or patient) Eye lesions (uveitis and/or vasculitis) Skin lesions (eritema nodosum-like, papulopustular skin lesions, or pseudo-folliculitis with acneiform nodules) Pathergy test

Adapted from: International Study Group for Behçet's Disease. Criteria for diagnosis of Behçet's disease. *Lancet*. 1990; 335(8697):1078-80.

Eye involvement appears in 60-80% of BD patients <sup>(6)</sup> and can be the initial symptom in 10–20% of patients. In others cases it is usually present at the onset of the disease or it will appear within the first 2 years of diagnosis. <sup>(7)</sup> Uveitis is the most common ocular manifestation in this context but the patients may also have conjunctivitis, retinal vasculitis, conjunctival ulcers, optic neuropathy, cataract, and neovascularization of iris or retina. <sup>(5)</sup> OM is considered uncommon. <sup>(4,5)</sup>

It is important to differentiate OM from thyroid ophthalmopathy. In this last one the involvement is usually bilateral; the muscle tendons are typically spared giving a fusiform appearance; the orbital pain is usually absent and there is associated lid retraction <sup>(8)</sup>, not found presently.

In the OM diagnosis, the use of MRI offers important information as it detects the exact distribution of muscle involvement. Fluid sensitive techniques such as fat suppressed T2 weighted sequences show the presence of oedema in the inflamed muscles that become hyperintense; unaffected muscles are characterized by low signal on T2 weighted sequences. <sup>(9)</sup> Tumors may also have increase signal on T2 <sup>(10)</sup>; so a muscle biopsy was done and excluded this hypothesis.

The treatment of OM is empirical. Glucocorticoids are usually the first treatment choice. <sup>(8)</sup> Despite the generally favorable response to steroid therapy, relapses and persistent inflammation complicate the clinical course and treatment. Cyclophosphamide, methotrexate, azathioprine, cyclosporine, mophetyl mycophenolate and even radiotherapy have been used in more severe cases. <sup>(8,11)</sup> More recently, biologic drugs such as

anti-TNF has been used successfully. In a series of seven OM cases treated with this drug, (in which there was one patient with Behçet's disease), the response was good, allowing the patients to reduce or even withdraw glucocorticoids. <sup>(12)</sup>

To conclude the authors would like to emphasize that, although rare, Behçet's disease should be included in the group of diseases associated with OM.

## REFERENCES

- Costa RM, Dumitrascu OM, Gordon LK. Orbital myositis: diagnosis and management. *Curr Allergy Asthma Rep*. 2009; 9(4):316-2.
- Yan J, Wu Z, Li Y. A clinical analysis of idiopathic orbital inflammatory pseudotumor. *Na KeXueBao* 2000; 16 (3): 208-13.
- Ugur HC, Tascilar N, Atilla H, Yucemen N. A case of atypical idiopathic myositis mimicking neurological disease. *J Clin. Neurosci*. 2001; 8(2):164-5.
- Roh JH, Koh SB, Kim JH. Orbital myositis in Behçet's disease: A case report with MRI findings. *Eur Neurol*. 2006; 56 (1): 44-5.
- Dursun D, Akova Y, Yucel E. Myositis and scleritis associated with Behçet's disease: an atypical presentation. *Ocul Immunol. Inflamm*. 2004; 12(4):329-32.
- Lutt JR, Lim LL, Phal PM, Rosenbaum JT. Orbital inflammatory disease. *Semin Arthritis Rheum*. 2008; 37 (4): 207-22.
- Gyldenløve M, Tvede N, Larsen JL, Jacobsen S, Thyssen JP. Low prevalence of positive skin pathergy testing in Danish patients with Behçet's disease. *J Eur Acad Dermatol Venereol*. 2014; 28(2):259-60.
- Volle E, Levy R, Miléa D, Tourbah A, Lubetzki C. Idiopathic orbital myositis. *Rev Neurol (Paris)* 2001; 157 (4): 430-2.
- Day J, Patel S, Limaye V. The role of magnetic resonance imaging techniques in evaluation and management of the idiopathic inflammatory myopathies. *Semin Arthritis Rheum*. 2017; 46 (5): 642-9.
- Mu X, Wang H, Li Y, Hao Y, Wu C, Ma L. Magnetic resonance imaging and DWI features of orbital rhabdomyosarcoma. *Eye Sci*. 2014; 29(1):6-11.
- Hatton MP, Rubin PA, Foster CS. Successful treatment of idiopathic orbital inflammation with mycophenolatemofetil. *Am J Ophthalmol*. 2005; 140 (5): 916-8.
- Garrity JA, Coleman AW, Matteson EL, Eggenberger ER, Waitzman DM. Treatment of recalcitrant idiopathic orbital inflammation (chronic orbital myositis) with infliximab. *Am J Ophthalmol*. 2004 138 (6):925-30.

## Corresponding Author:

Thelma L. Skare

Rua: Augusto Stelfeld 1908, CEP 80730150, Curitiba, PR, Brazil.

E-mail: tskare@onda.com.br