

# Recurrent bilateral orbits pseudo-tumor

## *Pseudotumor orbital bilateral recorrente*

---

Artur Furlaneto Fernandes<sup>1</sup>, Larissa de Freitas Nunes<sup>2</sup>, Tainã Paulo Zanata Trombetta<sup>3</sup>, Isadora Carvalho Nunes Rosa<sup>3</sup>, Tamara Hoffmann<sup>3</sup>

### **ABSTRACT**

*The orbital pseudotumor is a benign idiopathic inflammatory disease. The authors present a case manifested in 12 years old boy, diagnosed by clinical, laboratory and radiological examination. There was a good response to treatment with corticosteroids proposed. The report is followed by brief literary resume on the subject.*

**Keywords:** *Orbital pseudotumor; Orbital diseases; Recurrence; Adrenal cortex hormones; Child*

### **RESUMO**

O pseudotumor orbitário é uma doença inflamatória idiopática benigna. Os autores apresentam um caso manifestado em adolescente de 12 anos, diagnosticado por meio do exame clínico, laboratorial e radiológico. Houve boa resposta ao tratamento proposto com corticosteroides. O relato é seguido de breve retomada literária acerca do tema.

**Descritores:** Pseudotumor orbitário; Doenças orbitárias; Recidiva; Corticoesteroides; Criança

---

<sup>1</sup> Department of Neurology, Hospital Nossa Senhora da Conceição, Tubarão, SC, Brazil.

<sup>2</sup> Department of Medical Clinic, Hospital Nossa Senhora da Conceição, Tubarão, SC, Brazil.

<sup>3</sup> Academic of the Medical Course, Universidade do Sul de Santa Catarina, Tubarão, SC, Brazil.

Institution: Universidade do Sul de Santa Catarina (Unisul), Tubarão, SC, Brasil

**The authors declare no conflict of interests.**

Received for publication 18/05/2017 - Accepted for publication 03/10/2017.

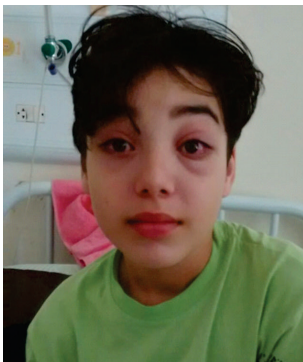## INTRODUCTION

**O**rbital pseudotumor is a benign idiopathic inflammatory disease that can affect any orbital tissue. It accounts for about 6% of all orbital lesions, of which only 6% in children.<sup>(1)</sup> It presents a great variety of clinical manifestations, with pain, proptosis and local inflammatory signs and symptoms being the most common ones. The diagnosis is made by exclusion through the clinical history, physical and laboratory examinations, and imaging tests that may characterize other conditions. Biopsy is recommended in cases of doubtful diagnosis, resistance to treatment, or recurrence of the lesion. The treatment is carried out mainly with the use of corticosteroids. Radiotherapy is indicated in case the corticosteroid therapy has no effect, or when the disease has insidious onset.<sup>(2,3)</sup>

## CASE REPORT

A 12-year-old white male patient with recurrent bilateral palpebral edema, conjunctival edema and hyperemia predominantly on the left associated to local pain starting 7 days prior to hospitalization. He had no other associated symptoms such as fever or headache. He had previous history of a similar condition in the year 2013, but no comorbidities and no use of continuous-use medications.

Physical examination presented stable vital signs, heart and respiratory auscultation without alterations, and abdomen without pain at palpation or presence of visceromegaly. Ocular examination revealed hyperemia and bilateral eyelid edema, conjunctival edema and hyperemia with predominance on the left side (Figure 1), bilateral ophthalmoparesis with predominance also on the left side, bilateral visual acuity 20/25 and normal funduscopy.

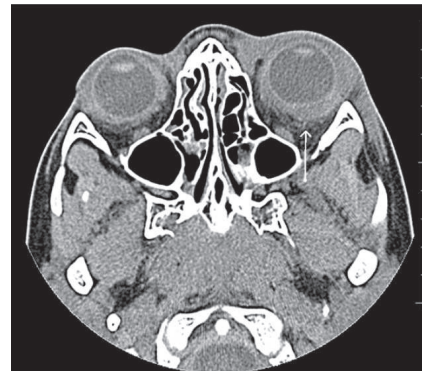

**Figure 1:** Physical examination shows bilateral edema and hyperemia of the eyelid, and conjunctival edema and hyperemia with predominance on the left.

The laboratory investigation showed leukocytes of 9750/mm<sup>3</sup>, platelets 355000/mm<sup>3</sup>, C-reactive protein (CRP) 11.2mg/L, thyroglobulin 16.3ng/mL, antithyroglobulin antibodies 0.40 IU/mL, complement C4 29mg/dL, complement C3 150 mg/dL, normal kidney function and coagulogram, nonreactive anti-nucleus factor (ANF) and rheumatoid factor (RF), thyroid function without alterations. Blood cultures were negative.

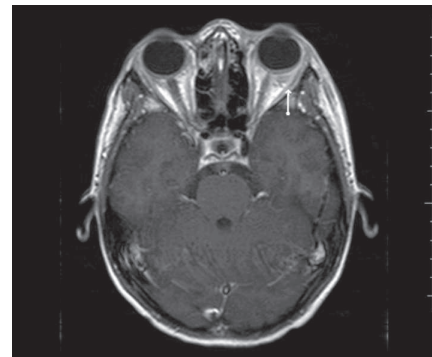
A CT scan of the skull was requested and showed no alterations, and then a CT of orbits was requested showing lesion of soft parts of the pre- and post-septal space, with involvement of the infra-conal space and involvement of the left orbital musculature, which determines mild proptosis of the ocular globe, and

may correspond to the inflammatory process depending on the clinical correlation (Figure 2).



**Figure 2:** Computed tomography. Images in axial cuts with visualization in window of soft parts. Lesion of the soft parts of the pre- and post-septal space with involvement of the intra-conal space and involvement of the left orbital musculature determining a light proptosis of the ocular globe compatible with the inflammatory process.

An MRI of the skull was then requested to rule out cavernous sinus thrombophlebitis, and a diffuse thickening of the left ocular globe was observed with contrast and blurring of the lateral and superior rectus muscles (Figure 3).



**Figure 3:** MRI with contrast. Images in axial section and weighted in T1 (arrows showing lesion). Diffuse thickening of the left ocular globe with contrast and blurring of the lateral and superior rectus muscles

With the exclusion of other hypotheses for the clinical condition, a recurrent orbital pseudotumor diagnosis was made and treatment initiated with prednisone 40 mg daily. The treatment with corticosteroid was carried out for three days, and an important clinical improvement was observed. The patient was discharged with ambulatory follow-up, and the symptoms were completely treated.

## DISCUSSION

The orbital pseudotumor, also known as idiopathic inflammation of the orbit (IIO), is a non-granulomatous inflammatory process that can affect any orbital tissue, and there is no definite site or systemic cause. Epidemiology shows that this pathology represents the third most common orbital disease, followed by dysthyroid orbitopathy and lymphoproliferative disease.<sup>(4)</sup> Its diagnosis is made by exclusion,<sup>(4,5)</sup> based on the history, clinical examination, results of complementary exams that can diagnose other conditions, for example laboratory tests (T3, T4, TSH, VHS, blood glucose, urea,

creatinine, blood cultures), computed tomography, response to the medication proposed, and biopsy of the lesion.<sup>(4)</sup>

The disease usually manifests in a very variable way, so the presentation forms include the acute, subacute or chronic episodes, and the inflammatory manifestations are less expressive or absent in the last two. It is more common in adults, and can affect both genders. The unilateral presentation is more common, but it may be bilateral, especially in children.<sup>(4,6)</sup>

Biopsy has a formal indication in situations where the diagnostic doubt remains after clinical, laboratory and radiological evaluations of the patient, in cases where there is involvement of the anterior portion of the orbit due to ease of access, and in the recurrence or resistance to treatment.<sup>(4,6)</sup> Based on the orbital tissue involved, IIO can be subdivided into: myositis (extraocular muscle), dacryoadenitis (lacrimal gland), periscleritis, and perineuritis. Some authors usually classify the disease as ocular topography, being anterior (eye and orbit), apical (orbital apex and cavernous sinus), nodular or diffuse orbital inflammatory processes.<sup>(6,7)</sup>

Graves' ophthalmopathy is the main differential diagnosis. Both may present congestive-edematous palpebral-conjunctival signs, exophthalmos, oculomotor anomalies, and also reduction of visual acuity. Unlike IIO, Graves ophthalmopathy more frequently presents bilateral involvement. Other diagnostic hypotheses that should be excluded are orbital cellulitis, Wegener's granulomatosis, carotid-cavernous fistula, foreign bodies, fungi, sarcoidosis, sinusopathies, mucocoeles, cavernous sinus diseases, and others. Diffuse and nodular forms are usually confused with hemangiomas, lymphomas, lacrimal gland or other orbital tumors.<sup>(4,6-8)</sup>

Signs and symptoms vary according to the location of the inflammatory process, and clinical manifestations may include edema and periorbital pain, diplopia, decreased visual acuity in varying degrees, ptosis, proptosis, and decreased ocular movement.<sup>(9)</sup>

Some studies suggest the etiological participation of two specific cytokines derived from the growth factor of macrophages, with proliferative potential of fibroblasts and stimulant of collagen production. They are the platelet-derived growth factor and the B-growth factor.<sup>(10,11)</sup>

Several treatments for orbital inflammation have been employed, such as antibiotics, mercury, potassium iodide, corticosteroids, radiotherapy, immunosuppressive agents and, in some cases, surgical excision. However, all of them have questionable results.<sup>(10,11)</sup>

Traditionally, systemic corticosteroids are the first therapeutic line with an initial response in about 70% of cases. However, long term control occurs in only one third of cases. For refractory cases, pulses with low dose alkylating chemotherapy may be used to treat inflammatory diseases and systemic vasculitis; most patients have good tolerance, minimal side effects and a satisfactory response. Radiotherapy has been effective and also successfully used for the treatment of refractory pseudotumor,

with long-term control reports in approximately 65-70% of cases.<sup>(9)</sup>

## REFERENCES

1. Wesley RE. Current techniques for the repair of complex orbital fractures. Miniplate fixation and cranial bone grafts. *Ophthalmology*. 1992; 99(12):1766-72.
2. Berger JW, Rubin PA, Jakobiec FA. Pediatric orbital pseudotumor: case report and review of literature. *Int Ophthalmol Clin*. 1996; 36(1):161-77.
3. Fraga J, Sá A, Cândido C, Pinto JP, Dias F. Miosite orbitária numa criança. *Nascer e Crescer (Porto)*. 2012;21(1):28-32.
4. Yuen SJA, Rubin PA. Idiopathic orbital inflammation: distribution, clinical features, and treatment outcome. *Arch Ophthalmol*. 2003;121(4):491-9.
5. Caminha LS, Pinto ER, Sousa PA, Oliveira RA, Conceição FL, Vaisman m. Orbital pseudotumor: a differential diagnosis of Graves' ophthalmopathy. *Arq Bras Endocrinol Metab*. 2011;55(1):85-8.
6. Rodrigues-Alves CA, Santo RM. Pseudotumor de órbita. In: Rodrigues-Alves CA. *Neurooftalmologia*. São Paulo: Roca; 2000. p.193-211.
7. Dantas AM. Inflamações da órbita. In: Dantas AM, Monteiro ML. *Doenças da órbita*. Rio de Janeiro: Cultura Médica; 2002. p.153-78.
8. Jacobs D, Galetta S. Diagnosis and management of orbital pseudotumor. *Curr Opin Ophthalmol*. 2002;13(6):347-51.
9. Azevedo K, Rech A, Menezes C, Barleta D, Ferreira PRF, Maestri M, Brunetto A. Pseudotumor orbital na infância. *Rev HCPA*. 2003; 23(Supl):22.
10. Rootman J, McCarthy M, White V, Harris G, Kennerdell J. Idiopathic sclerosing inflammation of the orbit. A distinct clinicopathologic entity. *Ophthalmology*. 1994;101( 3):570-84.
11. Colley T. A case of inflammatory pseudo-tumour of the orbit. *Br J Ophthalmol*. 1935;19(2):93-5.

### Corresponding author:

Tamara Hoffmann  
Rua Av. Lauro Muller,63- Centro Brusque, SC, Brazil.  
ZIPCode: 88353-040  
Phone No.: (47) 99916-4456  
E-mail: tamara.hoffmann@hotmail.com

### ERRATA

In the scientific article "**Pseudotumor orbital bilateral recorrente**" by authors: **Artur Furlaneto Fernandes, Larissa de Freitas Nunes, Tainã Paulo Zanata Trombetta, Isadora Carvalho Nunes da Rosa, Tamara Hoffmann**, published in issue number 2 – volume 77 of the *Revista Brasileira de Oftalmologia*, March-April 2018, pages 92-4, DOI 10.5935/0034-7280.20180020, was published incorrectly, **where it reads:** Isadora Carvalho Nunes da Rosa, **reads:** Isadora Carvalho Nunes Rosa.