

# Periorbital presentation of IgG4 related disease

## *Apresentação periorbitária de doença relacionada ao IgG4*

Gabriela Caroline Monteiro de Albuquerque<sup>1</sup>, Bruna Dantas Aires Guimarães<sup>1</sup>, Maria Amélia Silva de Sousa Ribeiro<sup>2</sup>, Rinalva Tenório Vaz<sup>3</sup>, Jerrar Janedson Xavier Silva<sup>4</sup>

### ABSTRACT

*IgG4-Related Disease is an immunomediated condition that is characterized by the presence of inflammatory lesions associated with fibrosis and lymphoplasmacytic infiltration rich in positive IgG4 tissue plasmocytes, forming a spectrum of fibroproliferative diseases. The pathogenesis of IgG4-RD is still poorly understood and the treatment is empirical. We report the case of a 50-year-old man with yellow eyelid lesions associated with local edema, previously diagnosed as an allergic process, until biopsy with immunohistochemical study and serum IgG4 dosage revealed the hypothesis of IgG4 related disease. Treatment with corticoid and rituximab was initiated, showing stabilization of the condition, without presenting other clinical forms of the disease.*

**Keywords:** Immunoglobulin G; Autoimmunity; Eye Manifestations; Fibrosis; Case reports

### RESUMO

A doença relacionada ao IgG4 é uma condição imunomediada caracterizada pela presença de lesões com reação inflamatória associada à fibrose e à infiltração linfoplasmocitária rica em plasmócitos tissulares IgG4 positivos, compondo um espectro de doenças fibroproliferativas. A patogênese da DRIGG4 ainda é pouco compreendida e o tratamento é empírico. Relatamos o caso de um homem de 50 anos com lesões amareladas palpebrais associadas a edema local, diagnosticadas previamente como processo alérgico, até que biópsia com estudo imuno-histoquímico e dosagem de IgG4 sérico aventaram a hipótese de doença relacionada ao IgG4. Foi iniciado tratamento com corticoide e rituximabe, observando-se estabilização do quadro e sem apresentação de outras formas clínicas da doença.

**Descritores:** Imunoglobulina G; Autoimunidade; Manifestações oculares; Fibrose; Relatos de casos

<sup>1</sup> Ophthalmology Medical Residency Program, Hospital de Olhos Santa Luzia, Recife, PE, Brazil.

<sup>2</sup> Department of Pediatric Ophthalmology and Strabismus, Hospital de Olhos Santa Luzia, Recife, PE, Brazil.

<sup>3</sup> Department of Glaucoma, Hospital de Olhos Santa Luzia, Recife, PE, Brazil.

<sup>4</sup> Department of Oculoplastic Surgery, Hospital de Olhos Santa Luzia, Recife, PE, Brazil.

Institution: Hospital de Olhos Santa Luzia, Recife, PE, Brazil

**The authors declare no conflicts of interests.**

Received for publication 09/11/2017 - Accepted for publication 24/07/2018.

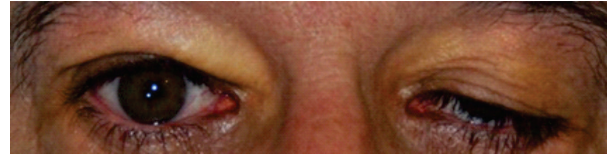## INTRODUCTION

IgG4-related disease (DRiG4) is an immunomediated condition characterized by the presence of lesions with inflammatory reaction associated with fibrosis and lymphoplasmacytic infiltration rich in IgG4 positive tissue plasminocytes, forming a spectrum of fibroproliferative diseases.<sup>(1)</sup> This spectrum of diseases shares particular pathological, serological and clinical characteristics. However, the pathogenesis of DRiG4 is still poorly understood. The disease was first described in 1961, but was only described as a systemic condition in 2003.<sup>(2)</sup> There are reports of involvement of salivary glands, periorbital tissues, meninges, lungs, aorta, pericardium, breast, thyroid and skin.<sup>(1)</sup> There are few epidemiological studies on the disease, but a higher prevalence is observed in male populations above 50 years of age, except for forms affecting the head and neck.<sup>(3)</sup> Currently, the most specific and sensitive diagnostic test for the diagnosis of DRiG4 is the IgG4 dosage. However, elevated concentrations of IgG4 can be found in other clinical conditions such as, for example, neoplasms, infections, and inflammatory diseases.<sup>(2)</sup> The purpose of the present case report is to describe the clinical, laboratory and imaging findings of a patient with DRiG4 with periorbital presentation.

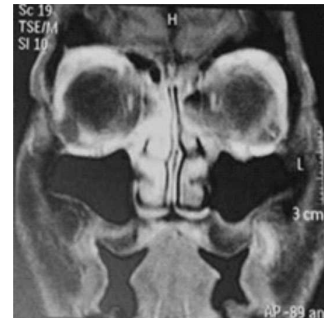
## CASE REPORT

Patient, 53 years old, male, complaining of upper eyelid (UE) ptosis in the left eye (LE) after palpebral biopsy 4 years ago. He reported the emergence of yellowish lesions in the UE of both eyes associated with local edema (Figure 1), and the biopsy of UE of LE (without immunohistochemical study) revealed an allergic process. At the time, he presented good function of the upper eyelid levator muscle in both eyes (BE), normal versions, visual acuity of 20/20 in BE. Patient denied comorbidities and was pseudophakic in BE. Orbital tomography (Figure 2) revealed a marked thickening of the extrinsic ocular muscle bilaterally (upper and lateral rectus muscles), discrete bilateral ocular proptosis, discrete fat densification, and presence of T2 hypointense tissue markedly impregnated by contrast in the topography of the lacrimal glands (bilateral and symmetrical), extending to the lateral walls of the orbit and upper eyelids. He had normal thyroid and anti-TRAB function. The biopsy of his right-eye UE showed immunohistochemical findings (Figure 3) revealing a population of T (CD3+) and B (CD20+) lymphocytes with areas with approximately 60 cells/CGA positive for IgG4/IgG of 30%, with said findings raising the possibility of IgG4 disease. The patient was referred to the hematologist who dosed IgG4 (70mg/ml), and prescribed treatment with Mabthera® and Meticortem®. During this period, it evolved with crossed diplopia to far and near sight, as well as vertical diplopia of left over right. The prism coverage test presented exotropia for far sight of 12 prismatic diopters (PD), and 20 DP for near sight associated with hypertropia of the LE of 6 PD. Hypofunction of the left superior oblique muscle (-2) and hyperfunction of the left inferior oblique muscle (+1) were noted in the versions, with a diagnostic hypothesis of left upper oblique paresis. Fresnel prism of 8 DP with lower base for the LE was prescribed, presenting fusion to far and near sight. After the stabilization of the condition, he underwent surgery

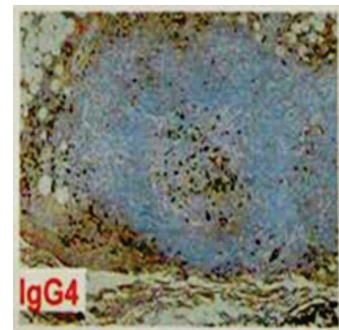
for correction of ptosis of LE. With continuous treatment, it evolved with the cure of diplopia and without other clinical forms of the disease.



**Figure 1:** . Clinical appearance of the eyelid lesions and ptosis of the upper eyelid of the left eye.



**Figure 2:** Orbit tomography showing thickening of the extrinsic ocular muscles bilaterally.



**Figure 3:** Findings of the immunohistochemical study.

## DISCUSSION

DRiG4 is a newly defined inflammatory process comprising tissue infiltration by IgG4-bearing plasma cells. It is considered a systemic condition comprising a broad spectrum of tumefying lesions in multiple organs that were previously thought to be unrelated.<sup>(4)</sup> IgG4 is the least common among the four classes of immunoglobulins (IgG1, IgG2, IgG3 and IgG4). However, it seems to play a significant role in allergic reactions, but it does not activate the complement nor has affinity for target antigens.<sup>(5)</sup>

Painless palpebral edema is the introduction symptom in most cases, whereas proptosis with or without diplopia is also common. Although the tomography of the patient in question suggested bilateral symmetrical involvement of the extraocular muscles, possibly the diplopia presented appeared as a result of a greater involvement of the extraocular muscles of the LE, observed on the exam of ocular motility. As in the case reported, the visual acuity is generally not impaired, but the optic nerve compression causing blindness has been reported.<sup>(5)</sup> In contrast to ocular adnexal lymphoma, DRiG4 patients rarely manifest

systemic symptoms such as weight loss or fever.<sup>(6)</sup> Previous publications on DRIGG4 with orbital involvement emphasized tear gland enlargement, however extraocular musculature thickening was the most common finding.<sup>(7)</sup> Ocular findings are generally bilateral in 62% of cases, 69% with involvement of the lacrimal gland, and bilateral involvement of the lacrimal gland in 48%.<sup>(8)</sup> As we did not observe description of palpebral ptosis in the literature and the patient did not present ocular motility impairment suggestive of cranial III impairment, we believe that the patient's left palpebral ptosis was possibly due to iatrogenic lesion of the upper eyelid levator muscle during the first biopsy.

Regarding the diagnostic tests, the serum IgG4 dosage is important as initial test, since high concentrations have high sensitivity and negative predictive value for the diagnosis of DRIGG4. However, since other conditions may also occur with increased IgG4 serum levels, the gold standard for diagnosis in most cases is biopsy of the organ involved and pathological clinical correlation.<sup>(9)</sup>

Identifying cases of DRIGG4 is important because the lesions may be highly responsive to directed treatment with biological agents.<sup>(4)</sup> The treatment is empirical, and as the pathophysiology is not understood it tends to suppress the corticosteroid process, although relapses are observed with treatment discontinuity.<sup>(8)</sup> Other indicated immunosuppressive agents are methotrexate, cyclophosphamide and azathioprine. Radiotherapy may be indicated in cases of localized disease, although its role is still unclear.<sup>(10)</sup> For the patient in question, the treatment with a combination of rituximab and corticosteroid was chosen. Before starting treatment, it is important to look for a tissue diagnosis and to exclude malignancy.

Estimating the incidence of DRIGG4 is difficult due to low diagnostic suspicion. Thus, we draw attention to the findings of the physical examination (characteristics of the skin lesions presented by the patient), as well as the relevance of the complementary tests such as the immunohistochemical study and the IgG4 dosage. The importance of a detailed anamnesis and a holistic view of the patient for the diagnostic investigation is demonstrated, which led to the hypothesis of DRIGG4 and the possibility of treatment directed to the patient.

## REFERENCES

1. Fernandes DA, Kido RY, Barros RH, Martins DL, Penachim TJ, Caserta NM. Doença relacionada à IgG4: pancreatite autoimune e manifestações extrapancreáticas. *Radiol Bras.* 2016;49(2):122-5.
2. Sampaio YC, Costa EB, Nogueira LR, Miranda CF, Nogueira JO, Macedo AL, et al. Doença relacionada à IgG4: relato de um desafio diagnóstico. *Rev Soc Bras Clin Med.* 2016;14(2):106-9.
3. Palazzo E, Palazzo C, Palazzo M. IgG4-related disease. *Joint Bone Spine.* 2014;81(1):27-31.
4. Khosroshahi A, Carruthers MN, Deshpande V, Unizony S, Bloch DB, Stone JH. Rituximab for the treatment of IgG4-related disease: lessons from 10 consecutive patients. *Medicine (Baltimore).* 2012;91(1):57-66.
5. Cheuk W, Yuen HK, Chan JK. Chronic sclerosing dacryoadenitis: part of the spectrum of IgG4-related Sclerosing disease? *Am J Surg Pathol.* 2007;31(4):643-5.
6. Khosroshahi A, Stone JH. A clinical overview of IgG4-related systemic disease. *Curr Opin Rheumatol.* 2011;23(1):57-66. Review.
7. Tiegs-Heiden CA, Eckel LJ, Hunt CH, Diehn FE, Schwartz KM, et al. Immunoglobulin G4-related disease of the orbit: imaging features in 27 patients. *AJNR Am J Neuroradiol.* 2014;35(7):1393-7.
8. Kubota T, Moritani S. Orbital IgG4-related disease: clinical features and diagnosis. *ISRN Rheumatol.* 2012; 2012:412896.
9. Carruthers MN, Khosroshahi A, Augustin T, Deshpande V, Stone JH. The diagnostic utility of serum IgG4 concentrations in IgG4-related disease. *Ann Rheum Dis.* 2015;74(1):14-8.
10. Mejico LJ. IgG4-related ophthalmic disease. *Saudi J Ophthalmol.* 2015;29(1):53-6.

---

### Corresponding author:

Jerrar Janedson Xavier Silva  
Hospital de Olhos Santa Luzia  
Estrada do Encanamento, 909 - Casa Forte, Recife - PE, Brazil.  
ZIP Code: 52070-000  
E-mail: jerrax@hotmail.com