

# Juvenile xantogranuloma with íris involvement

## *Xantogranuloma juvenil com acometimento iriano*

---

Karine Lustosa Augusto<sup>1</sup>, Bárbara Araújo Oliveira Freire<sup>2</sup>, Helena Luiza Douat Dietrich<sup>3</sup>, Virgínia Laura Lucas Torres<sup>4</sup>

### ABSTRACT

*Herein we report a case of juvenile xantogranuloma, an inflammatory disease more commonly diagnosed during childhood and is characterized by cutaneous and ocular manifestations. Iris is the main target, presenting as local or diffuse yellowish lesions. Iris involvement may precipitate not only glaucoma but also amblyopia. Treatment is based on corticosteroids therapy, either local or systemic aiming disease control.*

**Keywords:** Juvenile xantogranuloma; Iris diseases; Glaucoma; Case reports

### RESUMO

É relatado um caso raro de xantogranuloma juvenil, doença de natureza inflamatória diagnosticada mais frequentemente na infância, com manifestações cutâneas e oculares. A íris é o principal sítio extracutâneo da doença, apresentando-se como lesão amarelada, difusa ou localizada. O acometimento iriano pode acarretar surgimento de glaucoma, além de ambliopia. O manejo clínico da lesão ocular no presente caso foi baseado na necessidade no uso contínuo de corticoide tópico e sistêmico para estabilização da doença.

**Descritores:** Xantogranuloma juvenil; Doenças da íris; Glaucoma; Relatos de casos

---

<sup>1</sup> Ophthalmologist in training at Altino Ventura Foundation , Recife , Pernambuco, Brazil

<sup>2</sup> Ophthalmologist at Altino Ventura Foundation , Recife, Pernambuco, Brazil

<sup>3</sup> Ophthalmologist in training at Altino Ventura Foundation , Recife, Pernambuco, Brazil

<sup>4</sup> Ophthalmologist, Ocular Oncology specialist and Staff of Oncology department at Altino Ventura Foundation, Recife, Pernambuco, Brazil

**The authors declare no conflict of interests.**

Received for publication 13/11/2017 - Accepted for publication 22/02/2018.

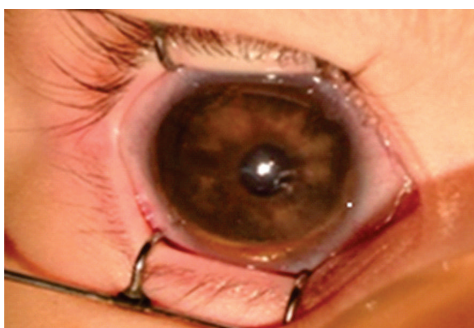
## INTRODUCTION

**J**uvenile Xanthogranuloma is a rare idiopathic early childhood histiocytosis, which mainly affects skin, other organs are rarely compromised.<sup>(1,2)</sup> Among these, the eye, more specifically the iris is the most common target.<sup>(2-4)</sup> Lesions can be local or diffuse, usually yellowish and well vascularized, what may lead to hyphema and secondary glaucoma.<sup>(1,4)</sup> Treatment is based on corticosteroids therapy, either local or systemic. Small dose of local radiation may also be considered.<sup>(5)</sup> Herein we report a typical case involving skin and iris with mild response to steroids therapy.

## CASE REPORT

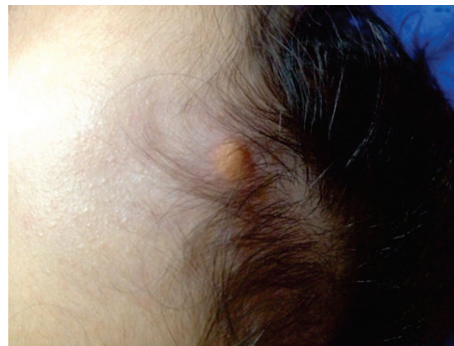T.L.B.S, 2 months, female, born and currently living in Alinança-PE. At the first visit, mother complained of redness and edema in child's right eye. Child was previously healthy, without any relevant medical past.

Ophthalmic examination under narcosis (Figure 1) revealed: biomicroscopy: right eye: buphtalmos, conjunctiva hyperemia, clear córnea, hyphema involving 1/5 of anterior chamber, yellowish infiltrating lesion in the iris; left eye examination was normal; corneal diameter: right eye: 13,5mm x 13mm, left eye: 12mm x 11,5 mm. Intraocular pressure was 10 mmHg both eyes. Right eye funduscopy was difficult due to media opacity, nonetheless high C/D ratio was observed. Left eye funduscopy was normal. Ultrassound was also performed both eyes. Examination revealed: right eye: 21.3 mm anteroposterior diameter, left eye: 18.6 mm APD. No significant alterations suggesting posterior segment tumor were found. Diagnostic hypothesis was Junevile Xanthogranuloma. Treatment was immediately started with dexamethasone 0.1% 1 drop every 3 hours and timolol maleate every 12 hours. Patient was referred to pediatrician and dermatologist for systemic evaluation.

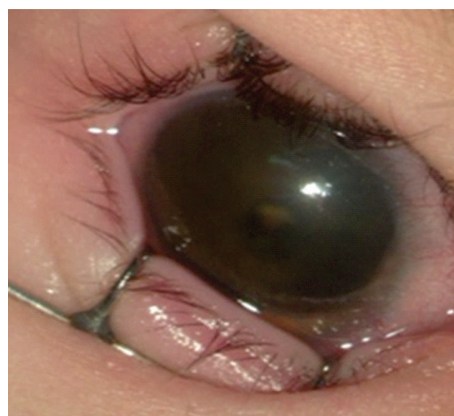


**Figure 1:** Examination under narcosis after initial symptoms showing yellowish iris lesion

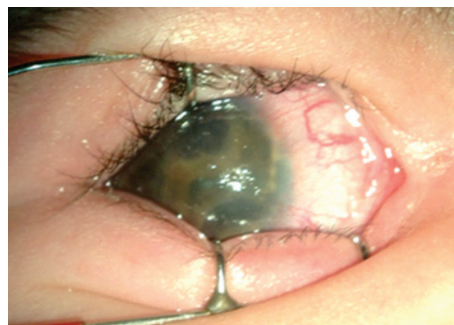Four months after first visit, typical yellowish papules at the face and scalp were observed (Figure 2) and since iris lesion improved significantly (Figure 3) dexamethasone weaning was started. One month later, patient returned with worsened lesion in the right eye (Figure 4). New cycle of topic dexamethasone with weakly weaning and systemic prednisolone 1mg/kg/day were started. After improvement of iris lesion, systemic prednisolone weaning was also started. When finishing medications, lesion worsened once again, this time prednisolone 1% drop was prescribed, initially, once a day following by alternate days therapy, which was maintained since lesion apparently stabilized.



**Figure 2:** Juvenile xanthogranuloma in the scalp



**Figure 3:** Improvement of iris lesion after topic steroids therapy



**Figure 4:** Worsening of iris lesion after suspension of topic steroids therapy

## DISCUSSION

Juvenile Xanthogranuloma is part of a spectrum of non-Langerhans cells histiocytosis.<sup>(4)</sup> It usually appears in early childhood, median age of onset is two years, but lesions may be present at birth.<sup>(2)</sup> Histologically, classic lesions are characterized by Touton cells, which are multinucleated cells with eosinophilic cytoplasm.<sup>(6)</sup> Although it has predilection for skin, JXG may also affect heart, lungs, bones, kidneys, bowel, central nervous system, pituitary and adrenal gland and bone marrow.<sup>(1-3)</sup>

Head and neck are the most common places for skin lesions, which are usually yellowish papules or nodules, 3-10 mm diameter.<sup>(2,7)</sup>, similar to our patient. Skin lesions are benign and self-limited, however, when affecting other organs, spontaneous regression is uncommon and morbidity is usually associated.<sup>(2)</sup>

The eye, particularly the uveal tract, is the most frequent site of extracutaneous involvement, 0.4 % of the cases, eyelids and ciliary body are less commonly involved.<sup>(3-5)</sup> Iris lesions are yellowish nodules, localized or diffuse, well vascularized, leading to hyphema and secondary glaucoma. They may be isolated or associated with skin lesions as well.<sup>(4,5)</sup>

In our case, because iris lesion was associated with clinical evidences of glaucoma such as buphtalmos and high C/D ratio, ocular hypotensive drug was concomitantly started with steroids therapy.

Disease is clinically diagnosed and may be confirmed by histopathology of either skin or eye lesion.<sup>(2,4)</sup> In this case report diagnosis was based on the typical presentation of the disease as well as on the age of onset.

For differential diagnosis of ocular JXG, neoplastic infiltrative lesions such as leukemia, medulloepithelioma and retinoblastoma.<sup>(8)</sup> In case of hyphema, trauma and other tumors should also be investigated.<sup>(9)</sup> On the other hand, if lesions at the conjunctiva are present, dermoid, scwhannoma, lipoma and other eyelid lesions such as lymphoma, sarcoidosis and Erdheim-Chester disease should be considered.

Treatment is based on topic steroids, either drops or subconjunctival and in case of failure systemic steroids and radiation therapy are options as well.<sup>(7)</sup> JXG control is difficult because long steroid therapy may increase the risk of glaucoma which is a particular complication of the disease already.<sup>(10)</sup> In our case, patient didn't respond properly to steroids therapy, without complete regression of the lesion. So far, maintenance of topical steroids is necessary to stop or at least to slow the progression of the disease.

## REFERENCES

1. Kanski JJ, Bowling B. Oftalmologia clínica: uma abordagem sistemática. Rio de Janeiro: Elsevier; 2012. p. 488.
2. Pajaziti L, Hapçiu SR, Pajaziti A. Juvenile Xanthogranuloma: a case report and review of the literature. BMC Res Notes. 2014; 7:174.
3. Liang S, Liu Y, Fang K. Juvenile xanthogranuloma with ocular involvement. *Pediatr Dermatol.* 2009;26(2):232-4.
4. Wilson M, Saunders RA, Trivedi RH. *Pediatric ophthalmology: Current thought and a practical guide.* Heidelberg, Germany: Springer; 2009. p.269;415.
5. Lueder GT. *Pediatric practice: ophthalmology.* New York: The McGraw-Hill; 2011. p. 157-8.
6. Sangüeza OP, Salmon JK, White CR, Beckstead JH. Juvenile xanthogranuloma: a clinical, histopathologic and immunohistochemical study. *J Cutan Pathol.* 1995; 22(4):327-35.
7. Casteels I, Olver J, Malone M, Taylor D. Early treatment of juvenile xanthogranuloma of the iris with subconjunctival steroids. *Br J Ophthalmol.* 1993; 77(1):57-60.
8. Zamir E, Wang RC, Krishnakumar S, Aiello Leverant A, Dugel PU, Rao NA. Juvenile xanthogranuloma masquerading as pediatric chronic uveitis: a clinicopathologic study. *Surv Ophthalmol.* 2001; 46(2):164-71.
9. Wright KW. *Pediatric ophthalmology for primary care.* 3rd ed. Illinois: American Academy of Pediatrics; 2007. p. 319-20.
10. Finamor LP, Finamor FJ, Muccioli C. Corticoterapia e uveítes. *Arq Bras Oftalmol.* 2002; 65(4): 483-6.

---

### Corresponding author:

Fundação Altino Ventura  
Rua da Soledade, 170, Boa Vista, Recife, PE, Brazil  
CEP 50070-040  
Phone: (81) 3302-4300  
E-mail: karine\_lustosa@hotmail.com