

Treatment of lateral rectus paralysis by transposition of superior rectus to lateral rectus

Tratamento de paralisia de reto lateral pela transposição do reto superior para o reto lateral

Cibele Peixoto Leite¹ <https://orcid.org/0000-0003-1573-7104>

Jorge Antônio Meireles Teixeira¹ <https://orcid.org/0000-0002-1842-486X>

Gian Francisco Rodrigues Cooper dos Santos² <https://orcid.org/0000-0003-4238-4770>

ABSTRACT

Objective: To evaluate the results of the surgical technique described by Crouch in the correction of lateral rectal paralysis (LR) esotropia.

Methods: A study conducted of six patients with VI cranial nerve palsy, with more than three months, and associated contracture of the medial rectus muscle. The causes of paralysis varied in traumatic, congenital and neuropathic. The patients underwent surgical correction, performed with a technique consisting of the instillation of the superior rectus muscle (SR) and its suture above the insertion of the LR muscle, completed with Foster's suture (suture joining, 8mm of the muscle insertion, the body of the SR and LR). The patients were followed for six months. **Results:** Five patients presented preoperative deviation between 30 and 50 prismatic diopter (PD), and one patient presented a deviation greater than 100 PD, and therefore, the patient required surgical reintervention due to residual deviation. The other five patients presented postoperative orthoptropy, with better visual acuity and no vertical deviations. **Conclusion:** The surgery proposed by Crouch has been shown to be a good alternative to conventional techniques, such as Carlson-Jampolsky surgery, being a technically simpler procedure with good results.

Keywords: Cranial nerve palsy; Ophthalmologic surgical procedures/methods; Crouch technique; Lateral rectal paralysis; Carlson-Jampolsky surgery

RESUMO

Objetivo: Avaliar resultados da técnica cirúrgica descrita por Crouch na correção de esotropia por paralisia do reto lateral (RL).

Métodos: Estudo realizado com seis pacientes diagnosticados com paralisia de VI par craniano, com mais de três meses, e com contratura associada do músculo reto medial. As causas da paralisia variaram em traumática, congênita e neuropática. Os pacientes foram submetidos à correção cirúrgica, realizada com técnica que consiste na desinserção do músculo reto superior (RS) e sua sutura acima da inserção do músculo RL, completada com ponto de Foster (sutura unindo, a 8mm da inserção muscular, o corpo do RS e RL). Os pacientes foram seguidos por seis meses. **Resultados:** Cinco pacientes apresentaram, no pré-operatório, desvio entre 30 e 50 dioptrias prismáticas (DP), e um paciente apresentava desvio maior que 100DP, sendo, portanto o paciente que necessitou de reintervenção cirúrgica, por desvio residual. Os outros cinco pacientes apresentaram ortotropia no pós-operatório, com melhor da acuidade visual e sem desvios verticais. **Conclusão:** A cirurgia proposta por Crouch demonstrou-se uma boa alternativa às técnicas convencionais, como cirurgia de Carlson-Jampolsky, sendo um procedimento tecnicamente mais simples e com bons resultados.

Descritores: Paralisia de VI par craniano; Procedimentos cirúrgicos oftalmológicos/métodos; Técnica de Crouch; Paralisia de reto lateral; Cirurgia de Carlson-Jampolsky.

¹ Universidade Federal do Maranhão, São Luís, MA, Brazil.

² Hospital de Referência Oftalmológica, São Luís, MA, Brazil.

Institution of achievement: Hospital Universitário President Dutra, Universidade Federal do Maranhão, São Luís, MA, Brazil.

The authors declare no conflicts of interests.

Received for publication 23/08/2018 - Accepted for publication 24/03/2019.

INTRODUCTION

The sixth cranial pair, or abducent nerve, is responsible for the innervation of the homolateral lateral rectal extraocular (LR) muscle, whose function is to perform the horizontal abduction movement of the eye. VI cranial paralysis has already been considered the most common of the extraocular muscle paralysis. Today it is considered the second most frequent, being behind the paralysis of IV cranial pair, whose main cause is traumatic.⁽¹⁾ The etiology of VI paralysis varies⁽¹⁻³⁾ among traumatic, vascular, infectious, neoplastic, infectious, congenital causes among others. The possibility of his injury is great, because of his long journey.⁽⁴⁾

The LR muscle is the only abductor of the eye in the primary gaze position (PG), since the abductor action of the oblique muscles is insignificant in this position. As a result, its paralysis causes relatively large deviations of approximately 30 PD or more esotropia. LR paralysis also tends to present a vicious head position to the side of the paretic muscle, to decrease diplopia or even to avoid it, since esotropia may manifest this symptom. The deficiency of this muscle causes an imbalance in the horizontal muscle forces, causing a strong tendency to develop contracture of its antagonist, medial rectus (MR).

The surgical technique of Carlson and Jampolsky for the correction of VI palsy is performed by longitudinal separation of the vertical straight fibers that are deinserted and restructured one after the other, after the LR.⁽⁵⁾ Although the technique of Carlson and Jampolsky is consecrated, new surgical measures have been proposed for this purpose. In this work, the modified Crouch and Crouch technique was chosen for this treatment, aiming to demonstrate a greater technical ease with satisfactory results, bringing visual quality to the patients.

METHODS

A prospective, descriptive and analytical study of patients seen in the strabismus sector of the Ophthalmological Reference Center of the University Hospital Presidente Dutra of Universidade Federal do Maranhão was carried out. Six patients with esotropia deviation underwent diagnosis of VI cranial nerve palsy, according to the following criteria: esotropia with a minimum of 30DP, with medial rectus contracture; limitation of active abduction, the eye not exceeding the midline; positive passive (clamp) abduction and slow abduction saccadic velocity. Surgical treatment and monthly postoperative follow-up were performed from September 2013 to March 2017.

The surgery was performed according to the technique described: transposition of the superior rectus muscle to immediately superior to the insertion of the lateral rectus muscle was performed, and it was completed with a Foster's suture - suture point of the muscular belly (RS and RL) from 8 to 12 mm place⁽⁶⁾ (Figure 1). As a measure of weakening of the medial rectus, muscle recoil was performed in two patients, being 5mm in one and 7mm in another, and a combination of rectus medial rectus with botulinum toxin application in the other four patients. In cases where botulinum toxin was used, its dilution was done to obtain 50 IU / ml being injected into the 5UI muscle belly (0.1ml) during the surgical procedure.

The topical medications used in the postoperative period consisted of a combination of corticosteroid and antibiotic

(dexamethasone and ciprofloxacin) with weekly dose reduction totaling 30 days of use.

The parameters analyzed were: gender, age, cause of paralysis, time of onset, presence of contracture of the medial rectus of the diseased eye, basic ophthalmologic examination and evaluation of ocular motility with special attention to the presence of PG deviation, deviation in the position opposite to the action of the paralyzed muscle in the preoperative evaluation, the action of the paralyzed muscle and the presence of horizontal or vertical deviations in the postoperative period.

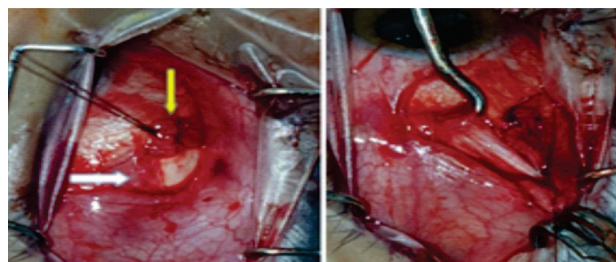


Figure 1: Left: upper rectum (yellow arrow) inserted near the insertion of the lateral rectus (white arrow). Right: upper and lateral junction up to 8mm of insertion by Foster's point

RESULTS

Six patients with VI paralysis were diagnosed, four (66.6%) males and two (33.4%) females. The patients were between 4 and 58 years old, with two cases (33.4%) in the left eye (LE) and four (66.6%) in the right eye (RE) (Table 1). Four of the cases had traumatic etiology, one case of congenital etiology and another, neuropathic. With the exception of the patient with a congenital cause of paralysis, the mother referred to deviance from birth, the other cases had between three and six months of diagnosis.

In the preoperative period one patient presented a deviation of 35 PD, one with a deviation of 45 PD, two patients with a 50 PD deviation and one with a deviation of 115 PD in primary gaze position (PG). All presented evidence of contracture of the MR muscle by the passive duction tests and presence of deviation when fixating in the direction of the medial rectus of the affected eye.

Table 1
Distribution of sixth cranial nerve paralysis cases according to sex, age, etiology, deviation and affected eye

Patients	Sex	Age	Cause	Deviation (PG)	Affected eye
EPR	M	58	Trauma	50 PD	RE
AGPS	M	23	Trauma	45 PD	RE
HVMM	F	04	Congenital	50 PD	LE
JSN	M	22	Trauma	50 PD	LE
ECL	F	14	Neuropathy	35 PD	RE
LFS	M	37	Trauma	115PD	RE

Regarding the function of LR in the preoperative period, two patients had a function of -4.0; three had -5.0 and another patient had a -6.0 function. The MR muscle presented contracted function of +1.0 in three patients, of +2 in two patients and of +3 in one patient. The patients were followed up in six months, with five of them presenting orthotropia in PG, in the third and sixth month after the surgical intervention. The patient showing a deviation of 115 PD in the preoperative period presented a residual deviation

of 35 PD in the postoperative period. This patient required a new surgery, in which a new MR recede was chosen. At the end of the sixth month, the duction examination showed an LR function of -2.0 in three patients, -3.0 in one patient and -4.0 in two patients. The MR muscle presented a function that varied from -1.0 to -2.0 in the postoperative examination.

No residual vertical deviation in the late postoperative period was observed in any of the six patients submitted to the Johnston-Crouch et al procedure (Figure 2). Subjectively, five patients reported improvement of the field of view without diplopia, perceiving it only in extreme versions, only the patient with great preoperative deviation presented diplopia in PG.

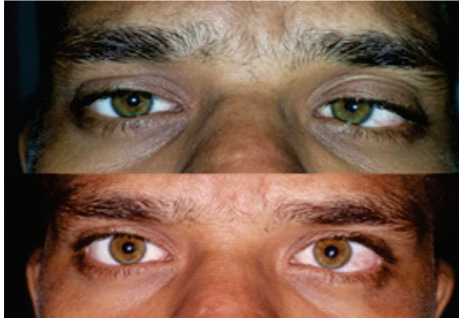

Figure 2: Patient before the intervention and after the surgical procedure

DISCUSSION

Hummleschein, in 1907, was the first to describe the technique of transposing part of the force of the vertical straight lines into horizontal action.⁽⁷⁾ Since then, many modifications have been proposed from this original technique.⁽⁸⁾

Carlson-Jampolsky proposed the longitudinal dissection of the vertical straight lines that are then sutured to each other below the LR and, after being firm, an adjustable suture was made at the insertion of the LR,^(5,8) with MR recede in the case of its contracture. Rosebaum et al. in previous publications emphasized that this procedure would present a theoretical risk of ischemia of the anterior segment and described a similar vertical transposition procedure, but with botulinum toxin use⁽⁹⁾ as an option to the MR recede, observing similar results.

In 2006, Johnston-Crouch et al. proposed the transposition of SR to the site adjacent to the LR insertion, suturing these two muscles to each other 8 to 12 mm posterior to the insertion,⁽¹⁰⁾ associating botulinum toxin with MR,⁽¹¹⁾ as a method of weakening this muscle.

Of the surgical techniques already used to correct this paralysis, the Carlson-Jampolsky proposal is widely accepted by most services, both because of the lower index of anterior segment ischemia, since only the lateral half of the vertical rectus⁽¹¹⁾ and the MR, as well as lower risk of iatrogenic vertical deviations, resulting in a balance of vertical forces. Although well established, this surgery presents as a disadvantage the technical difficulty for its accomplishment and a greater learning curve, being practiced normally by the experienced strabismologist.

In the present study, the technique used in two cases was the one described by Chouch, of transposition of the superior rectus and medial rectus recede, in the other four, the modified Crouch with the use of botulinum toxin was moment of the procedure, in the MR. Despite the use of two slightly different

techniques, five cases presented good results, being orthotropic in PG and only one case presented a deviation of 35 PD in the medium-term postoperative period (six months). In none of the cases presented was vertical deviation induced by the procedure in the medium-term postoperative period.

In this series we can observe a good result with good reproducibility, because it is theoretically a less complex procedure than vertical transposition by other techniques, and the six cases were operated by residents under the guidance of the strabismus tutor.

CONCLUSIONS

The six cases described from patients treated by RS transposition obtained good surgical results with improvement of esotropia and limitation of abduction. All patients in the present study reported subjective improvement of the field with binocular vision.

Despite being a series of only six cases, and having limitations such as the non-measurement of torsional deviation or the short follow-up of these patients, this study serves as support for new ones that may come to corroborate with this technique that emerges as an option for patients which can be affected by this common strabismus.

REFERENCES

1. Curi RL, Costa IC, Barroso TG. Paralisia do VI nervo (abducente). *Rev Bras Oftalmol.* 2013;72(1):59-69.
2. Camargo GB, Hida WT, Goldchmit M, Uesugui CF, Souza-Dias CR. Estrabismo paralítico: revisão de 24 anos da Santa Casa de São Paulo. *Arq Bras Oftalmol.* 2007;70(4):585-7.
3. Richards BW, Jones FR Jr, Younge BR. Causes and prognosis in 4,278 cases of paralysis of the oculomotor, trochlear, and abducens cranial nerves. *Am J Ophthalmol.* 1992;113(5):489-96.
4. Souza-Dias C, Goldchmit M. Os estrabismos: teorias e casos comentados. Rio de Janeiro: Guanabara Koogan; 2011.
5. Carlson MR, Jampolsky A. An adjustable transposition procedure for abduction deficiencies. *Am J Ophthalmol.* 1979;87(3):382-7.
6. Foster RS. Vertical muscle transposition augmented with lateral fixation. *J AAPOS.* 1997;1(1):20-30.
7. Hummelsheim E. Über schneutransplantation am Auge. *Berdtsh Ophthalmol Ges.* 1907;34:248.
8. Teixeira JA, Santos GF. Paralisia do VI nervo craniano. *Oftalmologia pediátrica e estrabismo.* 4a ed. São Paulo: Conselho Brasileiro de Oftalmologia; 2017. p. 1021-6.
9. Rosenbaum AL. Costenbader Lecture. The efficacy of rectus muscle transposition surgery in esotropic Duane syndrome and VI nerve palsy. *J AAPOS.* 2004;8(5):409-19.
10. Struck MC. Augmented vertical rectus transposition surgery with single posterior fixation suture: modification of Foster technique. *J AAPOS.* 2009;13(4):343-9.
11. Couser NL, Lenhart PD, Hutchinson AK. Augmented Hummelsheim procedure to treat complete abducens nerve palsy. *J AAPOS.* 2012;16(4):331-5.

Corresponding author:

Cibele Peixoto Leite Oliveira

E-mail: leite.cibele@yahoo.com.br