

# Choroidal neovascularization following laser pointer-induced macular injury: case report and overview

## *Neovascularização de coroide após lesão macular induzida por laser-pointer: Relato de caso e revisão de literatura*

Lívia da Silva Conci<sup>1</sup> <https://orcid.org/0000-0002-8460-8421>  
Débora Letícia Souza Alves<sup>2</sup> <https://orcid.org/0000-0002-6804-462X>  
Jéssica Cararo Frossard<sup>2</sup> <https://orcid.org/0000-0003-2319-9756>  
Kélcia Kiefer Harchbart<sup>2</sup> <https://orcid.org/0000-0002-3774-6549>  
Alexandre Grobbério Pinheiro<sup>2</sup> <https://orcid.org/0000-0002-8647-3137>

### ABSTRACT

*The purpose is to report a case of laser pointer-induced maculopathy and to describe its characteristics using spectral-domain optical coherence tomography (SD-OCT), further the outcome of treatment with intravitreal injections. A 35-year-old man presented with a 6-day history of central vision loss in his right eye (RE) after an accidental laser pointer discharge (wavelength of 532 nm). He underwent a full ophthalmologic examination, including SD-OCT, which suggested the presence of subfoveal choroidal neovascularization (CNV). This was not confirmed due to the unavailability of tools such as fluorescein angiography, indocyanine green angiography and OCT angiography. Best-corrected visual acuity (BCVA) was initially 20/400 in the RE. Thus, considering a presumed CNV, three intravitreal injections of bevacizumab (the first one combined with triamcinolone acetonide) were performed in the RE. BCVA acuity in his RE improved to 20/25 at 3 months after the first intravitreal injection, with complete resolution of exudation. Over the following 12 months, BCVA remained stable, and no evidence of progression or development of neovascularization was observed. Laser pointer may cause subfoveal CNV when accidentally directed toward the eye. In this case, the presumed CNV induced by laser had an excellent response to bevacizumab and triamcinolone acetonide injections.*

**Keywords:** Lasers; Eye injuries; Choroidal neovascularization; Intravitreal injections; Bevacizumab; Triamcinolone acetonide

### RESUMO

O objetivo é relatar um caso de lesão macular induzida por laser pointer e descrever suas características utilizando a tomografia de coerência óptica de domínio espectral (SD-OCT), assim como o resultado do tratamento com injeções intravítreas. Um homem de 35 anos apresentou uma história de perda da visão central no olho direito (OD) de 6 dias de evolução após um disparo acidental de laser (comprimento de onda de 532 nm). O paciente foi submetido a exame oftalmológico completo, incluindo SD-OCT, que sugeriu a presença de neovascularização coroidal (CNV) subfoveal. Isso não foi confirmado devido à indisponibilidade de ferramentas como angiografia fluoresceínica, angiografia com indocianina verde e angiografia por OCT. A acuidade visual (AV) com melhor correção foi inicialmente de 20/400 no OD. Assim, considerando uma CNV presumida, três injeções intravítreas de bevacizumabe (a primeira combinada com triancinolona acetona) foram realizadas no OD. A AV melhorou para 20/25 aos 3 meses após a primeira injeção intravítrea, com resolução completa da exsudação. Nos 12 meses seguintes, a AV permaneceu estável e nenhuma evidência de progressão ou desenvolvimento de neovascularização foi observada. O laser pointer pode causar CNV quando acidentalmente direcionado para o olho. Nesse caso, a suposta CNV induzida por laser teve uma excelente resposta às injeções de bevacizumabe e triancinolona acetona.

**Descritores:** Lasers; Traumatismos oculares; Neovascularização da coroide; Injeções intravítreas; Bevacizumabe; Triancinolona acetona

<sup>1</sup>Hospital das Clínicas, Faculdade de Medicina, Universidade de São Paulo, São Paulo, SP, Brazil.

<sup>2</sup>Ophthalmology Service, Hospital Universitário Cassiano Antônio de Moraes- Universidade Federal do Espírito Santo, Vitória, ES, Brazil.

Os autores declaram não haver conflito de interesses.

Recebido para publicação em 27/05/2019 - Aceito para publicação em 3/9/2019.

## INTRODUCTION

Light is a portion of the electromagnetic spectrum that is visible to the human eye and is responsible for the sense of sight,<sup>(1)</sup> while LASER (acronym for Light Amplification by Stimulated Emission of Radiation) is originated by a process of optical amplification based on the stimulated emission of electromagnetic radiation.<sup>(2)</sup> First produced in 1960,<sup>(3)</sup> laser has been effectively used in several applications in modern medicine and industry, further for private purposes. High-powered laser pointers have become commercially available and it has been observed an increased incidence of laser pointer induced retinal injuries in several countries, especially in the paediatric population.<sup>(4-12)</sup>

The first case of macular injury induced by laser pointer was reported in 1999, by Luttrull and Hallisey.<sup>(13)</sup> Since then, several cases were described. The spectrum of damage ranges from focal photoreceptor defects to macular holes and retinal hemorrhages associated with loss of visual acuity and central scotoma.<sup>(14)</sup> Besides, there are a few cases of choroidal neovascularization following laser pointer injury.<sup>(10, 15-17)</sup>

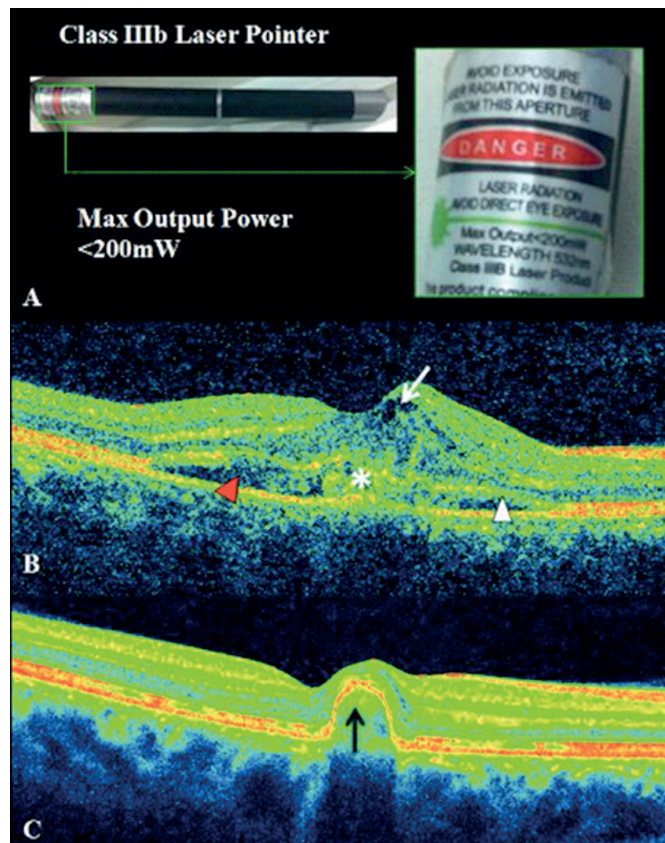
The purpose of this article is to report a laser-induced maculopathy in a healthy 35-year man and to describe its characteristics using spectral-domain optical coherence tomography, as well as the outcome of treatment with intravitreal bevacizumab and triamcinolone acetonide injections.

### Case presentation

A 35-year-old white healthy man presented with a 6-day history of central vision loss in his right eye (RE) after using a laser pointer. He reported an accidental discharge toward his RE while he was testing the device. It was a high-powered laser (200mW), with 532nm wavelength and the pointer was classified as a Class IIIB laser product (Figure 1A).

On examination, his best corrected visual acuity (BCVA) was 20/400 in the RE and 20/20 in the left eye (LE). Biomicroscopy was unremarkable in both eyes and pupillary reflexes were normal. In the RE, fundus examination disclosed an elevated foveal lesion, surrounded by a subretinal haemorrhage in the parafoveal region. On Spectral-domain optical coherence tomography (SD-OCT) (Cirrus, Carl Zeiss Meditec, Dublin, CA), macular thickness map revealed increased central subfield thickness (429µm). On cross-sectional assessment, a subfoveal hyperreflective material was shown above the retinal pigment epithelium (RPE), associated with intraretinal cysts, subretinal fluid and disruption of the ellipsoid zone (Figure 1B). Both fundus examination and SD-OCT were normal in the LE. Tools such as fluorescein angiography, indocyanine green angiography and OCT angiography were unavailable.

Presuming a laser-induced CNV, intravitreal injection of bevacizumab combined with triamcinolone acetonide was performed in the RE. One month later, mean central macular thickness



**Figure 1:** Laser pointer-induced maculopathy. 1A: Photograph of the device used in the injury with a magnified view (inset) of its label. 1B: Spectral domain optical coherence tomography image taken six days after laser injury shows a subfoveal hyperreflective material above the retinal pigment epithelium (white asterisk), associated with intraretinal cysts (white arrow), subretinal fluid (red arrowhead) and disruption of the ellipsoid zone (white arrowhead). 1C: Spectral domain optical coherence tomography image taken thirty days after third bevacizumab intravitreal injection shows a remaining pigment epithelial detachment (black arrow), besides disruption of the ellipsoid zone

decreased from 429µm to 220 µm and BCVA improved from 20/400 to 20/100. Complete resolution of subretinal fluid and intraretinal cysts were seen. The patient underwent two additional intravitreal bevacizumab injections in a monthly interval. BCVA and macular thickness evolution during intravitreal injections are shown in Table 1. Final central subfield thickness was 217µm and BCVA was 20/25. Macular scanning presented a residual pigment epithelial detachment, with no signs of activity (Figure 1C). Over the following 12 months, BCVA remained stable, and no evidence of progression or development of neovascularization was observed.

**Table 1**  
Evolution of best corrected visual acuity (BCVA) and central macular thickness

Time	BCVA (Snellen)	Central macular thickness
Before treatment (six days following laser injury)	20/400	429 µm
30 days after first intravitreal injection (Bevacizumab + Triamcinolone Acetonide)	20/200	220 µm
30 days after second intravitreal injection (Bevacizumab)	20/60	219 µm
30 days after third intravitreal injection (Bevacizumab)	20/25	217 µm

## DISCUSSION

It is well-known that retina is the most vulnerable structure to laser irradiation, because laser is focused by the refractive media of the eye on a very small retinal point, less than 50 micron in diameter. This focusing results in a very considerable increase in energy concentration, about 10,000 fold higher. Therefore, very little laser energy entering the eye can damage the retina.<sup>(18)</sup>

When laser light reaches a tissue surface, it can be reflected, refracted, scattered, absorbed, or transmitted. The fractional intensity of these different processes depends on the optical properties of the tissue, as well as the laser parameters.<sup>(19)</sup> The mechanisms of the light interaction may vary according to wavelength, intensity and duration of the exposure. There are three general mechanisms of light induced ocular damage: thermal, mechanical and chemical. In this context, thermal is the most important one in laser injury, since it leads to protein denaturation, loss of cell integrity and secondary inflammatory reactions.<sup>(20)</sup> It is more pronounced in short-wavelength light, like in the reported case (green laser pointer; wavelength 490–575 nm), compared with long-wavelength light (red laser pointer; wavelength 635–750 nm).<sup>(21)</sup>

The morphology of retinal injuries caused by laser is highly variable. There are some documented cases of disruption of the outer retinal layers,<sup>(22-24)</sup> macular-holes,<sup>(4,5,25-33)</sup> retinal haemorrhage,<sup>(5,25-27,34-36)</sup> and streak-like lesions.<sup>(24,37,38)</sup> Laser pointer injury rarely leads to secondary complications, but laser-induced perforation of Bruch's membrane can cause secondary CNV, like it was seen in a few reported cases<sup>(10,15-17)</sup> and in animals models.<sup>(39)</sup>

The treatment of retinal injury associated with laser pointer is limited and controversial. Systemic corticosteroids have been used in differing regimes and with differing results.<sup>(20,23)</sup> Observation is also an option, as many of these patients will have stabilization of visual acuity over time.<sup>(14)</sup> However, if a CNV forms as a result of direct trauma from the laser to Bruch's membrane, a vascular endothelial growth factor inhibitor is recommended to arrest neovascular growth.<sup>10</sup> In our case, SD-OCT suggested the presence of subfoveal CNV, but it was not confirmed due to the unavailability of tools such as fluorescein angiography, indocyanine green angiography and OCT angiography. Assuming a CNV, we chose to associate an antiangiogenic drug with an intravitreal corticosteroid, due to the inflammatory nature of the process. After that, we got an excellent result, with central macular thickness decrease and sustained improvement of BCVA.

In conclusion, laser pointers can be harmful to the eye, with several manifestations. Although CNV is very uncommon, it can be found in some cases. Treatment options after laser pointer-induced ocular injury are limited. In our case, association of bevacizumab and triamcinolone played an important role to disease control, besides morphological and functional improvement.

## REFERENCES

1. Commission Internationale de l'Eclairage (CIE). International lighting vocabulary. Vienna: CIE; 1987.
2. Tarasov L. Vasil'evi . Laser physics and applications. Moscow: Mir Publishers; 1986. 192 p.
3. Maiman, Theodore H. Stimulated optical radiation in ruby. *Nature*. 1960; 187:493-4.
4. Torp-Pedersen T, Welinder L, Justesen B, Christensen UC, Solborg Bjerrum S, La Cour M, et al. Laser pointer maculopathy - on the rise? *Acta Ophthalmol*. 2018;96(7):749–54.
5. Mtanes K, Mimouni M, Zayit-Soudry S. Laser Pointer-Induced Maculopathy: More Than Meets the Eye. *J Pediatr Ophthalmol Strabismus*. 2018;55(5):312–8.
6. Keunen JE, Delbecq AL, Cruysberg JR, van Meurs JC, Gan IM, Berendschot TT. [Laser pointers are not toys; eye injury with permanent loss of visual acuity]. *Ned Tijdschr Geneesk*. 2014;158:A7813. [Dutch].
7. Raof N, O'Hagan J, Pawlowska N, Quhill F. 'Toy' laser macular burns in children: 12-month update. *Eye (Lond)*. 2016;30(3):492-6.
8. Linton E, Walkden A, Steeples LR, Bhargava A, Williams C, Bailey C, et al. Retinal burns from laser pointers: a risk in children with behavioural problems. *Eye (Lond)*. 2019;33(3):492-504.
9. Alda J, Gómez Sanz F, González Martín-Moro J. Laser pointer maculopathy. A new public health problem? *Arch Soc Esp Oftalmol*. 2017;92(1):1–3.
10. Xu K, Chin EK, Quiram PA, Davies JB, Parke DW 3rd, Almeida DR. Retinal injury secondary to laser pointers in pediatric patients. *Pediatrics*. 2016;138(4).pii: e20161188.
11. Neffendorf JE, Hildebrand GD, Downes SM. Handheld laser devices and laser-induced retinopathy (LIR) in children: an overview of the literature. *Eye (Lond)*. 2019;33(8):1203–14.
12. Raof N, Bradley P, Theodorou M, Moore AT, Michaelides M. The new pretender: a large UK case series of retinal injuries in children secondary to handheld lasers. *Am J Ophthalmol*. 2016;171:88–94.
13. Luttrull JK, Hallisey J. Laser pointer-induced macular injury. *Am J Ophthalmol*. 1999;127(1):95–6.
14. Birtel J, Harmening WM, Krohne TU, Holz FG, Charbel Issa P, Herrmann P. Retinal injury following laser pointer exposure: a systematic review and case series. *Dtsch Arztebl Int* 2017; 114(49): 831-7.
15. Sun Z, Wen F, Li X, Wu D. Early subfoveal choroidal neovascularization secondary to an accidental stage laser injury. *Graefes Arch Clin Exp Ophthalmol*. 2006;244(7):888–90.
16. Fujinami K, Yokoi T, Hiraoka M, Nishina S, Azuma N. Choroidal neovascularization in a child following laser pointer-induced macular injury. *Jpn J Ophthalmol*. 2010;54(6):631–3.
17. Roeder J, Buesgen P, Hoerauf H, Schmidt-Erfurth U, Laqua H, Birngruber R. Macular injury by a military range finder. *Retina*. 1999;19(6):531–5.
18. Belkin M. Ophthalmic manifestations of laser-induced eye injuries. In: Stuck BE, Belkin M., editors. *Laser-inflicted eye injuries: epidemiology, prevention, and treatment*. USA: International Society for Optics and Photonics; 1996. Vol. 2674.
19. Steiner R. Laser-tissue interactions. *Laser and IPL technology in dermatology and aesthetic medicine*. Berlin, Heidelberg: Springer; 2011. p. 23–36.
20. Barkana Y, Belkin M. Laser eye injuries. *Surv Ophthalmol*. 2000 May;44(6):459–78.
21. Robertson DM, McLaren JW, Salomao DR, Link TP. Retinopathy from a green laser pointer: a clinicopathologic study. *Arch Ophthalmol*. 2005;123(5):629–33.
22. Lally DR, Duker JS. Foveal injury from a red laser pointer. *JAMA Ophthalmol*. 2014;132(3):297–297.
23. Hossein M, Bonyadi J, Soheilian R, Soheilian M, Peyman GA. SD-OCT features of laser pointer maculopathy before and after systemic corticosteroid therapy. *Ophthalmic Surg Lasers Imaging*. 2011;42 Online:e135–8.
24. Chen X, Dajani OAW, Alibhai AY, Duker JS, Bauml CR. Long-term visual recovery in bilateral handheld laser pointer-induced maculopathy. *Retin Cases Brief Rep*. 2019 Jan 10. doi: 10.1097/ICB.0000000000000845.
25. Alsulaiman SM, Alrushed AA, Almasaud J, Alzaaidi S, Alzahrani Y, Arevalo JF, et al.; King Khaled Eye Specialist Hospital Collaborative Retina Study Group. High-power handheld blue laser-induced maculopathy: the results of the King Khaled Eye Specialist Hospital Collaborative Retina Study Group. *Ophthalmology*. 2014;121(2):566–72.e1.
26. Xiao H, Liu X, Huang J, Mao Z, Li M, Cao D. [Image characters of optical coherence tomography in laser-induced maculopathy]. *Yan Ke Xue Bao*. 2010;25(2):82-5. Chinese.

27. Shenoy R, Bialasiewicz AA, Bandara AS. Retinal damage from laser pointer misuse—Case series from the military sector in Oman. *Middle East Afr J Ophthalmol*. 2015; 22(3):399-403.
28. Androudi S, Papageorgiou E. Macular Hole from a Laser Pointer. *N Engl J Med*. 2018;378(25):2420-2420.
29. Petrou P, Patwary S, Banerjee PJ, Kirkby GR. Bilateral macular hole from a handheld laser pointer. *Lancet*. 2014;383(9930):1780. Erratum in: *Lancet*. 2014 May 24;383(9931):1806. (2014): 1780.
30. Dhoot DS, Xu D, Srivastava S. High-powered laser pointer injury resulting in macular hole formation. *J Pediatr*. 2014;164(3):668.e1.
31. Alsakran WA, Alsulaiman SM, Ghazi NG. Delayed spontaneous closure of blue laser-induced full thickness macular hole. *Am J Ophthalmol Case Rep*. 2019;13:154-6.
32. Qi Y, Wang Y, You Q, Tsai F, Liu W. Surgical treatment and optical coherence tomographic evaluation for accidental laser-induced full-thickness macular holes. *Eye (Lond)*. 2017;31(7):1078-1084.
33. Porrúa L, Oblanca N, González-López JJ. Spontaneous closure of a blue laser induced full thickness macular hole [English Edition]. *Arch Soc Esp Oftalmol*. 2017;92(1):29-32.
34. Kim RY, Ra H. Observation of changes after peripheral retinal injury by cosmetic laser, using wide-field scanning laser ophthalmoscope: A case report. *Medicine (Baltimore)*. 2019;98(6):e14354.
35. Perez-Montañó CR, Palomares-Ordoñez JL, Ramirez-Estudillo A, Sanchez-Ramos J, González-Saldivar G. Sub-hyaloid and sub-internal limiting membrane macular hemorrhage after laser exposure at music festival: a case report. *Doc Ophthalmol*. 2019;138(1):71-6.
36. Boosten K, Van Ginderdeuren R, Spileers W, Stalmans I, Wirix M, Van Calster J, et al. Laser-induced retinal injury following a recreational laser show: two case reports and a clinicopathological study. *Bull Soc Belge Ophthalmol*. 2011;317(317):11-6.
37. Combillet F, Saunier V, Rougier MB, Delyfer MN, Korobelnik JF. Multimodal imaging in a case of self-inflicted laser-induced maculopathy. *Eur J Ophthalmol*. 2016;26(6):e155-7.
38. Mehta N, Tsui E, Ranka M, Dedania V, Lee GD, Modi Y. Inadvertent self-induced macular laser injury in an 8-year-old girl. *J AAPOS*. 2018;22(5):397-8.
39. Lambert V, Lecomte J, Hansen S, Blacher S, Gonzalez ML, Struman I, et al. Laser-induced choroidal neovascularization model to study age-related macular degeneration in mice. *Nat Protoc*. 2013;8(11):2197-211.

---

Corresponding author:

Lívia da Silva Conci

Endereço: Avenida Marechal Campos, 1355, Setor da Visão, Casa 4, Santa Cecília, Vitória- ES Zip code 29043-260 – Brazil.

Phone: 55 27 33357100

E-mail: livia.conci@gmail.com