

Lagophthalmos in leprosy: clinical experience in an Amazon reference center

Lagoftalmo na hanseníase: experiência clínica em centro de referência amazonense

Gilson Lima Bentes¹ <https://orcid.org/0000-0003-4564-0178>

Suzana Matayoshi² <https://orcid.org/0000-0003-0630-4091>

Carolina Talhari³ <https://orcid.org/0000-0003-2283-069X>

ABSTRACT

Objective: The present study aimed to characterize the epidemiological and clinical profile of patients with lagophthalmos associated with leprosy, seen at the ophthalmology outpatient clinic of Fundação Alfredo da Matta, Manaus, Amazonas. **Methods:** This is a retrospective study carried out by analyzing the medical records of the patients included in the study. Sex, age, clinical form, degree of disability in diagnosis and outcome were obtained from medical records. Onset, type of impairment (unilateral or bilateral), degree of intensity of lagophthalmos and associated eye changes were also compiled. **Results:** 65 patients were included; 66.1% were male and 53.8% were older than 60 years. Regarding the operational classification of leprosy, most patients (81.5%) were multibacillary: 33.8% in the form of borderline leprosy and 47% virchowian. 36.9% of cases had ocular sequelae associated with lagophthalmos: corneal opacity, epiphora, band keratopathy, and corneal neovascularization. 41.6% progressed to blindness. Lagophthalmos was performed clinically in 23 patients and the surgical approach was indicated in 42. Regarding surgical treatment, it consisted mainly of gold weight implantation and Tessier's canthoplasty. **Discussion:** Lagophthalmos in this sample affected more elderly men, was related to the multibacillary form, with leprosy-like leprosy as reported in the literature. The diagnosis of lagophthalmos was delayed in most cases, explaining the large number of sequelae including blindness. **Conclusion:** The present study reinforces the need for early eye care so that the potential and serious sequelae associated with this condition are avoided.

Keywords: *Mycobacterium leprae*; Leprosy; Lagophthalmos; Eye diseases; Keratopathy; Blindness

RESUMO

Objetivo: O presente trabalho teve por objetivo caracterizar o perfil epidemiológico e clínico de pacientes com lagoftalmo associado à hanseníase, atendidos no ambulatório de oftalmologia da Fundação Alfredo da Matta, Manaus, Amazonas. **Métodos:** Trata-se de estudo retrospectivo realizado por meio da análise dos prontuários clínicos dos pacientes incluídos no estudo. Sexo, idade, forma clínica, grau de incapacidade no diagnóstico e desfecho foram obtidos dos prontuários. Início, tipo de comprometimento (unilateral ou bilateral), grau de intensidade do lagoftalmo e alterações oculares associadas também foram compilados. Resultados: Foram incluídos 65 pacientes; 66,1% eram do sexo masculino e 53,8% tinham idade superior a 60 anos. Em relação à classificação operacional da hanseníase, a maioria dos pacientes (81,5%) era multibacilar: 33,8% na forma de hanseníase borderline e 47% virchowiana. 36,9% casos apresentavam sequelas oculares associadas ao lagoftalmo: opacidade corneana, epífora, ceratopatia em faixa, e neovascularização corneana. 41,6% evoluíram para a cegueira. O lagoftalmo foi conduzido de forma clínica em 23 pacientes e a abordagem cirúrgica foi indicada em 42. Em relação ao tratamento cirúrgico consistiu principalmente no implante de peso de ouro e na cantoplastia de Tessier. **Discussão:** O lagoftalmo nessa casuística acometeu mais homens idosos, esteve relacionado à forma multibacilar, com hanseníase do tipo virchowiano como relatado na literatura. O diagnóstico de lagoftalmo foi tardio na maioria dos casos, explicando o grande número de sequelas incluindo a cegueira. **Conclusão:** O presente estudo reforça a necessidade de acompanhamento oftalmológico precoce para que as potenciais e graves sequelas associadas a essa condição sejam evitadas.

Descritores: *Mycobacterium leprae*; Leprosy; Lagoftalmo; Doenças oculares; Ceratopatia; Cegueira

¹Ophthalmology Outpatient Clinic, Alfredo da Matta Dermatology and Venereology Foundation, Manaus City, Amazonas State, Brazil.

²Medical School, University of São Paulo, São Paulo City, São Paulo State, Brazil.

³Dermatology Department, Amazonas State University, Manaus City, Amazonas State, Brazil.

The authors declare no conflict of interest

Received for publication 22/6/2020 - Accepted for publication 2/11/2020

INTRODUCTION

Hansen's disease (HD) is a chronic bacterial disease transmitted by bacillus *Mycobacterium leprae*, which is an etiological agent that multiplies itself slowly and that mainly spreads itself through the coldest areas of the body, such as hands and feet; it can also affect eyes, mucous membranes, bones and testicles. This pathogen was never cultivated *in vitro*;⁽¹⁾ this bacillus can cause lesions in eyeballs and outer parts of the eye. Lagophthalmos, corneal anesthesia/ hypoesthesia, keratitis and iridocyclitis are seen as ophthalmological complications associated with leprosy. All these conditions can lead to decreased visual acuity and blindness.⁽²⁾

Up to 60% of patients with HD can have ophthalmic changes.^(3,4) Lagophthalmos is one of the most common changes (15% to 22%) and it can occur in all types of Hansen's disease, before or after treatment.⁽⁵⁾

Decreased blinking and lagophthalmos, which consists of inability to complete eyelid closure, are ocular manifestations directly related to facial nerve damage (VII cranial nerve).^(3,6,7) The zygomatic and temporal branches of this nerve are affected in cases of lagophthalmos.^(4,8,9)

Lagophthalmos causes corneal exposure, microtrauma, secondary infections, and, finally, progressive corneal opacification,^(10,11) which leads to decreased visual acuity and blindness. Therefore, it is important highlighting the importance of correct diagnosis and treatment.

The aim of the current study was to correlate the clinical Hansen's disease forms to lagophthalmos and to its treatment.

METHODS

Descriptive retrospective study carried out by assessing clinical records of leprosy patients examined by one of the authors (GB) at Alfredo da Mata Foundation (FUAM), in Manaus City, Amazonas State, Brazil from January 2004 to December 2014. Patients were treated consecutively through routine scheduling, at the ophthalmology outpatient clinic.

The following data were obtained from the medical records: sex, age, clinical form (histopathological examination), operational form of Hansen's disease, degree of disability at diagnosis, cure and outcome. Onset included impairment type (unilateral or bilateral), degree of lagophthalmos intensity (mild: up to 3 mm; moderate: between 3 mm and 6 mm, and severe: greater than 6 mm), associated eye changes, clinical and surgical treatment. The following data were also assessed: clinical Hansen's disease form (defined by clinical and histopathological exams), operational form (defined by bacilloscopy: paucibacillary – PB - or multibacillary - MB), degree of physical disability (GIF) at diagnosis, and treatment, in addition to outcomes (cure, death, non-adherence to treatment or transfer to another city).

The following ophthalmological data were compiled from clinical records: ophthalmological clinical situation onset, type of lagophthalmos (unilateral or bilateral), degree of lagophthalmos intensity, Bell's phenomenon assessment, ocular sequelae and blindness related to lagophthalmos.

The degree of lagophthalmos⁽¹²⁾ intensity is classified as mild (up to 3 mm), moderate (between 3 mm and 6 mm), and severe (greater than 6 mm). It is measured with millimeter ruler, with the patient in vertical position. The residual partial opening (between the upper and lower eyelid edges) was measured, after

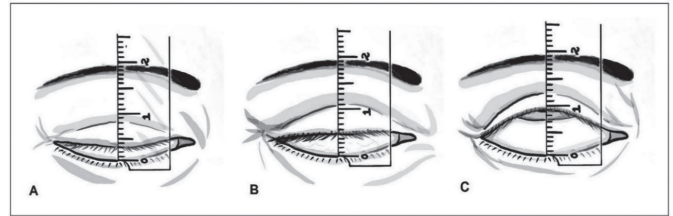


Figure 1: Lagophthalmos intensity: A) mild (up to 3 mm), B) moderate (between 3 mm and 6 mm) and severe (greater than 6 mm).

requesting the patient to close the eyes⁽³⁾ (Figure 1).

Biomicroscopy exam (slit lamp) results recorded for ocular structures assessment (cilia, eyelid border, corneal surface, bulbar conjunctiva, upper and lower tarsal conjunctiva, and lacrimal points) were also inserted in the clinical records.

Measurement of patients' visual capacity at distance was carried out by exams with and without optical assistance (glasses or lenses) and compiled from the clinical record. The measurement scale used was 5% (20/400) to 100% (20/20). Data on counting fingers exam (examiner 1 to 2 meters away from the patient), perception of shapes or hand motion (HM), and light perception test (PL) were included in the clinical record patients with visual acuity lower than 5%, for the study.

Degree of physical disability (GIF) assessment was carried out during diagnosis and at patient's discharge, based on criteria recommended by the Ministry of Health (Attachment 1).⁽¹³⁾

Patients with grade 0 GIF have preserved eyelid muscle strength and corneal sensitivity, but presented low vision (patient counts fingers at 6 meters or visual acuity greater than, or equal to, 0.1 or 6:60). Patients with grade 1 GIF have decreased eyelid muscle strength, without visible deficiencies and/or decreased or lost corneal sensitivity (delayed or absent response to dental floss contact or decreased/absent blinking). Patients with grade 2 GIF have evident eyelid manifestations, with lagophthalmos, ectropion, trichiasis, corneal opacity, lesions in the anterior chamber (iridocyclitis), and compromised visual acuity (patient cannot count fingers at 6 meters or visual acuity lower than 0.1 or 6:60, excluding other causes), which features usually irreversible blindness.⁽¹³⁾

Data were tabulated in Microsoft Excel spreadsheets and subjected to descriptive statistical analysis based on absolute frequency and relative frequency data. Sex and age group were taken into account to analyze the epidemiological and clinical profiles. Analyses were performed by correlating lagophthalmos development time to the relationship between clinical manifestation severity and patient's age group.

FUAM Ethics Committee approved the current research (CAAE: 99339018.6.0000.0002).

RESULTS

The current study assessed 65 patients with lagophthalmos in association with Hansen's disease; 43 (66.1%) were men and 22 (33.8%) were women. Regarding the age group, most participants (35; 53.8%) were over 60 years old. Regarding classification, three (4.6%) patients had indeterminate Hansen's disease (IT); nine (13.7%) had tuberculoid Hansen's disease (TT), 22 (33.8%) had borderline Hansen's disease (BB) and 31 (47%) patients had lepromatous Hansen's disease (LL). Regarding the operational classification, 12 (18.5%) patients had the paucibacillary form of the disease (BP) and 53 (81.5%) had the multibacillary form of

Table 1
Epidemiological and clinical features of the 65 patients with lagophthalmos associated with leprosy

Features		Sex			Age Group										
		Men		Women		Total		15 to 24 years		25 to 44 years		45 to 59 years		60 or more years	
		(N=22)	(N=43)	(N=65)	(N=2)	(N=11)	(N=17)	(N=35)	n	%	n	%	n	%	n
Operational classification															
At diagnosis	Paucibacillary	7	31.8	5	11.6	12	18.5	0	0	0	0	3	17.6	9	25.7
	Multibacillary	15	68.2	38	88.4	53	81.5	2	100	11	100	14	82.4	26	74.3
Clinical forms															
	Tuberculoid	5	22.7	4	9.3	9	13.8	0	0	0	0	2	11.8	7	20
	Indeterminate	2	9.1	1	2.3	3	4.6	0	0	1	9.09	1	5.88	1	2.86
	Borderline	3	13.6	19	44.2	22	33.8	1	50	9	81.8	7	41.2	5	14.3
	Lepromatous	12	54.5	19	44.2	31	47.7	1	50	1	9.09	7	41.2	22	62.9

Table 2
Time elapsed between Hansen's disease diagnosis and lagophthalmos onset based on the clinical leprosy form

Time elapsed between Hansen's disease diagnosis and lagophthalmos onset	CLINICAL FORMS									
	Tuberculoid		Indeterminate		Borderline		Lepromatous		Total	
	n=9	%	n=3	%	n=22	%	n=31	%	Total	%
0 to 5 years	4	44.4	0	0	11	50	6	19.4	21	32.3
5 to 10 years	1	11.1	0	0	4	18.2	2	6.45	7	10.8
10 to 15 years	2	22.2	0	0	5	22.7	4	12.9	11	16.9
15 to 20 years	0	0	1	33.3	0	0	5	16.1	6	9.23
20 to 25 years	1	11.1	0	0	0	0	3	9.68	4	6.15
25 to 30 years	0	0	1	33.3	0	0	4	12.9	5	7.69
30 to 35 years	1	11.1	1	33.3	0	0	2	6.45	4	6.15
35 to 40 years	0	0	0	0	0	0	1	3.23	1	1.54
Did not know	0	0	0	0	2	9.09	4	12.9	6	9.23

it (MB) (Table 1).

Twenty-one (32.3%) patients developed lagophthalmos less than five years after the diagnosis of Hansen's disease; seven (10.8%), between five and ten years old; 11 (16.9%), between ten and 15 years old; 6 (9.2%), between 15 and 20 years old; four (6.1%), between 20 and 25 years old; five (7.6%), between 25 and 30 years old; 4 (6.1%), between 30 and 35 years and one (1.5%), between 35 and 40 years after the diagnosis of Hansen's disease (Table 2).

The degree of physical disability (GIF), at the time of Hansen's disease diagnosis, was 2 for 38 (58%) patients, 0 for 14 (21%) patients, and 1 for 5 (7%) patients.

Lagophthalmos was identified in 94 eyes; impairment was unilateral in 36 (55.3%) patients and bilateral in 29 (44.6%) ones. This condition was mild in 13 cases (20%), moderate in 11 (16.9%), and severe in 12 (18.5%) patients, in cases of unilateral lagophthalmos. Bilateral lagophthalmos was classified as mild in ten (15.4%) cases, moderate in five (7.6%), and severe in eight (12.3%). In the group of patients with bilateral lagophthalmos, 23 (64%) had MB form Hansen's disease and 6 (36%) had its PB form. Among patients with unilateral lagophthalmos, 30 (83%) had MB Hansen's disease and six (17%) had its PB form (Table 3)

Among the 65 patients, 24 (36.9%) had one or more ocular sequelae associated with lagophthalmos. The most frequent ones

were bulbar atrophy (two; 8.3%), band keratopathy (four; 16.6%), conjunctivitis (four; 16.6%), pterygium (four; 16.6%), epiphora (five; 20.8%) and total corneal opacity (six; 3%). The most frequency sequelae among patients with with lagophthalmos were associated with its lepromatous form (14; 58.3%).

Twelve (26.6%) patients presented blindness due to severe sequelae associated with lagophthalmos; most of them (8; 17.7%) had MB forms of the disease. Regarding Bell's phenomenon, five (7.7%) patients absent or abolished reaction, and two of them developed blindness.

Clinical treatment with lubricating eye drops and physical therapy to strengthen the orbicularis muscle were recommended for 23 (35.4%) patients. Surgical treatment was recommended for 42 patients and performed in 25 of them (38.4%). The most used surgical techniques for lagophthalmos correction were gold weight implant (Figure 2), Tessier's canthoplasty and the association of these two techniques.

The number of patients with grade 2 GIF increased from 38 (58%) to 51 (78%) after treatment discharge

DISCUSSION

Patients with confirmed diagnosis of lagophthalmos in Brazil are classified as grade 2 GIF. Research showed that physical

Table 3
Lagophthalmos classification based on the intensity and clinical form of Hansen's disease

Lagophthalmos classification		Clinical Form of Leprosy									
		Tuberculoid		Indeterminate		Borderline		Lepromatous		Total	
		N=9		N=3		N=22		N=31		N=65	
Type of Lagophthalmos	Lagophthalmos Intensity	n	%	n	%	n	%	n	%	n	%
Unilateral Lagophthalmos	Mild	2	22,2	2	66,7	3	13,6	6	19,4	13	20
	Moderate	1	11,1	0	0	6	27,3	4	12,9	11	16,9
	Severe	1	11,1	0	0	9	40,9	2	6,45	12	18,5
Bilateral Lagophthalmos	Mild in both eyes	3	33,3	0	0	3	13,6	4	12,9	10	15,4
	Moderate in both eyes	0	0	0	0	0	0	5	16,1	5	7,69
	Severe in both eyes	0	0	0	0	0	0	8	25,8	8	12,3
	Severe RE and moderate LE	1	11,1	0	0	0	0	1	3,23	2	3,08
	Moderate RE and mild LE	1	11,1	0	0	0	0	1	3,23	2	3,08
	Severe RE and mild LE	0	0	0	0	1	4,55	0	0	1	1,54
	Mild RE and moderate LE	0	0	1	33,3	0	0	0	0	1	1,54

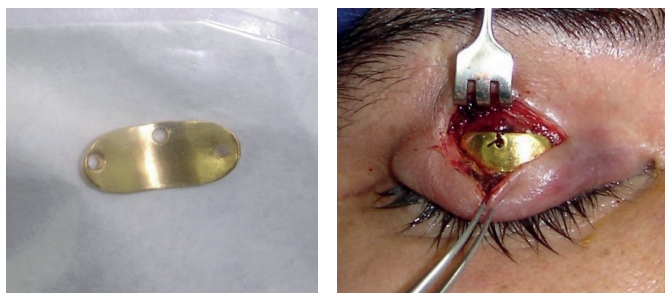


Figure 2: Sterile surgical gold weight implant and intraoperative appearance showing its insertion below the orbicularis muscle

disabilities associated with Hansen's disease were rare in patients with less than one year evolution. One to three years after the diagnosis, this rate increases to 3.9% and to 25% at late diagnosis (up to 8-year evolution).⁽¹⁴⁾ Approximately 70% of patients diagnosed with lagophthalmos and with the MB forms of Hansen's disease in China had more than 10-year disease evolution.⁽¹⁵⁾

Among the 51 patients with grade 2 GIF at the moment of recovery, 34 (51.5%) were men and 17 (25.7%) were women. Men were prevalent in Brazilian research conducted with 28 patients (63%).⁽¹⁶⁾ Moschioni et al.⁽¹⁷⁾ also observed that men had more deformities associated with Hansen's disease than women. Such a fact was attributed to the lower demand for health centers, fear that the stigma related to the disease would cause the patient to be fired and because, in general, male individuals perform heavier physical activities, which could contribute to the appearance and worsening of deformities.

Lepromatous (LL) Hansen's disease occurs in individuals with less effective cellular immunity against *M. leprae*. There is greater propensity for the emergence of leprosy reactions in the borderline form of the disease, which are important causes of physical disabilities such as lagophthalmos.⁽¹⁸⁾ Kusagur et al state that patients with the LL form have direct eye damage caused by the bacillus, whereas this compromise is indirect in the tuberculoid form and happens via hematogenous.⁽¹⁹⁾

There was prevalence of lagophthalmos in patients older than 60 years with MB Hansen's disease (n=26; 74%). Similar results were found in 57 patients with lagophthalmos in Nepal. (20) Age was a significant and independent factor for blindness

occurrence in a study conducted with 1137 leprosy patients in India. Patients aged 40 years, or older, were seven times more likely to develop blindness than those under the age of 40. This study also showed that patients over 60 years were 15 times more likely to be blind than those under 60 years.⁽²¹⁾

Lewallen et al. suggested that bilateral lagophthalmos is more often observed in patients with MB Hansen's disease due to greater *M. leprae* proliferation in the facial nerves and to higher frequency of inappropriate treatment provided to this group of patients.⁽²²⁾ The current study recorded greater prevalence of the MB form in unilateral cases.

Lagophthalmos was related to blindness in 12 patients (26.6%), most of them had the multibacillary or lepromatous form. A study conducted by Malu et al. with 311 leprosy patients showed blindness in 74 affected eyes - keratitis and corneal opacity associated with lagophthalmos was its main causes.⁽¹⁰⁾ Total corneal opacity caused blindness in 23.2% of leprosy patients in Nigeria.⁽²³⁾

It is important highlighting the evolution of physical disability degree, which was Grade 2 GIF in 38 patients at the time of diagnosis. Grade 2 GIF was observed in 51 patients in a new examination conducted upon discharge from treatment. Some factors must be taken into account:

1. Admission of patients with advanced physical disability, which tend to worsen with aging - it corroborates the observations made by Waziri-Erameh and Daniel E.^(15,24)
2. There is sequelae despite disease control
3. Medication discharge in the health system is linked to infectious process control rather than to sequelae solution.

The physical disability classification is not adequate to quantify the ocular sequelae treatment and it should be viewed with caution as ophthalmic therapeutic approach success indicator.

Lagophthalmos diagnosis must be made early in order to avoid potential and serious sequelae associated with this condition. Ophthalmological follow-up of leprosy patients must be periodic and continuous, even after discharge from polychemotherapy. Lagophthalmos appears late in many patients; eventually, after cure or outpatient discharge, even after the end of the recommended therapeutic regimen.^(24,25)

Patients with Hansen's disease, mainly those with the MB forms, should be routinely examined by an ophthalmologist in

order to avoid blindness.

The earlier the diagnosis of lagophthalmos, the greater the possibility of preventing and rehabilitating ocular sequelae associated with this condition. Estimates show the likelihood of minimizing or reversing lagophthalmos within up to six months. The peripheral nerve injury tends to become permanent and irreversible after six months of disease evolution.⁽²⁶⁾

Only few recent articles address surgical treatment for lagophthalmos associated with Hansen's disease comparing surgical techniques. Thus, the used treatments derive from techniques used for paralytic lagophthalmos of different causes (mainly related to neoplastic, surgical and traumatic sequelae).

The gold weight implant was the most recommended surgical technique in the current study (Figure 2). This technique provides excellent vertical eyelid closure based on gravity using.⁽²⁷⁾ (figura3) Although the gold weight implant is technically fast and effective, it is currently no longer available in SUS at the present time; so alternatives such as Tessier's canthoplasty and tarsorrhaphy are the most viable options at the moment. Special attention should be paid to Tessier's canthoplasty, which allows reducing the vertical and horizontal eyelid slit. Both tarsorrhaphy and Tessier's canthoplasty promote asymmetry in comparison to the normal side.

It is important pointing out that surgery does not restore the physiological eyelid occlusion⁽²⁸⁾ since its goal is to decrease the exposed surface and, consequently, to minimize or prevent corneal damage progression. On the other hand, need of combining several procedures to achieve more satisfactory results is often experienced.

CONCLUSION

Elderly, multibacillary men with LL Hansen's disease presented unilateral or bilateral lagophthalmos of moderate and severe degree in the current study. Lagophthalmos associated with Hansen's disease diagnosis emphasized the need of early and continuous eye-care assessment to minimize lagophthalmos complications even after the infection process has healed.

REFERENCES

1. Stefani MM, Rosa PS, Costa MB, Schetinni AP, Manhães I, Pontes MA, et al. Leprosy survey among rural communities and wild armadillos from Amazonas state, Northern Brazil. *PLoS One*. 2019;14(1):e0209491.
2. Grzybowski A, Nita M, Virmond M. Ocular leprosy. *Clin Dermatol*. 2015;33(1):79–89.
3. Kamble KM, Gitte SV, Sabat RN. Efficacy of steroid and physiotherapy in early reported lagophthalmos of patient affected with leprosy. A report from tribal dominated leprosy endemic state of India. *Indian J Lepr*. 2016;87(4):227–31.
4. Moss HE. Eyelid and facial nerve disorders. In: Moss HE, editor. Liu, Volpe, and Galetta's *Neuro-Ophthalmology: Diagnosis and management*. 3rd ed. Philadelphia: Elsevier; 2019. p. 449–88.
5. Chavarro-Portillo B, Soto CY, Guerrero MI. *Mycobacterium leprae's* evolution and environmental adaptation. *Acta Trop*. 2019;197:105041.
6. Lewallen S, Tungpakorn NC, Kim SH, Courtright P. Progression of eye disease in "cured" leprosy patients: implications for understanding the pathophysiology of ocular disease and for addressing eyecare needs. *Br J Ophthalmol*. 2000;84(8):817–21.
7. Hogeweg M, Keunen JE. Prevention of blindness in leprosy and the role of the Vision 2020 Programme. *Eye (Lond)*. 2005;19(10):1099–105.

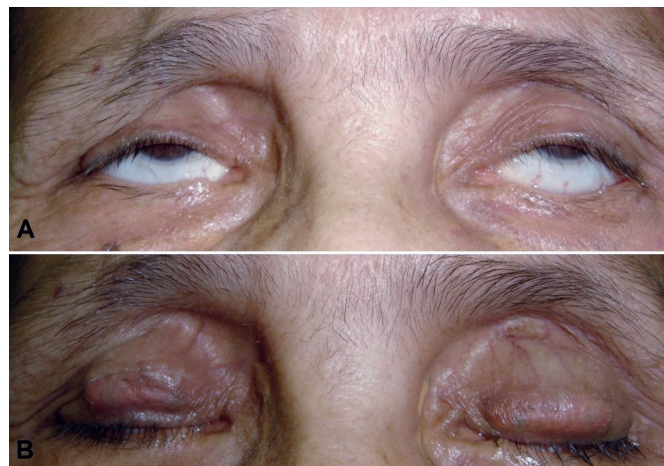

Figure 3: Bilateral lagophthalmos in a leprosy patient who underwent surgical correction using the gold weight implantation technique. A.: preoperative in an attempt of eyelid occlusion; B.: postoperative with corrected bilateral lagophthalmos

8. Turkof E, Richard B, Assadian O, Khatri B, Knolle E, Lucas S. Leprosy affects facial nerves in a scattered distribution from the main trunk to all peripheral branches and neurolysis improves muscle function of the face. *Am J Trop Med Hyg*. 2003;68(1):81–8.
9. Forno EA. Lagoftalmo paralítico. In: Matayoshi S, Forno EA, editors. *Manual de cirurgia plástica ocular*. São Paulo: Roca; 2004. p. 79–86.
10. Malu KN, Malu AO. Blindness in leprosy patients of Kaduna State, Northern Nigeria. *Trop Doct*. 1995;25(4):181–3.
11. Mvogo CE, Bella-Hiag AL, Ellong A, Achu JH, Nkeng PF. Ocular complications of leprosy in Cameroon. *Acta Ophthalmol Scand*. 2001;79(1):31–3.
12. Linhares JD, França VP, Soares EJ. Lagoftalmo paralítico: uma proposta de classificação clínico-cirúrgica. *Arq Bras Oftalmol*. 1995;58(5):319–24.
13. Brasil. Ministério da Saúde. Secretaria de Vigilância em Saúde, Departamento de Vigilância das Doenças Transmissíveis. *Guia prático sobre a hanseníase*. Brasília (DF): Ministério da Saúde; 2017.
14. Soares LS, Pimentel AF, Ferreira AP. The impact of multidrug therapy on the epidemiological pattern of leprosy in Juiz de Fora, Brazil O impacto da poliquimioterapia no perfil epidemiológico da hanseníase em Juiz de Fora, Brasil. *Cad Saúde Pública*. 2000;16(2):343–50.
15. Waziri-Erameh MJ, Omoti AE. Ocular leprosy in Nigeria: a survey of an Eku leprosarium. *Trop Doct*. 2006;36(1):27–8.
16. Angelucci R, Sampaio P, Proto R, Sato L, Rehder JR. Análise das principais manifestações oculares de pacientes hansenianos nas regiões Norte e Sudeste do Brasil. *Rev Bras Oftalmol*. 2007;66(4):236–41.
17. Moschioni C, Antunes CM, Grossi MA, Lambertucci JR. Risk factors for physical disability at diagnosis of 19,283 new cases of leprosy. *Rev Soc Bras Med Trop*. 2010;43(1):19–22.
18. Talhari S, Penna GO, Gonçalves HO. Hanseníase. Aspectos gerais da hanseníase, agente etiológico, transmissão, patogenia, classificação, manifestação clínica, diagnóstico. Rio de Janeiro: DiLivros; 2015. p. 217.
19. R. Kusagur S. S. Kusagur M, K.J.G. A Clinical study of ocular manifestations in leprosy. *J Evol Med Dent Sci*. 2013;2(36):6816–23.
20. Lubbers WJ, Schipper A, Hogeweg M, de Soldenhoff R. Paralysis of facial muscles in leprosy patients with lagophthalmos. *Int J Lepr Other Mycobact Dis*. 1994;62(2):220–4.
21. Thompson KJ, Allardice GM, Babu GR, Roberts H, Kerketta W, Kerketta A. Patterns of ocular morbidity and blindness in leprosy—a three centre study in Eastern India. *Lepr Rev*. 2006;77(2):130–40.

22. Lewallen S, Courtright P. Ocular Involvement in Leprosy. In: Nunzi Enrico M, editor. *Leprosy: A practical guide*. Verlag: Springer International Publishing; 2012. p. 247–54.
23. Ebeigbe JA, Kio F. Ocular leprosy in institutionalized Nigerian patients. *Ghana Med J*. 2011;45(2):50–3.
24. Daniel E, Ffytche TJ, Kempen JH, Rao PS, Diener-West M, Courtright P. Incidence of ocular complications in patients with multibacillary leprosy after completion of a 2 year course of multidrug therapy. *Br J Ophthalmol*. 2006;90(8):949–54.
25. Medina NH, Marzliak MLC, Lafrattá TE. Vigilância epidemiológica das incapacidades oculares em hanseníase. *Hansen Int*. 2004;29(2):101–5.
26. Kiran KU, Hogeweg M, Suneetha S. Treatment of recent facial nerve damage with lagophthalmos, using a semistandardized steroid regimen. *Lepr Rev*. 1991;62(2):150–4.
27. Wolkow N, Chodosh J, Freitag SK. Innovations in Treatment of Lagophthalmos and Exposure Keratopathy. *Int Ophthalmol Clin*. 2017;57(4):85–103.
28. Courtright P, Lewallen S. Current concepts in the surgical management of lagophthalmos in leprosy. *Lepr Rev*. 1995;66(3):220–3.

Corresponding author

Gilson Lima Bentes

E-mail: gilsonbentes10@gmail.com

APPENDIX 1
Criteria for assessing Physical Disability Degree (GIF)

DEGREE	FEATURES
0	<ul style="list-style-type: none"> ▪ Eyes: preserved eyelid muscle strength and corneal sensitivity, counting fingers at 6 meters or visual acuity greater than or equal to 0.1 or 6:60 ▪ Hands: preserved hand muscle strength and sensitivity; feels the monofilament 2g (lilac) or the lightest touch of ballpoint pen ▪ Feet: preserved foot muscle strength and sensitivity; feels the monofilament 2g (lilac) or the touch of ballpoint pen
1	<ul style="list-style-type: none"> ▪ Eyes: decreased eyelid muscle strength, without visible deficiencies and/or decreased or lost corneal sensitivity delayed or absent response to dental floss contact or decreased/absent blinking ▪ Hands: decreased hand muscle strength, without visible deficiencies and/or decreased or lost corneal sensitivity, does not feel the monofilament 2g (lilac) or the touch of ballpoint pen ▪ Feet: decreased foot muscle strength, without visible deficiencies and/or decreased or lost corneal sensitivity, does not feel the monofilament 2g (lilac) or the touch of ballpoint pen
2	<ul style="list-style-type: none"> ▪ Eyes: evident deficiencies caused by leprosy, such as lagophthalmos, ectropion, trichiasis, corneal opacity, lesions in the anterior chamber (iridocyclitis), and visual acuity is compromised (patient cannot count fingers at 6 meters or visual acuity less than 0.1 or 6:60, excluding other causes) ▪ Hands: evident deficiencies caused by leprosy, such as claws, bone resorption, muscle atrophy, contractures, trophic and/or traumatic wounds ▪ Feet: evident deficiencies caused by leprosy, such as claws, bone resorption, muscle atrophy, contractures, trophic and/or traumatic wounds

Source: Adapted from Brasil. Ministério da Saúde; Secretaria de Vigilância em Saúde, Departamento de Vigilância das Doenças Transmissíveis; Guia prático sobre a hanseníase; Brasília (DF): Ministério da Saúde; 2017.⁽¹³⁾