

# Multiple layers on the Descemet membrane

## *Múltiplas camadas na membrana de descemet*

---

Samuel Montenegro Pereira<sup>1</sup> <https://orcid.org/0000-0002-4343-7769>  
Juliana de Lucena Martins Ferreira<sup>2</sup> <https://orcid.org/0000-0001-5481-3400>  
Marilia Cavalcante Araújo<sup>1</sup> <https://orcid.org/0000-0002-0257-4142>  
Antônio Lucas Oliveira Correia<sup>1</sup> <https://orcid.org/0000-0002-9345-7389>  
Fernando Queiroz Monte<sup>1</sup> <https://orcid.org/0000-0002-0459-9642>

### ABSTRACT

*To relate a case not described previously in the national multilateral ophthalmological literature of Descemet's membrane. A 59-year-old pseudophakic woman diagnosed with bullous keratopathy underwent penetrating keratoplasty with an unusual finding of multiple layers of Descemet's membrane, which were variable in shape and thickness. In addition, ovoid bodies with negative Gocott-Gomori (GMS) color were present. Discussion and Conclusion: As Descemet's membrane has a fetal and a postnatal period in its development, it is frequently and well identifiable in histological sections in adults. In the case presented, in which other layers are present, there is evidence of spherical bodies that could mean that the potential to produce other layers may remain into later adulthood.*

**Keywords:** Descemet membrane; Bullous keratopathy; Keratoplasty, penetrating

### RESUMO

Relato de caso não descrito na literatura oftalmológica nacional de múltiplas camadas da membrana de Descemet. Mulher de 59 anos, pseudofácica, com diagnóstico de ceratopatia bolhosa, foi submetida à ceratoplastia penetrante em olho direito, sendo encontrado achado incomum de multiplicidade de camadas da membrana de Descemet, variáveis em forma e espessura, além de corpos ovoides com coloração de metamina de prata de Gocott-Gomori (GMS) negativa. Como a membrana de Descemet tem no seu desenvolvimento um período fetal e outro pós-natal que frequentemente é bem identificável nos cortes histológicos em adultos. No caso apresentado, em que outras camadas estão presentes, há evidência de corpos esféricos que poderiam significar que a potencialidade de produzir outras camadas pode permanecer na fase adulta mais tardia.

**Descritores:** Lâmina limitante posterior; Ceratopatia bolhosa; Ceratoplastia penetrante

---

<sup>1</sup>Fortaleza General Hospital, Fortaleza City, Ceará State, Brazil.

<sup>2</sup>Christus University Center – Unichristus, Fortaleza City, Ceará State, Brazil.

**The authors declare no conflict of interest**

Received for publication 2/3/2020 - Accepted for publication 23/9/2020.

## INTRODUCTION

Cornea is the medium presenting the highest refractive index in the eye. It is covered by epithelium of approximately 50-60 microns, which is located on the basal membrane - composed of type IV collagen. The Bowman layer is located just below this membrane; it is an acellular structure that acts as barrier against the entry of epithelium agents into the underlying stroma. The corneal stroma lies under the Bowman layer; its blood and lymph vessel absence, and presence of precisely adjusted collagen fibers, give this tissue the characteristic transparency of its functionality.<sup>(1)</sup> Such features result in cornea immunologic privilege due to the absence of immune cells in the corneal stroma, which account for low risk of immune rejection after corneal transplants.<sup>(2)</sup>

The Descemet membrane is located under the stroma and works as basal membrane. Its main function is to promote deturgescence and to allow adequate tissue dehydration and, consequently, its transparency. The thickness of the descemet membrane structure ranges from 5 to 10 microns, with three-dimensional web of type IV collagen fibrils.<sup>(3)</sup> The endothelium is a single layer presenting approximately 5 microns in thickness. Another layer was discovered in 2013, it was called DUA and is located between the stroma and the Descemet membrane. It was described as acellular and measures approximately 10-15 microns. It is composed of 10-15 transversely-grouped type I collagen lamellae.<sup>(4)</sup>

Corneal edema is a clinical condition featured by increased anteroposterior corneal thickness or diameter.<sup>(5,6)</sup> The main factors taken into account in corneal edema etiology are endothelial dysfunction and Descemet membrane abnormalities. Bullous keratopathy is featured by stromal corneal edema, with epithelial and subepithelial bubbles, secondary to endothelial dysfunction.<sup>(7)</sup> The main etiologies of bullous keratopathy are the following: trauma after cataract surgery, trabeculectomy or secondary implantation of intraocular lenses, anterior chamber tumors, acute glaucoma, herpetic endotheliitis, and Fuchs endothelial dystrophy.<sup>(7-9)</sup> Fuchs dystrophy is the most common cornea dystrophy, which is slowly progressive, bilateral and usually asymmetric.<sup>(10)</sup> Such dystrophy starts to be clinically perceived in the fourth or fifth decade of life; it is a contraindication to refractive surgery and cataract surgery since surgical manipulation can lead to greater endothelial cell losses and, consequently, worsen the disease.<sup>(11)</sup> Electron microscopy shows multilamellar configuration with the accumulation of fibrillar material containing type I, III, and V collagen.<sup>(12-14)</sup> According to Ximenes et al., corneal edema can be caused by Descemet membrane detachment.<sup>(15)</sup>

Descriptive study of the histopathological changes found in the Descemet membrane of a patient subjected to penetrating keratoplasty secondary to bullous keratopathy. Ethics Committee approved the current project (CAAE 14961719.9.0000.5049).

## RESULTS

Women, aged 59 years, high blood pressure, diabetes (type 2), referred to the ophthalmologic outpatient clinic of Fortaleza General Hospital complaining of low visual acuity in both eyes (BE) in May 2014. Medical record presented phacoemulsification with intraocular lens implant in June 2013 in the right eye (RE) and in October 2013 in the left eye (LE), both performed

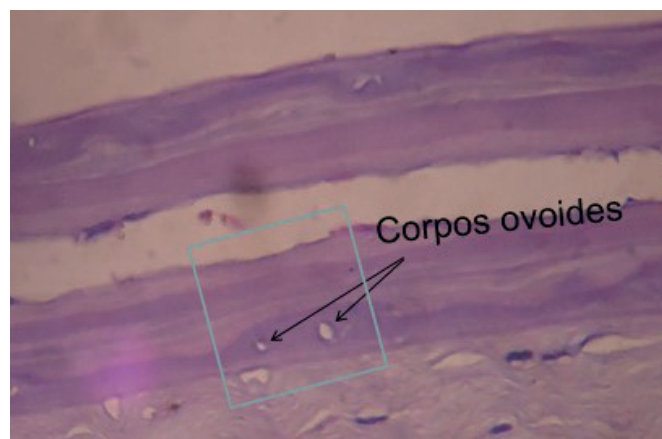
in another clinic. Best-corrected visual acuity (BCVA) was hand motion (RE) and counting finger at 30cm (LE). Biomicroscopy in both eyes showed corneal opacification, with edema 3+/4+ and epithelial microbubbles almost over the entire corneal surface; it showed dots in Fluorescein staining, without any other changes. Ocular ultrasound was performed due to the impossibility of visualizing the fundus, which was normal in BE. Treatment with polydimethylsiloxane eye drops was started in BE and the patient was referred to penetrating corneal transplantation (RE on April 2015 and LE in April 2016), which evolved with good results (BCVA RE 20/40 and LE 20/30). Patient RE cornea was fixated in 10% neutral formaldehyde, macroscopy was performed. It was taken to paraffin; 2.5µm thick cuts were made and stained with Hematoxylin-Eosin (HE), Masson trichrome, PAS (periodic acid-Schiff) and methenamine silver (Grocott-Gomori method). The LE cornea was not sent for assessment in the current research's Eye Bank.

RE Macroscopy: Corneal tissue 7 mm in diameter

RE Microscopy: Corneal epithelium showed microbubbles on its surface and the basal layer had swollen and vacuolated cells. Marginal corneal edema was identified due to Descemet membrane detachment, similar to the findings made by Ximenes et al.<sup>(15)</sup> Bowman layer showed thinned areas with darker color shades when they were stained with HE: numerous folds and breaks, and little stained by Masson coloration and PAS. There were some small and dispersed areas with very mild edema in the stroma. Descemet membrane was compact on one side and showed superposition of layers, without having very explicit tonal differences, which became significantly evident after it. Encapsulated ovoid formations (Figure 1) were more often observed in areas with greater division of layers. The capsules of these formations did not stain in Grocott-Gomori (GMS) stain. In figure 2 we see the multiplicity of layers. Being more evident in 2B, due to the magnification of 100x.

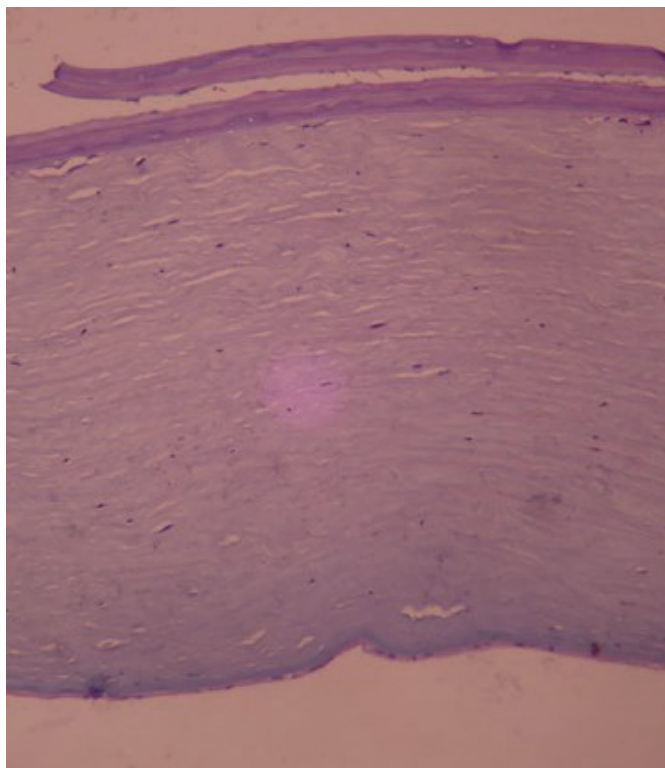
## DISCUSSION

Descemet membrane detachment is not a frequent complication in the postoperative period of cataract surgery, but it causes intense visual loss when it reaches the visual axis and, when edema persists for a long time. Bullous keratopathy is an uncomfortable occurrence that impairs patients' quality of life.<sup>(13)</sup>

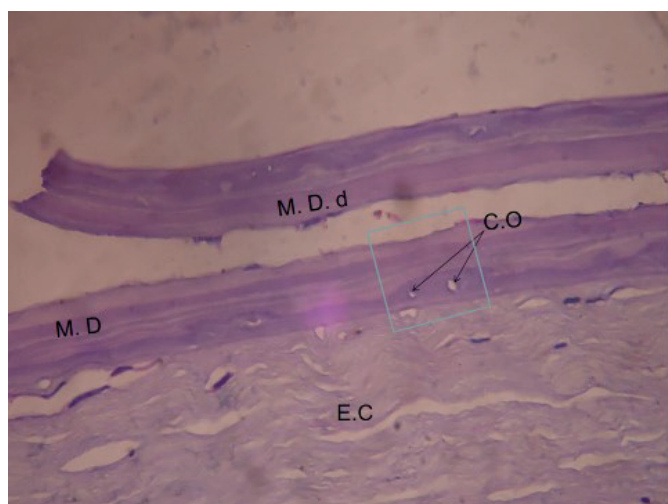


MD (Descemet membrane); MDd (detached Descemet membrane); CO- Ovoid bodies; EC- corneal Stroma.

Figure 1: RE - Ovoid bodies are real structures rather than fungus spores (negative GMS color), these bodies can produce extra layers.



**Figure 2A:** RE – Photomicrograph of the left (HE; original magnification - 50x) corneal region with evident multiplicity Descemet membrane layers showing edema absence.



**Figure 2B:** RE – Photomicrograph on the right (HE; original magnification - 100x) showing how the multiple layers have different shapes and thickness.

Literature is limited to the etiopathogenesis of bullous keratopathy and corneal edema to the endothelium factor or, to a lesser extent, only to the absence of Descemet membrane integrity.

The study “The role of descemet membrane in the corneal edema pathogenesis after anterior segment surgery” reported that changes in such a membrane can be related to endothelial dysfunction in the pathogenesis of bullous keratopathy after cataract surgery.<sup>(8)</sup>

Descemet membrane detachment is a frequent histopathological finding in post-surgical corneal edema; it must be seen as important factor in its pathogenesis. Such a change must be

investigated thoroughly at the postoperative time in order to be properly diagnosed and to receive early treatment to possibly avoid the need of keratoplasty.<sup>(8)</sup> The presence of ovoid bodies, probably involved in the production of these supernumerary layers, was the main change found in the current study. Thus, it is necessary paying attention to the etiology of corneal edema by correlating histopathological findings (such as the multiple divisions of Descemet membrane) to clinical manifestations.

Previous research have demonstrated the importance of Descemet membrane to the etiology of corneal edema with changes in integrity prevalence, be it in the form of rupture, isolated detachment or of detachment associated with rupture. Endothelial changes were frequently associated with Descemet membrane integrity absence.<sup>(8)</sup> It is important highlighting that the embryological evolution of Descemet membrane extends to the postnatal period. It is often possible distinguishing the pre from postnatal layers of the membrane in histological cuts. The several layers detected in the current study raise the issue about the extension of the postnatal period. The presence of ovoid bodies with morphology resembling fungal spores led to the attempt of achieving differential diagnosis. Negativity for fungi makes it legitimate to ask whether they were not the ones forming these late layers. Such a hypothesis come with reservations, because this statement can have serious implications from the biological viewpoint, since this assumption cannot be based on a single report. Further research is necessary to assess whether it would be the prolonged extension of the membrane formation process or the reappearance of this process after the proper time. Both possibilities present dystrophic form, which could help better understanding the embryological evolution of the membrane’s structure.

## CONCLUSION

It was not possible distinguishing the fetal layer from the acquired layer in the herein reported case. Therefore, it evidences the importance of the current case report, since the literature on this subject is scarce. The DUA’s layer was not well-defined in the current study, because optical microscopy was the used examination method and, in some cases, it is easily individualized. The functional character of the DUA’s layer could be further defined, so it could be included in textbooks. This structure did not have any participation in the assessed case, since, based on the figures, changes were only observed in the Descemet membrane and they were different from the neighboring structures.

Research on collagen was not carried out, because there were not enough resources in the Eye Bank to perform histochemistry, immunohistochemistry, or electron microscopy. The current publication allows other researchers to value histopathological findings by describing them through research carried out in the laboratories presenting more resources available. After all, according to the French epidemiologist Michel Foucault (1926-1984): we only see in the clinic what we know. Many researchers will be able to warn about the existence of the herein described pathological condition.

## REFERENCES

1. Koudouna E, Okumura N, Okazaki Y, Nakano S, Inoue R, Fullwood NJ, et al. Immune cells on the corneal endothelium of na allogeneic corneal transplatation rabbit model. *Invest Ophthalmol Vis Sci.* 2017;58(1):242-51.

2. Costa DC, Kara-José N. Rejeição de transplante de córnea. *Rev Bras Oftalmol.* 2008;67(5):255-63.
3. Junqueira L, Carneiro J. *Basic histology.* New York: McGraw-Hill Medical; 2005.
4. Dua HS, Faraj LA, Said DG, Gray T, Lowe J. Human corneal anatomy redefined: a novel pre-Descemet's layer (Dua's layer). *Ophthalmology.* 2013;120(9):1778-85.
5. Alomar TS, Al-Aqaba M, Gray T, Lowe J, Dua HS. Histological and confocal microscopy changes in chronic corneal edema: implications for endothelial transplantation. *Invest Ophthalmol Vis Sci.* 2011;52(11):8193-207.
6. Goldman JN, Kuwabara T. Histopathology of corneal edema. *Int Ophthalmol Clin.* 1968;8(3):561-79.
7. Domingues GE, Mauro C, Fabiana P, Gomes JÁ, Farias Charles Costa de. Ceratopatia bolhosa: etiopatogênese e tratamento. *Arq Bras Oftalmol.* 2008;71(6):61-4.
8. Ljubimov AV, Atilano SR, Garner MH, Maguen E, Nesburn AB, Kenney MC. Extracellular matrix and Na<sup>+</sup>,K<sup>+</sup>-ATPase in human corneas following cataract surgery: comparison with bullous keratopathy and Fuchs' dystrophy corneas. *Cornea.* 2002;21(1):74-80.
9. Lucena AR, Lucena DR, Macedo EL, Ferreira JL, de Lucena AR. Uso de C3F8 no descolamento da membrana de Descemet pós-facectomia. *Arq Bras Oftalmol.* 2006;69(3):339-43.
10. Fuchs E. Dystrophia epithelialis corneae. *Graefes Arch Clin Exp Ophthalmol.* 1910;76(3):478-508.
11. Doors M, Berendschot TT, Touwslager W, Webers CA, Nuijts RM. Phacopower modulation and the risk for postoperative corneal decompensation: a randomized clinical trial. *JAMA Ophthalmol.* 2013;131(11):1443-50.
12. Ljubimov AV, Burgeson RE, Butkowsky RJ, Couchman JR, Wu RR, Ninomiya Y, et al. Extracellular matrix alterations in human corneas with bullous keratopathy. *Invest Ophthalmol Vis Sci.* 1996;37(6):997-1007.
13. Ljubimov AV, Burgeson RE, Butkowsky RJ, Michael AF, Sun TT, Kenney MC. Human corneal basement membrane heterogeneity: topographical differences in the expression of type IV collagen and laminin isoforms. *Lab Invest.* 1995;72(4):461-73.
14. Waring GO 3rd. Posterior collagenous layer of the cornea. Ultrastructural classification of abnormal collagenous tissue posterior to Descemet's membrane in 30 cases. *Arch Ophthalmol.* 1982;100(1):122-34.
15. Ximenes KF, Silva JV, Vasconcelos KFX, Monte FQ. O papel da membrana de Descemet na patogenia do edema corneano após cirurgia de segmento anterior. *Rev Bras Oftalmol.* 2014;73(5):262-8.

---

**Corresponding Author**

Samuel Montenegro Pereira

E-mail: Samuel.ofthalmontenegro@gmail.com