

# Gemelarity-based diagnosis for subclinical keratoconus

## *Diagnóstico baseado em gemelaridade para ceratocone subclínico*

Cristiane Samara Botteon<sup>1</sup> <https://orcid.org/0000-0001-6626-1674>  
Jacques Ramos Houly<sup>1</sup> <https://orcid.org/0000-0001-5496-6095>  
Giuliano de Oliveira Freitas<sup>2</sup> <https://orcid.org/0000-0002-9348-1856>  
Joel Edmur Boteon<sup>3,4</sup> <https://orcid.org/0000-0002-8498-2560>  
Milton Ruiz Alves<sup>3</sup> <https://orcid.org/0000-0001-6759-5289>

### ABSTRACT

*We report a case of two twins for whom advanced keratoconus is present in one of the siblings and no clear sign of the disease could be found for the other.*

**Keywords:** Keratoconus; Twins; Corneal diseases; Refractive surgery procedures; Tomography

### RESUMO

Relatamos um caso de dois gêmeos em que o ceratocone avançado está presente em um dos irmãos e nenhum sinal da doença foi encontrado no outro.

**Descritores:** Ceratocone; Gêmeos; Doenças da Córnea; Procedimentos Cirúrgicos Refrativos; Tomografia

<sup>1</sup>Fundação Hilton Rocha, Belo Horizonte, MG, Brazil.

<sup>2</sup>FOCCO – Catarata e Cirurgia Refrativa, Uberlândia, MG, Brazil.

<sup>3</sup>Federal Universidade de Minas Gerais, Belo Horizonte, MG, Brazil.

<sup>4</sup>Universidade de São Paulo, São Paulo, SP, Brazil.

**Instituição:** FOCCO - Catarata e Cirurgia Refrativa, Uberlândia, MG, Brazil.

**The author declare no conflict of interest**

Received for publication 17/2/2019 - Accepted for publication 6/7/2020.

**INTRODUCTION**

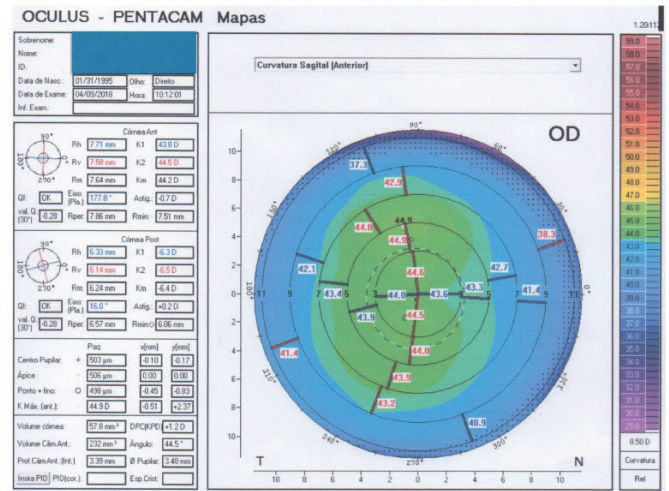
**K**eratoconus (Kc) is a bilateral, asymmetric and often progressive corneal ectasia, characterized by thinning and protrusion of the cornea.<sup>(1)</sup> Its etiopathogenesis remains uncertain.<sup>(2)</sup> Studies on Kc involving twins have investigated the involvement of the genetic and environmental components of the disease. There are a large number of family cases in the literature, and inheritance related to sex, autosomal dominant, recessive, and multifactorial have been suggested.<sup>(1)</sup> The diagnosis of subclinical forms among refractive surgery candidates should be one of the main concerns of the surgeon, since the weakening of the biomechanical properties of the cornea, associated with the keratorefractive procedures, can aggravate the ectasia, leading to low postoperative visual acuity.<sup>(3,4)</sup> The present report addresses the case of two twins for whom routine consultation and corneal tomography have shown unequivocal diagnosis of Kc for one sibling, meanwhile virtually no findings suggestive of the disease have been found for the other. Both had no history of pruritus or allergic eye disease.

**Case report**

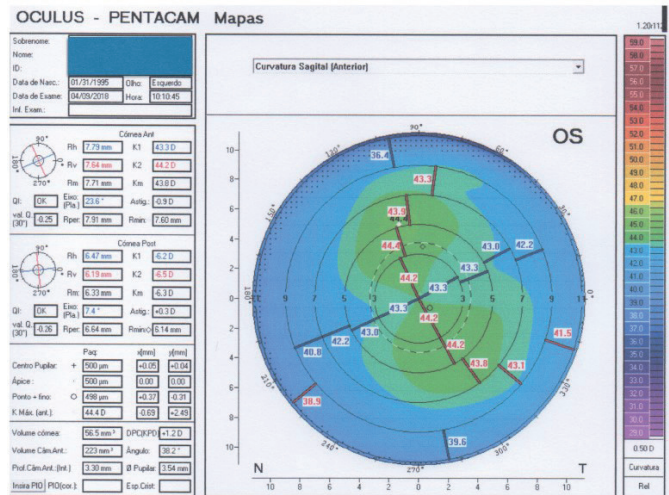
A 23-year-old male patient has sought ophthalmologic care aiming for refractive surgery. His personal or family histories were unremarkable for any known eye, or systemic diseases at that time. His best corrected distance visual acuity has been 20/20 for both eyes and his cycloplegic refraction was -4.50 sphere -0.25-cylinder x 175° for the right eye (OD), and -4.75 sphere -0.50 cylinder x 40° for the left eye (OS), similar to the patient's glasses, prescribed a year earlier elsewhere. No remarkable findings were found on biomicroscopy, or fundus examinations.

Corneal tomography (Pentacam - Oculus, Wetzlar, Germany) revealed a simulated keratometry of 43.8 diopters (D) @ 177.8°/44.5 for OD and 43.3 D @ 23.6°/44.2 for OS (Figure 1) and also maximum keratometric reading of 44.9 D for OD and 44.4 D for OS. Both anterior and posterior elevation maps have shown values within normal range: central elevation lower than +12 µm and +17 µm, respectively. Topometric indices have showed values lower than 2.5 standard deviations of a normal population. The pachymetric analysis charts showed a distribution within two standard deviations of the population mean (Figure 2). The pachymetric measurement of the thinnest point was 498 µm for both. Astigmatism vector analysis<sup>(5,6)</sup> for OD was 0.10 D for the astigmatism vector (Astigm) and the blurring vector (Blur) 6.40 D, and for OS Astigm was 0.15 D and the Blur of 6.35 D (Reference values: Astigm <0.23 D, Blur <6.45). Such findings associated with the qualitative analysis of the anterior keratometric, pachymetric and anterior and posterior elevation maps, and even the various topometric indices presented, were not suggestive of Kc.

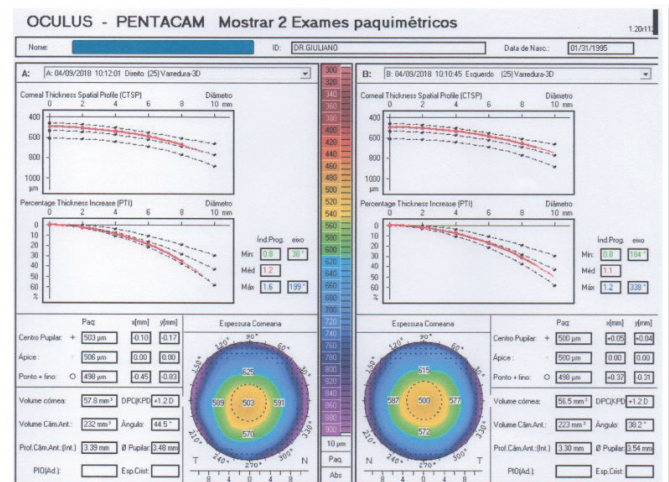
His twin brother, who also sought routine ophthalmic evaluation, has complained of progressive worsening in corrected visual acuity for OS during the last six months. His distance corrected visual acuity was 20/20 in the OD with cycloplegic refraction of -2.25 spherical D. His distance visual acuity for OS, on the other hand, was lower than 20/200; it was impossible to measure its cycloplegic refraction. Evident Vogt's striae were observed in OS. No fundoscopic changes were found. Corneal tomography and anterior segment obtained the following results: maximum keratometry of 47.7 D for OD and 60.8 D for OS; thinnest pachymetric measurement of 465 µm for OD and of 431 µm for OS (Figure 3). Qualitative analysis of keratometric and



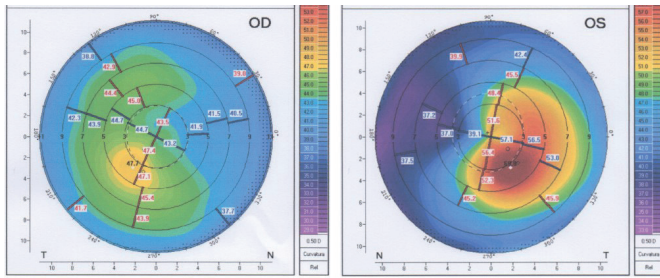
**Figure 1A:** Sagittal map of the OD



**Figure 1 B:** Anterior sagittal map of OS



**Figure 2:** Pachymetric exams of OD (on the left) and OS (on the right).



**Figure 3:** Map of OD (in the left) and OS (on the right)

paquimetric maps and their indexes were unambiguous about the diagnosis of Kc to this patient: grade I for OD and grade III for OS (Amsler-Krumeich classification).<sup>(7)</sup>

## DISCUSSION

Laser keratorefractive procedures promote biomechanical weakening of the cornea, which can lead to progressive stromal thinning, and consequently to increased curvature and irregular astigmatism. Such a complication occurs more frequently within corneas that present preexisting biomechanical fragility, such as in keratoconus carriers, even in the subclinical form.

Although most of the cases of Kc occur sporadically, there are a large number of familial cases in the literature, with the possibility of Kc among first-degree relatives being 27.9% higher.<sup>(8)</sup> There are reports of inheritance related to sex, autosomal dominant and recessive, in addition to possible multifactorial inheritance.<sup>(1)</sup> In addition to the genetic component, the relative contribution of environmental and behavioral factors is proposed.<sup>(2)</sup> Studies involving Kc and gemelarity may contribute to clarification about the participation of these factors in the development of the disease, but such studies are still scarce in the literature.<sup>(9)</sup> A study involving 18 pairs of twins, being 13 monozygotic and 5 dizygotic, showed that all monozygotic (100%) and 4 of 5 dizygotic (80%) were concordant for occurrence of Kc, but with differences in age and onset of the disease. Phenotypic variability among monozygotics can be explained by possible environmental differences, epigenetic mechanisms or other factors that have not yet been fully elucidated.<sup>(2)</sup>

Preoperative evaluation among candidates for keratorefractive procedures attempts to identify corneas that are more susceptible to the development of postoperative ectasia.<sup>(4,7)</sup> The topography of the anterior surface of the cornea, traditionally evaluated by based on the reflection of Placid disk, has been complemented, or even replaced, by corneal tomography based on the Scheimpflug system.<sup>(2)</sup> Equipments such as Pentacam (Oculus, Wetzlar, Germany), Galilei (Ziemer, Biel, Switzerland), or the Sirius (Costruzione Strumentaria Ophthalmica, Florence, Italy) are, at least theoretically, able to perform measurements of anterior and posterior corneal surfaces, as well as elevation maps, pachymetric maps, as well as calculating various topometric indices that aim to raise sensitivity and specificity for subclinical Kc forms.<sup>(7,10)</sup> Equipment such as the Ocular Response Analyzer (Reichert Buffalo, NY, USA), or Corvis ST (Oculus, Wetzlar, Germany) offer additional information on corneal biomechanics, however, they do not yet have widespread use.<sup>(4)</sup> Despite the advances in propaedeutics, sometimes the diagnosis of subclinical forms of Kc remains difficult to perform,<sup>(11)</sup> the literature is rich in examples, sometimes conflicting, of indexes

or analyzes that claim better diagnostic capacity: Hashemi et al. concluded that the Belin Ambrosio Enhanced Display (BAD-D), the surface variation index (ISV) and the vertical asymmetry index (IVA) are strong indicators for subclinical keratoconus;<sup>(12)</sup> Muftuoglu et al. have reached similar conclusions;<sup>(13)</sup> Shetty et al. demonstrated high sensitivity (100%) to differentiate subclinical keratoconus through ISV and the highest asymmetry index (IHA)<sup>(7)</sup>; Shajari et al. suggested the use of IVA and the index of greater decentralization (IHD) to evaluate the initial stages of the disease. More recently, the tomographic and biomechanical index (TBI) that combines data from Pentacam and Corvis ST, showed greater precision to improve the detection of subclinical ectasia.<sup>(14)</sup>

Regarding the patient with Kc grade III of the report, intrastromal ring segment implant for OS and crosslinking of corneal collagen for OD were indicated. Both procedures were rejected by the patient who preferred the use of semi-scleral lenses in the most affected eye and visual correction by means of glasses for the least affected. For the other sibling, classified as having suspected cornea, the exams showed subtle changes, which, according to the evaluation of many refractive surgeons, would certainly not contraindicate the performance of photorefractive keratectomy. However, considering the reality that is required in the day-to-day practice of the clinics, in which there is no adequate propaedeutic, as well as the epidemiology that suggests that the concordance varying between 30 and 100% between twins (if possible monozygosis), we have chosen the prescription of optical correction through glasses, not indicating laser vision correction. Both patients have been advised to perform close follow-ups visits every six months, until around the age of 30, for clinical evaluation and complementary propaedeutics available. In addition to the inherent limitation to the type of study, there is the question of the relative subjectivity of the diagnosis and conduct for the twin with the suspected cornea. Nevertheless, the report reinforces the need for complementary tests to be interpreted in the light of the patient's clinic, of which family history is a fundamental part.

## REFERENCES

- Schmitt-Bernard C, Schneider CD, Blanc D, Arnaud B. Keratographic analysis of a family with keratoconus in identical twins. *J Cataract Refract Surg.* 2000;26(12):1830-2.
- Tuft SJ, Hassan H, George S, Frazer DG, Willoughby CE, Liskova P. Keratoconus in 18 pairs of twins. *Acta Ophthalmol.* 2012;90(6):e482-6.
- Vinciguerra R, Ambrósio R Jr, Roberts CJ, Azzolini C, Vinciguerra P. Biomechanical characterization of subclinical keratoconus without topographic or tomographic abnormalities. *J Refract Surg.* 2017;33(6):399-407.
- Lopes BT, Ramos IC, Dawson DG, Belin MW, Ambrósio R Jr. Detection of ectatic corneal diseases based on pentacam. *Z Med Phys.* 2016;26(2):136-42.
- Freitas GO, Ambrósio R Jr, Ramos I, Lopes B, Valbon BF, Botteon C, et al. Astigmatic vector analysis of posterior corneal surface: a comparison among healthy, forme fruste and overt keratonic corneas. *Am J Ophthalmol.* 2016;167(5):65-71.
- Thibos LN, Horner D. Power vector analysis of the optical outcome of refractive surgery. *J Cataract Refract Surg.* 2001;27(1):80-5.
- Shetty R, Rao H, Khamar P, Sainani K, Vunnava K, Jayadev C, et al. Keratoconus screening indices and their Diagnostic ability to distinguish normal from ectatic corneas. *Am J Ophthalmol.* 2017;181(9):140-8.



8. Shaag AG MM, Shneor E, Liu Y. The genetic and environmental factors for keratoconus. *Biomed Res Int*. 2015;2015:795738.
9. G M. Non-identical monozygotic twins, intermediate twin types, zygosity testing, and the non-random nature of monozygotic twinning: a review. *Am J Med Genet C Semin Med Genet*. 2009;2(15):110–27.
10. Kosekahya P, Koc M, Caglayan M, Kiziltoprak H, Atilgan CU, Yilmazbas P. Repeatability and reliability of ectasia display and topometric indices with the Scheimpflug system in normal and keratoconic eyes. *J Cataract Refract Surg*. 2018;44(1):63–70.
11. Shajari M, Jaffary I, Herrmann K, Grunwald C, Steinwender G, Mayer WJ, et al. Early tomographic changes in the eyes of patients with keratoconus. *J Refract Surg*. 2018;34(4):254–9.
12. Hashemi H, Beiranvand A, Yekta A, Maleki A, Yazdani N, Khabzkhooob M. Pentacam top indices for diagnosing subclinical and definite keratoconus. *J Curr Ophthalmol*. 2016;28(1):21–6.
13. Muftuoglu O, Ayar O, Hurmeric V, Orucoglu F, Kılıc I. Comparison of multimetric D index with keratometric, pachymetric, and posterior elevation parameters in diagnosing subclinical keratoconus in fellow eyes of asymmetric keratoconus patients. *J Cataract Refract Surg*. 2015;41(3):557–65.
14. Ambrósio R Jr, Lopes BT, Faria-Correia F, Salomão MQ, Bühren J, Roberts CJ, et al. Integration of Scheimpflug-based corneal tomography and biomechanical assessments for enhancing ectasia detection. *J Refract Surg*. 2017;33(7):434–43.

---

**Corresponding author**

Cristiane Samara Botteon

Av. Professor Cândido Holanda, 30/ 703. Belo Horizonte, MG, Brazil. Zip code: 30350340.

E-mail: cristianebotteon@yahoo.com.br