







Esotropia, nystagmus and optic disk staphyloma in Donnai-Barrow syndrome

Esotropia, nistagmo e estafiloma de disco óptico na síndrome de Donnai-Barrow

Tamires Able Carmona¹ , Marcella Polisuk¹ , Larissa de Sá Barreto¹ , Daniele Bravim Longo¹ , Renato Sztern Queiroz¹ , Rachel Simões Cavalcanti¹ 

¹ Hospital Federal de Bonsucesso, Rio de Janeiro, RJ, Brazil.

Carmona TA, Polisuk M, Barreto LS, Longo DB, Queiroz RS, Cavalcanti RS. Esotropia, nystagmus and optic disk staphyloma in Donnai-Barrow syndrome. Rev Bras Oftalmol. 2023;82:e0014.

How to cite:

doi:

<https://doi.org/10.37039/1982.8551.20230014>

Keywords:

Nistagmus; Staphyloma;
Esotropia; Donnai-Barrow
syndrome; Hypertelorism

Descritores:

Nistagmo; Estafiloma; Esotropia;
Síndrome de Donnai-Barrow;
Hipertelorismo

Received on:
Sept 01, 2022

Accepted on:
Dec 23, 2022

Corresponding author:

Tamires Able Carmona
Hospital Federal de Bonsucesso
Avenida Londres, 616, building 5, 5th floor
– Bonsucesso
CEP: 21041-030 – Rio de Janeiro, RJ, Brazil
E-mail: tamirescarmona@gmail.com

Institution:

Hospital Federal de Bonsucesso, Rio de
Janeiro, RJ, Brazil.

Conflict of interest:

no conflict of interest.

Financial support:

no financial support for this work.



Copyright ©2023

ABSTRACT

A 12-year-old boy with Donnai-Barrow syndrome diagnosed intra-uterus presented esotropia, high myopia, nystagmus, and optic disk staphyloma in an ophthalmologic examination. The patient had associated Fanconi syndrome and sensorineural hearing loss as well as facial manifestations as hypertelorism, downward slanting of palpebral fissures and low ear implantation. Magnetic resonance imaging revealed agenesis of the corpus callosum. To our knowledge, this is the first reported case associated with esotropia, nystagmus, and optic disk staphyloma.

RESUMO

Paciente do sexo masculino, 12 anos, com diagnóstico intrauterino de síndrome de Donnai-Barrow, apresentava ao exame oftalmológico esotropia, alta miopia, nistagmo e estafiloma de disco óptico. Associado ao quadro, apresentava síndrome de Fanconi e perda auditiva neurossensorial, além de alterações faciais, como hipertelorismo, inclinação inferior das fissuras palpebrais e implantação baixa das orelhas. Ressonância magnética revelou agenesia de corpo caloso. Ao nosso conhecimento, este é o primeiro caso relatado associando esotropia, nistagmo e estafiloma de disco óptico.

INTRODUCTION

The first case ever reported of Donnai-Barrow Syndrome (DBS), or Facio-acoustico-renal syndrome, was in 1972⁽¹⁾ and only 35 years later, its molecular pathogenesis was discovered. It happens due to mutations in LRP2 genes, which is responsible for coding a protein called megalin, a multiligand uptake receptor that regulates levels of diverse circulating compounds.⁽²⁾

The DBS is associated with ocular abnormalities, deep sensorineural hearing loss, facial dysmorphism, congenital diaphragmatic hernia, agenesis of corpus callosum, and development delay.⁽¹⁾

In this paper, we report a case of a 12-year-old patient with DBS, esotropia, and Fanconi syndrome.

CASE REPORT

A 12-year-old boy presented to ophthalmology consultation with low vision acuity since birth, already diagnosed with DBS whilst still intra-uterus through amniocentesis and later on had magnetic resonance imaging revealing agenesis of the corpus callosum. He is being followed up by the Pediatric Nephrology Department for proximal renal tubular acidosis with Fanconi syndrome. He was also diagnosed with diaphragmatic hernia and unilateral cryptorchidism, both already surgically corrected, and bilateral severe sensorineural hearing loss, with no cochlear implants. Systemic examination revealed hypertelorism, downward slanting of palpebral fissures, and low implantation of both ears. On examination, patient presented horizontal nystagmus bilaterally, with high frequency and low amplitude, without null point. Visual acuity with best correction was less than 20/400 on each eye, using the Snellen chart. The cycloplegic retinoscopy revealed -28.00D spherical and 1.00D cylindrical on the right eye and -28.50D spherical and 1.50 cylindrical on the left eye. Ocular mobility presented hypofunction of lateral rectus and superior oblique muscles bilaterally, with anisotropy in letter "V". Esotropia of 10 diopters in primary ocular position and 30 diopters in infraversion position was shown (Figure 1). Fundus examination showed scleral exposure, applied retina, and optic disk staphyloma bilaterally. Contact immersion A-ultrasound presented axial length of 32.7mm on the right eye and 33.91mm on the left eye, while B-ultrasound detected vitreous degeneration in both eyes. Anterior chamber diameter measured by ultrasonic biometry of the right eye was 2.65mm and 2.23mm on the left eye (Figure 2). Goldmann Tonometry was 12mmHg on the right eye and 14mmHg on the left eye. Anterior segment evaluation showed no alterations. After 4 months, the patient developed spontaneous

superior and temporal retinal detachment in the left eye (Figures 3 and 4).

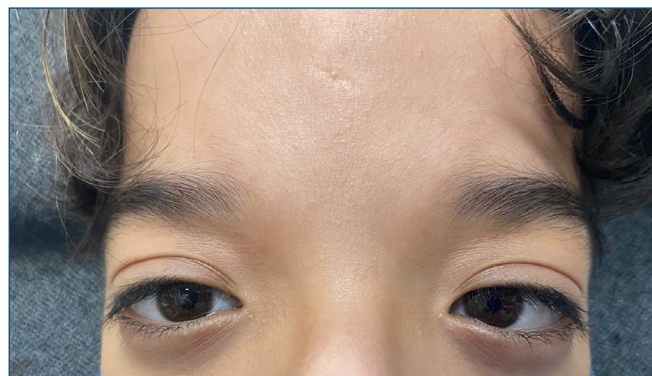

Figure 1. Patient with DBS showing hypertelorism and esotropia

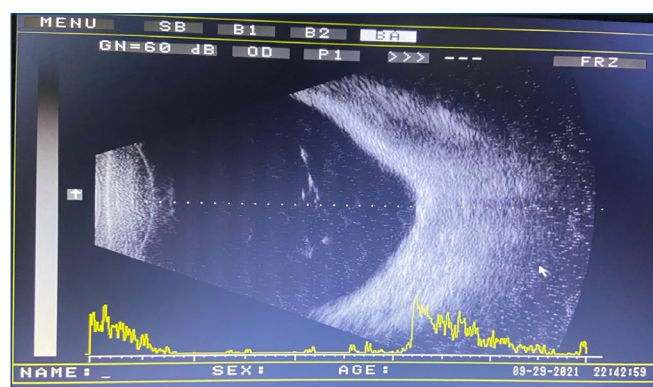


Figure 2. B-mode ultrasound of left eye

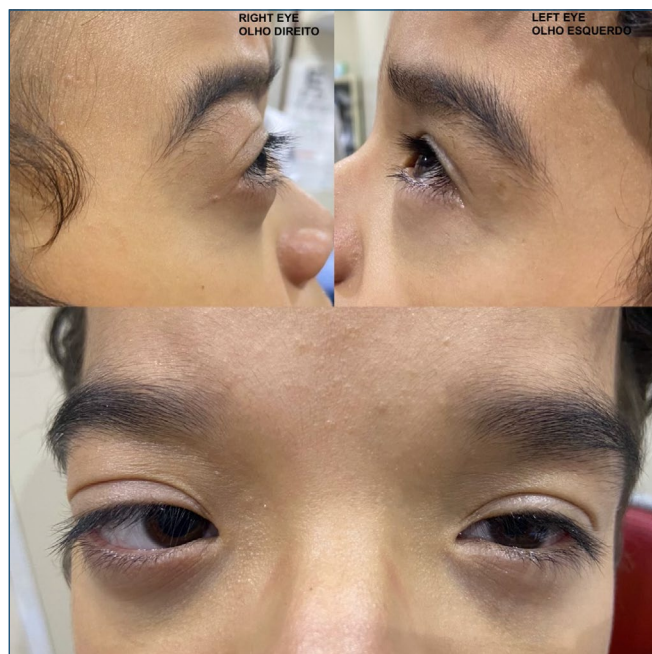

Figure 3. Patient with DBS and retinal detachment presenting enophthalmos of left eye

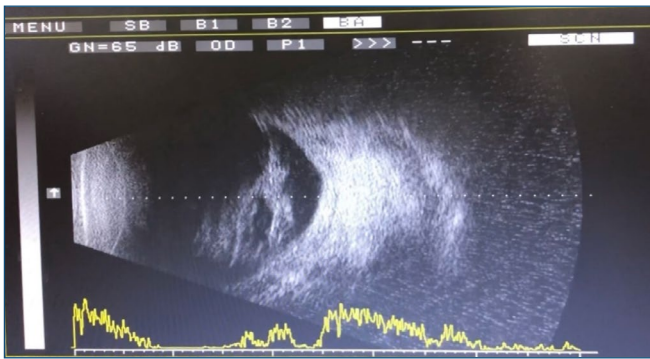


Figure 4. B-mode ultrasound of left eye showing retinal detachment

DISCUSSION

Facio-acoustico-renal syndrome, also known as Donnai-Barrow syndrome, was first reported in 1972, by Holmes and Schepens, in two siblings presenting both eyes and craniofacial abnormalities, telecanthus and sensorineural deafness.⁽¹⁾ The disorder is a result from mutation in the *LRP2* gene, which encodes a protein called megalin, a multiligand endocytic receptor.⁽²⁾ This receptor is found in the proximal convoluted tubules, neural tube, the epididymis, and the retinal pigmented endothelium, which justifies the multiple phenotype and function anomalies. Megalin is also critical to reuptake multiple ligands, including vitamin-D binding proteins, retinol binding proteins, lipoproteins and sterols. The defect of *LRP2*/megalin clearance pathway in the kidney may cause proximal renal tubular acidosis type 2 (Fanconi's syndrome), with low-molecular weight protein loss.⁽³⁾ Different *LRP2* gene mutations have been discovered, which may explain the gravity variation of the syndrome's clinical features.⁽⁴⁻⁶⁾

A review study showed that over 90% of the patients with DBS showed congenital anomalies such as hypertelorism, partial or complete agenesis of the corpus callosum, enlarged anterior fontanelle, and characteristic facial features; also, over 90% of the cases showed functional anomalies, as proteinuria, high myopia, sensorineural hearing loss, development delay, and other anomalies found in about 50% of the patients, as congenital diaphragmatic hernia and omphalocele/umbilical hernia. Additional features such as coloboma and macrocephaly were also reported.⁽⁷⁾ The DBS diagnosis consists of the aforementioned characteristic clinical features and a distinctive pattern of low-molecular weight proteinuria.⁽⁸⁾

Ocular manifestations of DBS reported include nystagmus, staphyloma optic disk, esotropia, hypertelorism, down-slanting palpebral fissures, high myopia (up to -11.00D), enlarged globes, prominent eyes, iris coloboma,

iris hypoplasia, cataract, choroidal atrophy, retinal detachment, strabismus, nystagmus, and optic nerve hypoplasia.⁽⁸⁻¹⁰⁾ These patients with congenital high myopia have significant risk of retinal detachment, and prophylactic barrier photocoagulation may be considered.⁽⁸⁾ To our knowledge, only a few reports have been made in ophthalmologic literature^(8,9) and, aside from hypertelorism and high myopia, which are described in all papers reporting DBS, the incidence of other ocular findings is unknown.

An early ophthalmologic diagnosis is important, for the high risk of retinal detachment, refractive errors and amblyopia (in one or both eyes). To promote the best visual development possible for the patient, early cycloplegic refraction and prescription of glasses or contact lenses to correct any refraction error, and regular fundus examination, due myopic alterations, are mandatory. In cases of higher risk of retinal detachment, prophylactic barrier photocoagulation can be performed.⁽⁸⁾ However, as it is a rare syndrome, more ophthalmological studies should be considered in order to discover more ways to prevent retinal detachment. In this case, we report esotropia with nystagmus and staphyloma optic disk with DBS for the first time.

REFERENCES

1. Holmes LB, Schepens CL. Syndrome of ocular and facial anomalies, telecanthus, and deafness. *J Pediatr*. 1972;81(3):552-5.
2. Kantarci S, Al-Gazali L, Hill RS, Donnai D, Black GC, Bieth E, et al. Mutations in *LRP2*, which encodes the multiligand receptor megalin, cause Donnai-Barrow and facio-oculo-acoustico-renal syndromes. *Nat Genet*. 2007;39(8):957-9.
3. Flemming J, Marczenke M, Rudolph IM, Nielsen R, Storm T, Erik IC, et al. Induced pluripotent stem cell-based disease modeling identifies ligand-induced decay of megalin as a cause of Donnai-Barrow syndrome. *Kidney Int*. 2020;98(1):159-67. Erratum in: *Kidney Int*. 2021;100(2):482.
4. Willnow TE, Christ A. Endocytic receptor *LRP2*/megalin-of holoprosencephaly and renal Fanconi syndrome. *Pflugers Arch*. 2017;469(7-8):907-16.
5. Longoni M, Kantarci S, Donnai D, Pober BR. Donnai-Barrow Syndrome. 2008 Aug 28 [updated 2018 Nov 21]. In: Adam MP, Everman DB, Mirzaa GM, Pagon RA, Wallace SE, Bean LJH, et al., editors. *GeneReviews*. Seattle (WA): University of Washington, Seattle; 1993-2022.
6. Willnow TE, Christ A. Endocytic receptor *LRP2*/megalin-of holoprosencephaly and renal Fanconi syndrome. *Pflugers Arch*. 2017;469(7-8):907-16.
7. Pober BR, Longoni M, Noonan KM. A review of Donnai-Barrow and facio-oculo-acoustico-renal (DB/FOAR) syndrome: clinical features and differential diagnosis. *Birth Defects Res A Clin Mol Teratol*. 2009;85(1):76-81.
8. Chinta S, Gupta A, Sachdeva V, Kekunnaya R. Persistent pupillary membrane, strabismus, and optic nerve hypoplasia in Donnai-Barrow syndrome. *J AAPOS*. 2011;15(6):604-5.
9. Patel N, Hejkal T, Katz A, Margalit E. Ocular manifestations of Donnai-Barrow syndrome. *J Child Neurol*. 2007;22(4):462-4.
10. Khan AO, Ghazi NG. The distinct optic disk and peripapillary appearance in Donnai-Barrow syndrome. *Ophthalmic Genet*. 2018;39(3):321-4.