

Behavioral and histologic experimental model of facial nerve regeneration in rats

Andrei Borin¹, Ronaldo Nunes Toledo², Simone Damasceno de Faria³, José Ricardo Gurgel Testa⁴, Oswaldo Laércio Mendonça Cruz⁵

Keywords: histology, animal model, facial nerve, wistar rat, nerve regeneration.

Summary

To setup an experimental model is the first step to study neural regeneration. **Aim:** Setting up an experimental model on facial nerve regeneration. **Material and Methods:** Wistar rats with complete sectioning and suturing of the extratemporal facial nerve trunk; with a behavioral and histological analysis for 9 weeks. **Study Design:** Experimental prospective study. **Results:** Progressive clinical and histological recovery of the animals. **Conclusion:** Our method is acceptable to study facial nerve regeneration in rats.

¹ M.S. in Otorhinolaryngology at UNIFESP/EPM, Doctoral degree in progress.

² M.S. in Otorhinolaryngology at UNIFESP/EPM, Doctoral degree in progress.

³ M.S. in Otolaryngology at UNIFESP/EPM, M.D.

⁴ PhD in Otorhinolaryngology at UNIFESP/EPM, associate professor of otorhinolaryngology at UNIFESP/EPM.

⁵ Associate professor at FMUSP, affiliated professor at UNIFESP/EPM.

Department of Otorhinolaryngology and Head & Neck Surgery at the Federal University of São Paulo.

Mailing address: Andrei Borin - Rua Loefgreen 1587 apto. 152 V. Clementino São Paulo SP 04040-032.

Paper submitted to the ABORL-CCF SGP (Management Publications System) on May 2, 2006 and accepted for publication on June 20, 2006. cod. 1891.

INTRODUCTION

The facial nerve -either of the seventh pair of cranial nerves- plays an important role in various bodily functions. It is responsible for homolateral hemifacial motion and assists in the motion of neck muscles, in the efferent stapedius reflex, in outer ear sensitivity, in gustatory functions and in the autonomic control of exocrine glands. Injuries to the facial nerve pose marked impact on anyone's well-being, as cosmetic, functional, and psychological impairments ensue¹⁻³.

Publications in the medical literature on attempts to repair injured facial nerves date back to the 17th century⁴, but the first successful account happened only in 1927 by Bunne⁵. During World War II, as patients poured in from the battle fields, efforts were initiated to treat neural lesions. Published in 1942, 'Senior Consultant in Neurologic Surgery to the European Theater of Operations'⁶ argued in favor of early tensionless sutures to improve functional outcomes. However, recovery results for injured facial nerves remain controversial^{1,2,7,8}. Several papers have been published on the weight various factors bear on the recovery of lesioned facial nerves, encompassing surgical techniques², delivery of neurotrophic agents^{1,7,9} and even exposure to electromagnetic pulses¹⁰. All such studies have led to the development of experimental methods to analyze injured facial nerves.

This paper aims to set a reproducible experimental paradigm to analyze total facial nerve lesions that allows for the analysis of nerve regeneration along time and facilitates the implementation of future studies on the use of neurotrophic factors.

MATERIALS AND METHODS

The research project described in this paper was reviewed and approved by the Research Ethics Committee at UNIFESP/EPM under protocol # 0418/05.

Adult male Wistar rats with weight ranging between 200 and 300 grams were used in the study. They were kept in proper cages, under controlled environmental conditions and 12-hour darkness/light cycles, with free access to water and feed. The rats were divided into six groups and underwent facial nerve sectioning followed by suturing, slaughtering and histology exams at 1, 3, 5, 7 and 9 weeks after surgery. The 9-week group (9 SEM) followed the algorithm described below:

D0 D01 D07 D14 D21 D28 D35 D42 D49 D56 D63
 |_____|_____|_____|_____|_____|_____|_____|_____|_____|_____|
 Initial surgery behavior observation slaughter
 * Sectioning of nerve and suturing * nerve histology exams

Note: D01 (first day post-op), D07 (seventh day post-op), D14 (fourteenth day post-op)...

None of the other groups (0 SEM, 1 SEM, 3 SEM, 5 SEM and 7 SEM) were observed for behavior and were slaughtered as scheduled on D0, D7, D21, D35 and D49 respectively. On D0 all rats underwent surgery using a DF-Vasconcelos® M90 surgical microscope, as described below:

- 1) Intraperitoneal anesthesia with 2% xylazine chloridrate (0.5 ml/Kg of weight) and 10% ketamine chloridrate (0.9 ml/Kg of weight);
- 2) right-side retroauricular hair removal;
- 3) Vertical retroauricular incision encompassing skin, subcutaneous tissue, and the platysma;
- 4) blunt dissection and identification of the tendinous margin of the clavicle-trapezius muscle, the trunk and furcation of the right-side facial nerve and external jugular vein;
- 5) Total sectioning of the facial nerve with micro scissors approximately 3mm above its point of emergence (between the tendinous margin of the clavicle-trapezius muscle and the external jugular vein) and followed by immediate suture with 9-0 nylon wire;
- 6) Closure of skin and subcutaneous tissues by separate stitches using 4-0 nylon wire.

On the days set aside for clinical observation the rats were observed for spontaneous facial movement and motion of vibrissae, comparing the injured right side to the normal left side as rats went by exploring the grounds. Scores were assigned based on vibrissae position, frequency and range of motion as described on Figure 1.

Figure 1. Scoring scale for vibrissae movement observation.

| Score | Motion |
|-------|---|
| 0 | No motion |
| 1 | Minor trembling |
| 2 | Effective movement with posterior positioning, range of motion and frequency lower than the contralateral side. |
| 3 | Effective movement, with positioning similar to the contralateral one, however with lower range and frequency of motion |
| 4 | Effective movement with range and positioning similar to the contralateral, however with lower frequency |
| 5 | Effective movement, frequency and range of motion similar to the contralateral |

The rats' eye-closure capability was also assessed during clinical observation through stimulation by a burst of air produced by quickly pushing on the plunger of a 20-ml syringe pointing to each of the animals' eyeballs. No comparisons were made between injured (right) and normal (left) sides as the lateralized position of the rats' eyeballs does not allow for simultaneous bilateral stimulation. Scores were assigned based on observed eyelid closure as described in Figure 2.

Figure 2. Scoring scale for eye closure observation.

| Score | Motion |
|-------|---|
| 0 | No perceptible motion |
| 1 | Muscle contraction but no perceptible eye closure |
| 2 | 25% eye closure |
| 3 | 25-50% eye closure |
| 4 | 50-75% eye closure |
| 5 | 75-100% eye closure |

All rats were slaughtered on the days scheduled for their specific groups by the administration of a high dose of the same anesthetics used during initial surgery. The right-side facial nerves were once again dissected and the previous neural sutures located. The fragments immediately distal to the point of suture were removed for histologic examination. Nerve fragments were placed in individual vials with modified Karnovsky fixative solution (2.5% glutaraldehyde and 2% paraformaldehyde, buffered with 0.1M sodium cacodylate (pH 7.4) to be processed and histologically analyzed at CEME (Center for Electronic Microscopy) at UNIFESP/EPM, as follows: four consecutive baths in a buffer solution of sodium cacodylate (0.1M pH 7.4), being the two first baths at room temperature for 15 minutes; the third was done at 4° C for 12 hours; and the fourth at room temperature for 15 minutes. Post-fixation with 2% osmium tetroxide in buffer solution of sodium cacodylate (0.1 M pH 7.4) for one hour, followed by two quick successive baths (1 minute) in distilled water. Fragments were then dipped in aqueous solution of 0.5% uranyl acetate for 30 minutes, followed by two quick successive baths (1 minute) in distilled water. Dehydration followed, in the form of successive immersion baths in solutions with increasing ethanol contents: 70% for 30 minutes (once), 90% for 30 minutes (once) and 100% for 20 minutes (twice). Two consecutive immersion baths in propylene oxide for 20 minutes each. Injection into an Araldite 502® resin mix type: propylene oxide in concentrations of 1:3, 1:2 and 1:1 for 60 minutes each, agitated by rotation at room temperature. Placement into pure resin for four to five hours in vacuum. Transference to embedding molds horizontally oriented to allow cross-sectioning of the nerves followed by resin polymerization in oven at 60° C for 72 hours. The resulting blocks were trimmed and sectioned using a Leica Reichert Ultracuts® ultramicrotome. The blocks obtained after this preparation were trimmed and sectioned using an ultramicrotome equipped with glass blades, producing ultrafine 0.3µm cuts in thickness. Then the cuts were placed in glass slides and stained with 1% toluidine blue.

The cross sections were seen under a Nikon Optiphot II® light microscope coupled to a Leica Quantimet 500 QWIN® image analyzer system, having the images

digitalized by a Sony XC 003P® camera. We obtained images with a 40x magnification lens and total magnification of 860 x the digitalized image. These images were then printed on 10 x 15cm photographic paper for the histometric quantitative and qualitative analysis of neural regeneration by analyzing myelinated fibers.

For the qualitative analysis, the pictures were displayed sequentially according to the time between the lesion and the animal slaughtering, and the presence of myelinated fibers was appreciated, together with its relative diameter and its uniform distribution in the nerve.

For the quantitative analysis we prepared a 10 x 15cm "mask" on a transparent acetate sheet, in which we drew 18 1.5 x 1.5cm "windows", numbered from 1 to 18, uniformly distributed on 3 lines (6 "windows" per line). We used Figure 4, which will be shown in the results in order to carry out a photo assembling that will represent these "windows". We then, randomly selected 3 "windows" per line in order to count myelinated fibers, at a total of 9 "windows" per image. Such count followed the classical histometric method¹¹ that only considers as "valid" those elements present totally "within" the window area and the ones only partially inside, but were crossed by the upper and left corners. We disregarded those that were partially in, and were crossed by the lower and right corners. The counts of each one of these nine "windows" was added up, thus yielding the total count for each rat. During the counting process, if any of the "windows" was considered inadequate, either because it was not totally inserted within the neural area (encompassing sheath and/or adjacent tissues), or the fibers be diagonally cut, or still because of problems as to its color (homogeneous deposits of toluidine blue). The "window" at hand here is then replaced by the next one in line. In case this new "window" is already selected at the initial random choosing, the succeeding window was then chosen. In case it becomes necessary to replace Windows 6, 12 or 18 (last in the lines); we chose windows 1, 7 and 13 (first ones in the lines).

RESULTS

We used two animals in each study group, a total of 12 rats. The results from this behavioral observation are depicted on Table 1. The score obtained by each rat in relation to vibrissae movement and eye closure were added up and we used the average value from the animals from each group, depicted on Chart 1. In this one we may infer a temporal recovery in the animals along these nine weeks of clinical observation. Statistical analysis were not carried out, since we have a sample of only two animals per group; however, we see a clear trend towards clinical recovery, going from an average of 2 points in the 1SEM group, towards 7.5 points in the 9SEM group. A "trend line" was calculated and inserted in order to facilitate the perception of such fact.

Table 1 - Results of animal behavior observation.

| Vibrissae observation | | | | | | | | | | | |
|--|------|-----|-----|-----|-----|-----|-----|-----|-----|-----|-----|
| Group | rat | D01 | D07 | D14 | D21 | D28 | D35 | D42 | D49 | D56 | D63 |
| 1 SEM | I | 0 | 1 | | | | | | | | |
| 1 SEM | XII | 0 | 1 | | | | | | | | |
| 3 SEM | VII | 0 | 1 | 1 | 2 | | | | | | |
| 3 SEM | VI | 0 | 1 | 1 | 1 | | | | | | |
| 5 SEM | IV | 0 | 1 | 1 | 2 | 2 | 2 | | | | |
| 5 SEM | X | 0 | 1 | 1 | 2 | 2 | 2 | | | | |
| 7 SEM | V | 0 | 1 | 1 | 2 | 2 | 2 | 2 | 2 | | |
| 7 SEM | VIII | 0 | 1 | 1 | 2 | 2 | 2 | 2 | 2 | | |
| 9 SEM | IX | 0 | 1 | 1 | 2 | 2 | 2 | 3 | 3 | 3 | 3 |
| 9 SEM | XI | 0 | 1 | 1 | 2 | 2 | 2 | 2 | 2 | 2 | 2 |
| Eye closure observation | | | | | | | | | | | |
| Group | rat | D1 | D7 | D14 | D21 | D28 | D35 | D42 | D49 | D56 | D63 |
| 1 SEM | I | 0 | 1 | | | | | | | | |
| 1 SEM | XII | 0 | 1 | | | | | | | | |
| 3 SEM | VII | 0 | 1 | 1 | 3 | | | | | | |
| 3 SEM | VI | 0 | 1 | 1 | 1 | | | | | | |
| 5 SEM | IV | 1 | 1 | 1 | 2 | 3 | 4 | | | | |
| 5 SEM | X | 0 | 1 | 1 | 3 | 3 | 4 | | | | |
| 7 SEM | V | 1 | 1 | 1 | 3 | 4 | 4 | 4 | 5 | | |
| 7 SEM | VIII | 0 | 1 | 1 | 3 | 3 | 4 | 5 | 5 | | |
| 9 SEM | IX | 0 | 1 | 1 | 3 | 4 | 4 | 4 | 5 | 5 | 5 |
| 9 SEM | XI | 0 | 1 | 1 | 3 | 4 | 4 | 5 | 5 | 5 | 5 |
| TOTAL (Summation of Vibrissae and eye closure observation) | | | | | | | | | | | |
| Group | rat | D1 | D7 | D14 | D21 | D28 | D35 | D42 | D49 | D56 | D63 |
| 1 SEM | I | 0 | 2 | | | | | | | | |
| 1 SEM | XII | 0 | 2 | | | | | | | | |
| 3 SEM | VII | 0 | 2 | 2 | 5 | | | | | | |
| 3 SEM | VI | 0 | 2 | 2 | 2 | | | | | | |
| 5 SEM | IV | 1 | 2 | 2 | 4 | 5 | 6 | | | | |
| 5 SEM | X | 0 | 2 | 2 | 5 | 5 | 6 | | | | |
| 7 SEM | V | 1 | 2 | 2 | 5 | 6 | 6 | 6 | 7 | | |
| 7 SEM | VIII | 0 | 2 | 2 | 5 | 5 | 6 | 7 | 7 | | |
| 9 SEM | IX | 0 | 2 | 2 | 5 | 6 | 6 | 7 | 8 | 8 | 8 |
| 9 SEM | XI | 0 | 2 | 2 | 5 | 6 | 6 | 7 | 7 | 7 | 7 |

We, hereby show 12 pictures obtained from each one of the animals (Figures 1 through 12). By using these images in the qualitative histological analysis we can notice in the 0 SEM group (Figures 1 and 2) the presence of regular and circular fibers, homogeneously distributed throughout the whole field. In the 1 SEM (Figures 3 and 4) group we hardly noticed any myelinated fiber, and in Figure 4 we see a dye build up in part of the field. In the 3 SEM group, observing Figure 5 (rat VII), we noticed the

presence of small gauge myelinated fibers grouped around some nerve areas; now, on Figure 6 (rat VI), we noticed an image very much similar to what was seen in the 1 SEM group. In Figure 8 (rat X), from the 5 SEM group, we noticed a “retraction” of the material, and this prevented a qualitative analysis; however, on Figure 7, we observed an increase in the presence of small myelinated fibers throughout the whole neural area. In the 7 SEM (Figures 9 and 10) and 9 SEM (Figures 11 and 12) groups, such

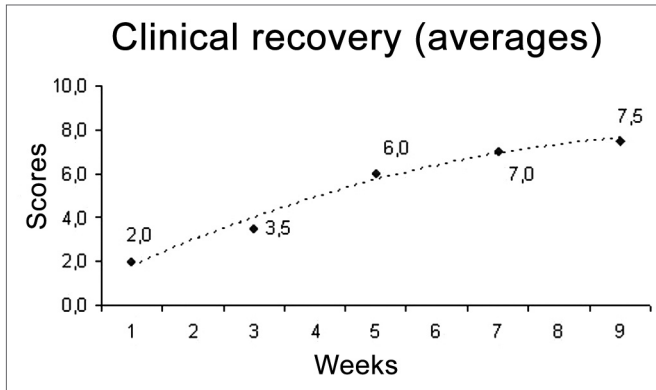


Chart 1. Clinical recovery averages after facial nerve sectioning and suturing.

presence increases even further, already showing some larger fibers, similar to what we noticed for the 0 SEM group, especially in Figure 12 (rat IX).

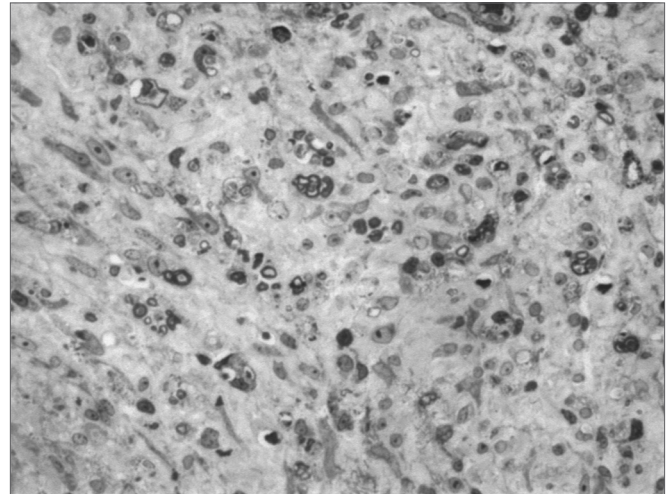


Figure 3. Facial nerve trunk microscopy 1 week after section and suturing (RAT I)

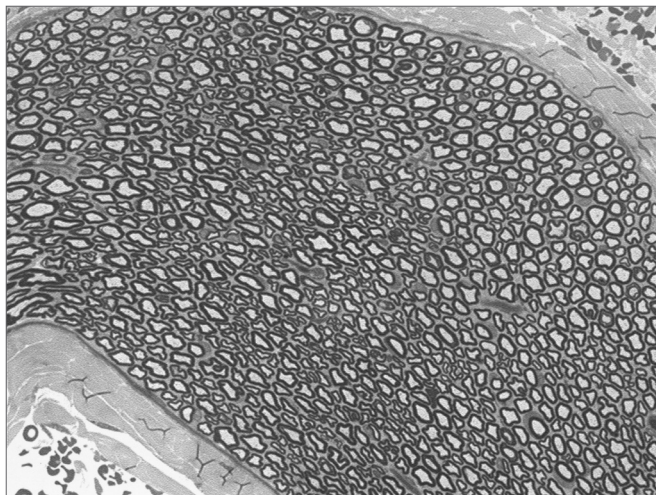


Figure 1. Facial nerve trunk microscopy - no lesion (RAT II)

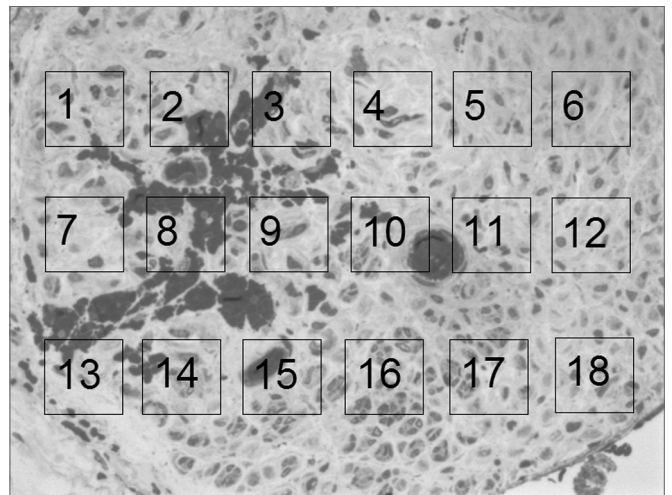


Figure 4. Facial nerve trunk microscopy 1 week after section and suturing (RAT XII); and myelinated fiber count "mask" simulation.




Figure 2. Facial nerve trunk microscopy - no lesion (RAT III)

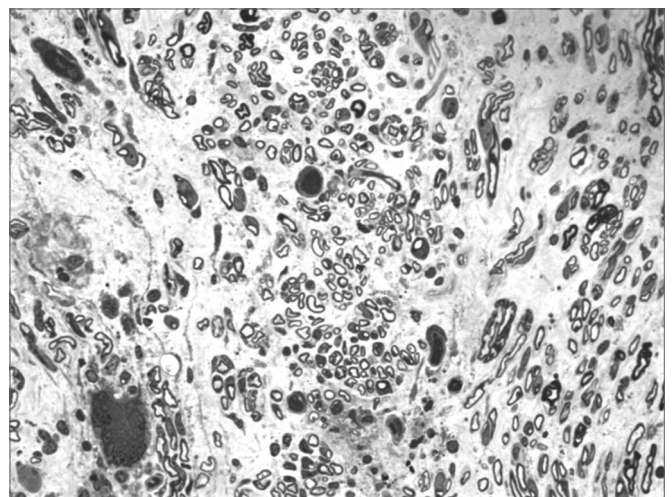


Figure 5. Facial nerve trunk microscopy 3 weeks after section and suturing (RAT VII)

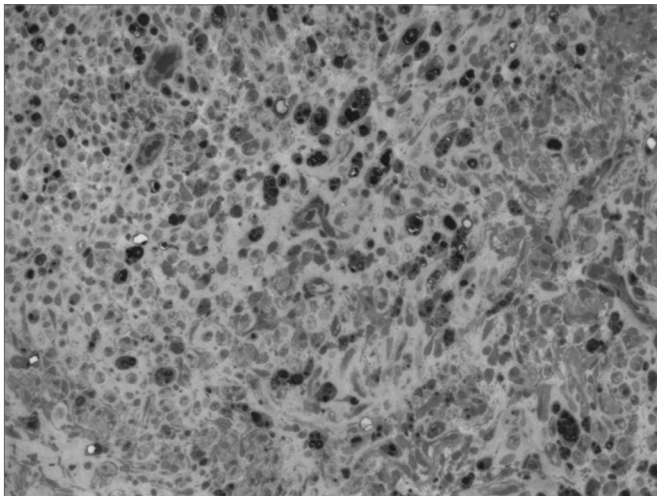


Figure 6. Facial nerve trunk microscopy 3 weeks after section and suturing (RAT VI)

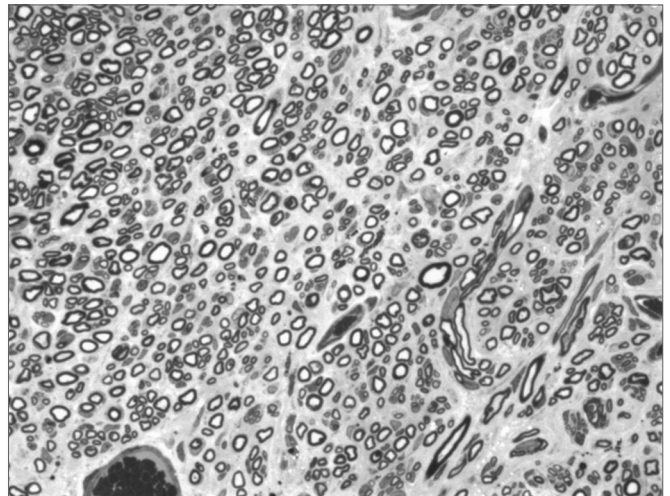


Figure 9. Facial nerve trunk microscopy 7 weeks after section and suturing (RAT V)

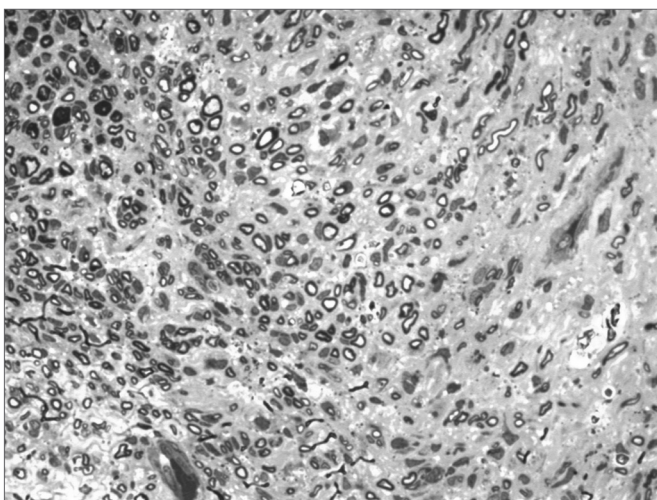


Figure 7. Facial nerve trunk microscopy 5 weeks after section and suturing (RAT IV)

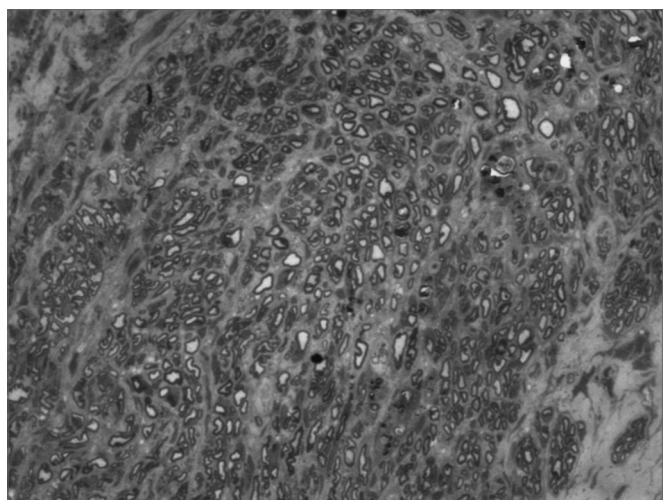


Figure 10. Facial nerve trunk microscopy 7 weeks after section and suturing (RAT VIII)

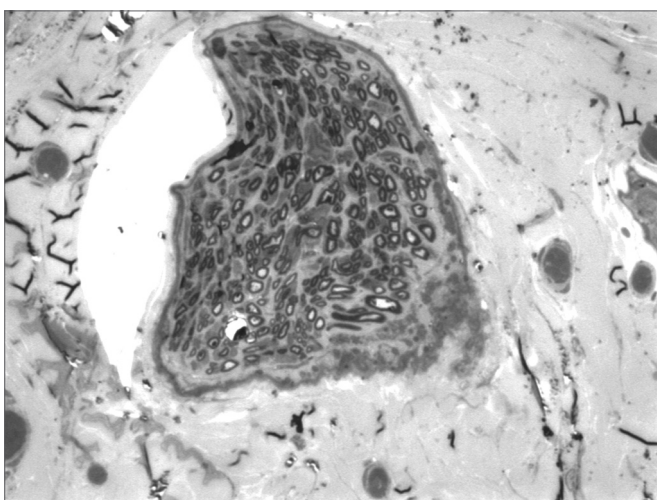


Figure 8. Facial nerve trunk microscopy 5 weeks after section and suturing (RAT X)

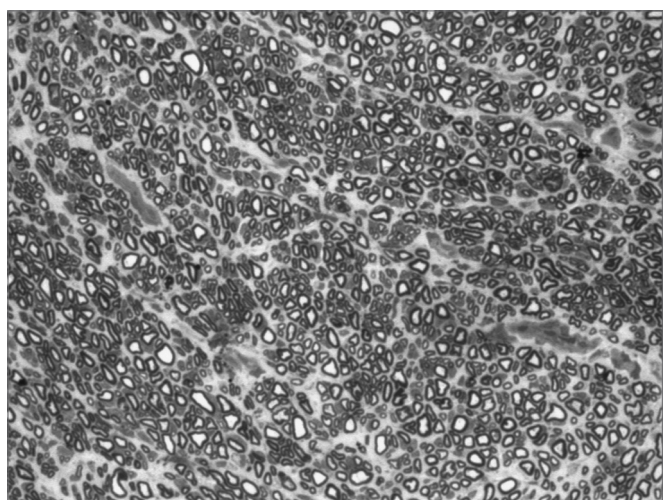


Figure 11. Facial nerve trunk microscopy 9 weeks after section and suturing (RAT XI)

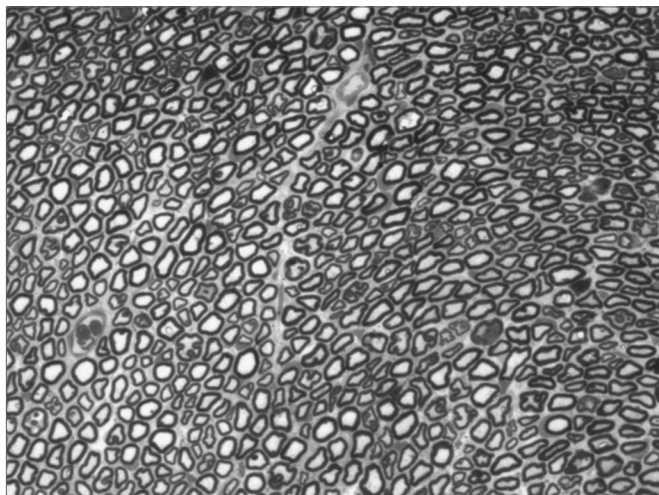


Figure 12. Facial nerve trunk microscopy 9 weeks after section and suturing (RAT IX)

In the quantitative histology analysis, we had problems in two images. In Figure 4, because of the dye build up that was previously mentioned, it was necessary to change three of the nine windows randomly chosen in order to proceed with the count. In Figure 8, the material “retraction” made it impossible to carry out even its quantitative analysis. Table 2 depicts the histometric analysis data, compiling the counts of each one of the nine “windows” randomly chosen for each rat, total count for each animal and the average for each group. We noticed a temporal increment in the number of myelinated fibers, and for group 7 SEM we attained values that were very close to those from group 0 SEM, and this was surpassed

in group 9 SEM. Chart 2 depicts this very fact. We also did not do statistical analysis here because we had a sample of only two animals per group.

In an attempt to observe the correlation between the results obtained from clinical observation and the count of myelinated fibers, presented on Table 3 and Chart 3, that correlate these two series of results, we organized the rats in an ascending series of results in the counts of myelinated fibers, excluding rat X from this analysis, since we were unable to obtain a histometric analysis for it, as previously mentioned. Afterwards, we listed its results in the clinical observations and noticed a direct correlation between both results, especially in groups 1 SEM, 3 SEM and 5 SEM, in which a greater fiber count indicated a higher clinical score. Now, in groups 7 SEM and 9 SEM, a higher count did not point towards a better and directly related clinical result.

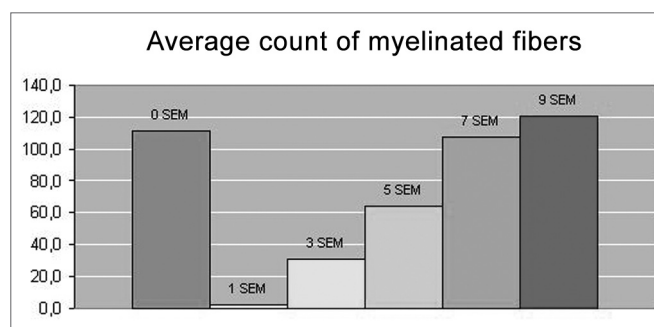


Chart 2. Myelinated fiber count averages.

Table 2. Results of myelinated fibers count and average per group.

| GROUP | RAT | TOTAL RAT | | | | | | | | | | AVERAGE GROUP |
|-------|------|-----------|----|----|----|----|----|----|----|----|-----|---------------|
| 0 SEM | II | 17 | 13 | 14 | 17 | 16 | 12 | 13 | 11 | 14 | 127 | 111,5 |
| 0 SEM | III | 12 | 9 | 9 | 9 | 10 | 11 | 14 | 11 | 11 | 96 | |
| 1 SEM | I | 0 | 1 | 0 | 1 | 0 | 0 | 1 | 1 | 0 | 4 | 2,0 |
| 1 SEM | XII | 0 | 0 | 0 | 0 | 0 | 0 | 0 | 0 | 0 | 0 | |
| 3 SEM | VII | 1 | 9 | 4 | 7 | 2 | 9 | 4 | 6 | 16 | 58 | 30,5 |
| 3 SEM | VI | 0 | 1 | 0 | 0 | 2 | 0 | 0 | 0 | 0 | 3 | |
| 5 SEM | IV | 10 | 6 | 3 | 12 | 3 | 2 | 9 | 13 | 6 | 64 | 64,0* |
| 5 SEM | X | \ | \ | \ | \ | \ | \ | \ | \ | \ | \ | |
| 7 SEM | V | 16 | 15 | 15 | 11 | 7 | 10 | 15 | 12 | 11 | 112 | 108,0 |
| 7 SEM | VIII | 10 | 18 | 12 | 12 | 14 | 3 | 13 | 9 | 13 | 104 | |
| 9 SEM | IX | 14 | 13 | 8 | 8 | 10 | 12 | 9 | 12 | 8 | 94 | 121,0 |
| 9 SEM | XI | 17 | 18 | 17 | 18 | 19 | 14 | 16 | 15 | 14 | 148 | |

* data related only to rat IV

Table 3. Correlation between the results of myelinated fiber count and behavioral observation score.

| RAT | XII | VI | I | VII | IV | IX | VIII | V | XI |
|----------------|-----|----|----|-----|----|----|------|-----|-----|
| GROUP | 1S | 3S | 1S | 3S | 5S | 9S | 7S | 7S | 9S |
| Fiber count | 0 | 3 | 4 | 58 | 64 | 94 | 104 | 112 | 148 |
| Clinical score | 2 | 2 | 2 | 5 | 6 | 8 | 7 | 7 | 7 |

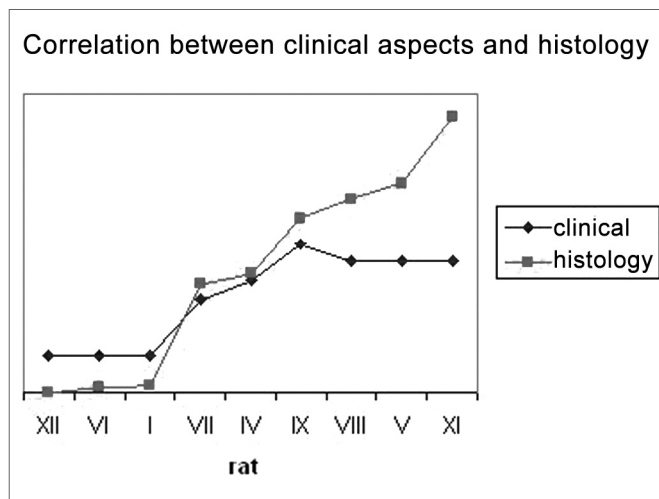


Chart 3. Correlation between clinical results and fiber count.

DISCUSSION

Setting up an experimental paradigm for a FN lesion is the first and fundamental step towards the study of actions from potential neurotrophic factors. Although we agree that we still lack a perfect experimental model¹², such should bear at least the characteristics of being practical and easily reproducible, thus allowing for a temporal and objective analysis of the neural regenerative process. Many animals can be used in order to set up experimental models for the study of the FN, such as cats², rabbits¹⁵, hamsters¹⁴, mice¹⁵, guinea pigs¹⁶ and pigs¹⁷. We chose the Wistar rat, because besides being an animal already used in similar studies published in the literature¹⁸⁻²⁵, it is easily accessible in our Institution, it is easy to handle, it may be kept in collective cages, it is easily anesthetized and the animal with facial paralysis does not present greater morbidity in order to feed itself, even when the paralysis is bilateral¹². We chose to standardize the model with male animals because there are reports on gender influence on neural regeneration, being naturally greater for female hamsters¹⁴, and also so that we would not have to control the animal hormonal cycle. The extratemporal facial nerve anatomy in rats is also described in the literature, its trunk has approximately 6mm, it is easy and constantly accessed by a simple behind-the-ear incision, bearing variations in less than 2.1% in serial counts of myelinated fibers, and it is not influenced by the animal age and weight^{12,26}. As

to the cons related to such animal, we noticed that the FN trunk is monofascicular, which is different from that of human beings¹², besides the little facial expression in these animals, and this makes it difficult to establish visual scales of mobility recovery.

Once decided upon the animal, we have to choose the type of neural lesion. Numerous studies have been using the “crushing” of the FN^{8,21,27,28}, however, we chose to section the nerve completely since it is a more reproducible lesion, always grade V in the Sutherland classification^{17,18}. In repairing a complete FN lesion we could decide to use silicon tubes, collagen rods, fibrin glue, and temporal fascia or free neural or muscle grafts^{1,2,7,13}. We also chose to do epineural suturing, because besides being well established in the literature^{12,16,18,19,20,24,25,29,30}, it better mimics the surgical correction carried out in human being nerves³¹, and it was relatively easy to obtain a proper alignment and low stump tension with a single stitch as is the case in rats.^{1,7}

Numerous methods have been already proposed aiming at improving neural regeneration in animals. Behavioral scales^{8,28,32,33}, electrophysiological analysis^{2,10,19,32}, muscle fiber analysis^{19,20,29}, central nuclei analysis^{18,19,21-23,30,34-36} and axon analysis^{2,10,16,19,31-33} have been described in the literature. We decided to use a behavioral analysis because it reflects not only an anatomical aspect, but also the main regeneration issue, which is facial movement function recover³⁷. By means of FN lesion studies in rodents, other authors have been using clinical scales observing the movement of vibrissae, very similar to our own.^{8,28} In an attempt to enhance behavioral analysis; we associated eye closure observation, based on the experience of other authors who worked with other animals, such as cats². Notwithstanding, it is undeniable that such behavioral measure has an important component of subjectiveness, and is less reproducible. We then decided to associate a histometric assessment by light microscopy of the axon myelinated fibers that besides reported in the literature, bears an acceptable cost^{16,19,31,32,37-39}. It is important to stress some of the limitations of this technique. It does not allow to check the presence of non-myelinated fibers - only seen by means of electron microscopy, and such technique is of very high cost to be used in large series^{13,37} - and does not assess the diameter, nor the thickness of the myelinated sheath - items that would be interesting to be used in order to follow up the regeneration process. We tried to assess these last two items through automated analysis of areas captured by color matrix systems; however, the data were not reproducible and reliable, since there is great difficulty in dyeing myelin with a specific color - problem already reported by other authors³⁷.

Once the model is established, we then discuss our results compared to the observations of other authors in the literature. As to the behavioral observation scale, we attained results that showed a temporal recovery of facial

movement, well correlated to the results attained by other authors who used similar models with rodents^{27,28}. Within a maximum score of 10, our animals had a recover of 50% in function between the third and the fifth weeks, and of 75% in the 9th week, when we terminated the experiment. Eye closure seemed to be the earliest and more easily observable item for this analysis, and vibrissae movement return was the slowest one. Such observation is in tune with that of other authors who stress that the blink reflex partial return is the earliest sign of neural recovery in rodents²⁸.

As to our histology qualitative analysis, we observed the appearance of small groups of myelinated fibers, especially after the third week, and such process was intensified on the subsequent weeks, followed by an increase in their diameters, especially during the 7th and the 9th weeks. This observation finds corresponding ones in the literature in investigations carried out with rats, the FN and the sciatic nerve³⁸⁻⁴⁰, in which the authors show a gradual increase in the number and diameter of myelinated fibers alongside neural regeneration. This would reflect the initial multiple sprouting process of fibers from the proximal stump that invade the distal stump and that increase in diameter with time, thus reflecting a greater capacity for neural conduction. The time in which we started to notice neural regeneration is also in agreement with the classical observations already described in the literature, in which Wallerian Degeneration would be completed around the 2nd week; and fiber sprouting from the proximal stump fibers and the onset of distal stump "invasion" would happen around the 10th day^{1,7,41}.

As to our histometric quantitative analysis, we observed that after the 3rd week there was a gradual increase in myelinated fibers count, reaching a value very close to normal on the 7th week, and surpassing that on the 9th week. Such fact also finds similarities in the literature, where many authors report a progressive increase on the number of myelinated fibers alongside the regeneration process³⁸⁻⁴⁰. In our opinion, the very fact that the 9th week count surpasses that of the control group (OSEM), is due to the smaller fiber diameter in this group when compared to those of the control group, such fibers would be more "immature" than those of greater diameter. So much so, that the IX-9SEM (Figure 9) rat was the one that presented the highest qualitative similarity of fibers in comparison to group O SEM, and also a better clinical score, had less fibers than the XI-9SEM, V-7SEM and VIII-7SEM rats. However, since we did only 2 animals per group, it would not be adequate to make any statistical comparison among them.

When we compare the results of our clinical and histometric clinical behavior analysis (Chart 3), we can see that a higher clinical score is followed by a greater fiber count, especially up to a plateau made up by the animals

in groups 7SEM and 9SEM, where the count remains ascending and the clinical improvement is practically stable. Such later dissociation among neural regeneration parameters that occurred in the last weeks seems to happen because of two facts. First, our clinical evaluation scale is somewhat limited, since we highlighted previously that rats do not have refined facial movements available for such. And second, that an increase in the number of fibers only, does not necessarily reflect an improvement in final movement function, and such fact has also been stressed in the literature^{1,7,37,42}.

CONCLUSION

We conclude that there is no perfect experimental paradigm for the study of FN recovery after a lesion. Notwithstanding, we believe to have established a proper method through behavioral and histometric analysis.

REFERENCES

1. Choi D, Dunn LT. Facial nerve repair and regeneration: an overview of basic principles for neurosurgeons. *Acta Neurochir (Wien)* 2001;143:107-14.
2. Bento RF, Miniti A. Comparison between fibrin tissue adhesive, epineural suture and natural union in the intratemporal facial nerve of cats. *Acta Otolaryngol Suppl* 1989;465:1-36.
3. Khomura E, Yuguchi T, Yoshimine T, Fujinaka T, Koseki N, Sano A, Kishino A, Nakayama C, Sakaki T, Nonaka M, Takemoto O, Hayakawa T. BDNF atelocollagen mini-pellet accelerates facial nerve regeneration. *Brain Research* 1999;849:235-8.
4. Gluck T. Ueber Transplantation, regeneration und entzündliche Neubildung. *Berl Klin Wochenschr* 1881;18:529-31.
5. Bunnell S. Suture of the facial nerve within the temporal bone with a report of the first successful case. *Surg Gynec Obst* 1927;45:7-12.
6. Davis L, Perret G, Carroll W. Surgical principles underlying the use of grafts in the repair of peripheral nerve injuries. *Annals of Surg* 1945;121(5):686-98.
7. Toriumi DM, Wollford TJ, Teitlebaum B, Sabnani K, O'Grady K. Growth factors in nerve regeneration. *Facial Plastic Surg Clin North Am* 1997;5(3):289-302.
8. Gilad VH, Tetzlaff WG, Rabey JM, Gilad GM. Accelerated recovery following polyamines and aminoguanidine treatment after facial nerve injury in rats. *Brain Research* 1996;724:141-4.
9. Lindsay RM. Neuron saving schemes. *Nature* 1995;373:289-90.
10. Byers JM, Clark KF, Thompson GC. Effect of pulsed electromagnetic stimulation on facial nerve regeneration. *Arch Otolaryngol Head Neck Surg* 1998;124:383-9.
11. Abercrombie M. Estimation of nuclear population from microtome sections. *Anatomical Record* 1946;94(2):239-46.
12. Mattox DE, Felix H. Surgical anatomy of the rat facial nerve. *Am J Otol* 1987;8(1):43-7.
13. Spector JG, Lee P, Derby A, Roufa DG. Early stages of facial nerve regeneration through silicone chambers in the rabbit. *Laryngoscope* 1991;101:1109-23.
14. Kinderman NB, Jones KJ. Axotomy-induced changes in ribosomal RNA levels in female hamster facial motoneurons: differential effects of gender and androgen exposure. *Exp Neurol* 1994;126:144-8.
15. Fawcett JP, Bamji SX, Causing CG, Aloyz R, Ase AR, Reader TA, McLeane JH, Miller FD. Functional evidence that BDNF is an anterograde neural trophic factor in the CNS. *J Neurosci* 1998;18(8):2808-21.
16. Yuh-Shyang C, Chuan-Jen H, Tien-Chen L, Yanagihara N, Murakami S. Histological rearrangement in the facial nerve and central nuclei

- following immediate and delayed hypoglossal-facial anastomosis. *Acta Otolaryngol* 2000;120:551-6.
17. David DM. Facial nerve trauma: optimal timing for repair. *Laryngoscope* 1991;101:835-48.
 18. Guntinas-Lichius O, Streppel M, Angelov DN, Stennert E, Neiss WF. Effect of delayed facial-facial suture on facial nerve regeneration: a horseradish peroxidase tracing study in the rat. *Acta Otolaryngol* (Stockh) 1997;117:670-4.
 19. Guntinas-Lichius O, Effenberger K, Angelov DN, Klein J, Streppel M, Stennert E, Neiss WF. Delayed rat facial nerve repair leads to accelerated and enhanced muscle reinnervation with reduced collateral axonal sprouting during a definitive period using a cross-anastomosis paradigm. *Exp Neurol* 2000;162:98-111.
 20. Jergovic D, Stal P, Lindman D, Lindvall B, Hildebrand C. Changes in a rat facial nerve after facial nerve injury and repair. *Muscle Nerve* 2001 Sept;1202-12.
 21. Terao E, Janssens S, Aguilar VDB, Portier MM, Klosen P. In vivo expression of the intermediate filament peripherin in rat motoneurons: modulation by inhibitory and stimulatory signals. *Neurosc* 2000;101(3):679-88.
 22. Hol EM, Schwaiger FW, Werner A, Schmitt A, Raivich G, Kreutzberg GW. Regulation of the lim-type homebox gene islet-1 during neuronal regeneration. *Neurosc* 1999;88(3):917-25.
 23. Hass CA, Donath C, Kreutzberg GW. Differential expression of immediate early genes after transection of the facial nerve. *Neurosc* 1993;53(1):91-99.
 24. Fernandez E, Pallini R, Marchese E, Lauretti L, La Marca F. Qualitative, morphological, and somatotopic nuclear changes after facial nerve regeneration in adult rats: a possible challenge to the "no new neurons" dogma. *Neurosurg* 1995;37(3):456-63.
 25. Guntinas-Lichius O, Neiss WF, Schulte E, Stennert E. Qualitative image analysis of the chromatolysis in rat facial nerve and hypoglossal motoneurons following axotomy with and without reinnervation. *Cell Tissue Res* 1996;286:537-41.
 26. Semba K, Egger MD. The facial "motor" nerve of the rat: control of vibrissal movement and examination of motor and sensory components. *J Comparative Neurol* 1986;247:144-58.
 27. Jones KJ, Brown TJ, Damaser M. Neuroprotective effects of gonadal steroids on regenerating peripheral motoneurons. *Brain Res Review* 2001;37:372-82.
 28. Jones KJ. Recovery from facial paralysis following crush injury of the facial nerve in hamsters: differential effects of gender and androgen exposure. *Exp Neurology* 1993;121:133-8.
 29. Constantinidis J, Akbarian A, Steinhart H, Iro H, Mautes A. Morphological changes of denervated and reinnervated rat facial muscle. *Acta Otolaryngol* 2001;121:763-7.
 30. Fernandez E, Pallini R, Marchese E, Lauretti L, Bozzini V, Sbriccoli A. Reconstruction of peripheral nerves: the phenomenon of bilateral reinnervation of muscles originally innervated by unilateral motoneurons. *Neurosurg* 1992;30(3):364-9.
 31. Wong BJJ, Mattox DE. The effects of polyamines and polyamine inhibitors on rat sciatic and facial nerve regeneration. *Exp Neurol* 1991;111:263-6.
 32. Yian CH, Paniello RC, Spector JG. Inhibition of motor nerve regeneration in a rabbit facial nerve model. *Laryngoscope* 2001;111:786-91.
 33. Guntinas-Lichius O, Angelov DN, Tomov TL, Dramiga J, Neiss WF, Wewetzer K. Transplantation of olfactory ensheathing cells stimulates the collateral sprouting from axotomized adult rat facial motoneurons. *Exp Neurol* 2001;172:70-80.
 34. Dauvergne C, Pinganaud G, Buisseret P, Buisseret-Delmas C, Zerari-Mailly F. Reticular premotor neurons projecting to both facial and hypoglossal nuclei receive trigeminal afferents in rats. *Neurosc Lett* 2001;311:109-12.
 35. Sendtner M, Kreutzberg GW, Thoenen H. Ciliary neurotrophic factor prevents the degeneration of motor neurons after axotomy. *Nature* 1990;345:440-1.
 36. Mattsson P, Aldskogius H, Sevansson M. Nimodipine-induced improved survival rate of facial motor neurons following intracranial transection of the facial nerve in the adult rat. *J Neurosurg* 1999;90:760-5.
 37. Frykman GK, McMillan PJ, Yegge S. A review of experimental methods measuring peripheral nerve regeneration in animals. *Orthop Clin North Am* 1988;19(1):209-19.
 38. Lewin SL, Utley DS, Cheng ET, Verity AN, Terris DJ. Simultaneous treatment with BDNF and CNTF after peripheral nerve transection and repair enhances rate of functional recovery compared with BDNF treatment alone. *Laryngoscope* 1997;107:992-9.
 39. Gershenbaum MR, Roisen FJ. The effects of dibutyl cyclic adenosine monophosphate on the degeneration and regeneration of crush-lesioned rat sciatic nerves. *Neurosc* 1980;5:1565-80.
 40. McQuarrie IG, Grafstein B, Gershon MD. Axonal regeneration in the rat sciatic nerve: effect of a conditioning lesion and of dbcAMP. *Brain Research* 1977;132:443-53.
 41. Terenghi G. Peripheral nerve regeneration and neurotrophic factors. *J Anat* 1999;194:1-14.
 42. Guntinas-Lichius O, Irintchev A, Streppel M, Lenzen M, Grosheva M, Wewetzer K, Neiss WF, Angelov DN. Factors limiting motor recovery after facial nerve transection in the rat: combined structural and functional analyses. *Eur J Neurosc* 2005;21:391-402.