

MYCETOMA BY *NOCARDIA ASTEROIDES*: A 9 YEAR FOLLOW-UP

Giani de Oliveira SARAÇA (1), Loan TOWERSEY (2) Roderick James HAY (3), Alberto Thomaz LONDERO (4), Eunice de Castro Soares MARTINS (5) Alberto Torres AMORA (6), Kátia Maria Pereira Nunes REIS (7), Ana Maria Nunes MENDONÇA (8) & Rogerio Ribeiro ESTRELLA (9).

SUMMARY

An extensive and severe actinomycetoma by *Nocardia asteroides*, a rare etiologic agent of this infection in Brazil, observed during a 9 year follow-up is reported.

Unsuitable social and financial conditions led to amputation as the only possible solution for this case, no signs of infection relapse having been observed in three years after his surgery.

Key Words: *Nocardia asteroides* mycetoma; *Nocardia* infections; Actinomycetoma.

INTRODUCTION

The term mycetoma encompasses infections of the subcutaneous tissues caused by fungi or by filamentous aerobic actinomycetes that are present in the lesions as grains. The grain is composed of a tangled mass of hyphae or filaments or by similar structures embedded in a cement-like material. According to composition grain mycetomas can be classified in eumycotic or actinomycotic forms, caused respectively by fungi or by aerobic actinomycetes. Commonly the infection begins as a nodule at the site of implantation of the microorganisms which live in the soil, wood debris or thorns. In the nodule, the grain lies within a microabscess. The lesions spread slowly to adjacent tissues and may involve muscles and bones. The abscesses extend through the skin forming fistulae discharging serosanguinous or purulent material and grains.

^{5,12} Actinomycotic agents produce more extensive and obliterative bone involvement, with both lytic and hypertrophic changes. In eumycotic mycetoma there is late lytic lesion of the bone but no hypertrophic effects in the course of the disease. Once bone infection is established, the response to medical treatment is usually poor.¹²

Actinomycotic mycetoma is the most common mycetoma seen in Brazil. It is usually amenable to antibiotic therapy. *Nocardia asteroides* has seldom been reported as an etiologic agent of mycetoma in this country, the commonest agent being *Nocardia brasiliensis*.^{10,11,13}

An extensive and severe mycetoma by *N. asteroides*, observed through a 9 year follow-up period, is presented.

- (1) Adjunct Professor of Mycology, Instituto Biomédico, Universidade Federal Fluminense, Post Graduation student, Dermatology Division, HUAP, Universidade Federal Fluminense, RJ, Brazil.
- (2) Assistant Professor of Parasitology, FMT, FESO, Dermatologist, CPN/INAMPS, and CSCAS/SES, PhD Student, Post Graduation in Medicine - Dermatology Division, HUCFF, Universidade Federal do Rio de Janeiro, RJ, Brazil.
- (3) Professor of Cutaneous Medicine, St. John's Institute of Dermatology, Guy's Hospital, United Medical and Dental Schools of Guy's and St. Thomas' Hospitals, University of London, London, U.K.
- (4) Professor of Mycology, Department of Microbiology and Parasitology (Mycology Division), Universidade Federal de Santa Maria, RS, Brazil.
- (5) Adjunct Professor of Mycology, Instituto Biomédico, Universidade Federal Fluminense, RJ, Brazil.
- (6) Assistant Professor of Dermatology, Faculdade de Medicina de Nova Iguaçu; Post graduation student, Dermatology Division, HUAP, Universidade Federal Fluminense, RJ, Brazil.
- (7) Adjunct Professor of Mycology, Instituto Biomédico, Universidade Federal Fluminense, Niterói, Brazil.
- (8) Adjunct Professor of Pathology, Department of Pathology, Hospital Universitário Antônio Pedro, Universidade Federal Fluminense, RJ, Brazil.
- (9) Adjunct Professor of Dermatology, Division of Dermatology, Hospital Universitário Antônio Pedro, Universidade Federal Fluminense, RJ, Brazil.

Address for correspondence: Dr. Loan Towersey, MD, MA - Travessa Caio Martins, 10 - apt. 202. CEP 24220-290 Niterói, RJ, Brazil.

This long follow-up is unfrequent and shows the clinical spectrum of the natural evolution of this disease, with no systemic spreading of the infection in spite of the prolonged course of this actinomycetoma. The infection reported in this paper became unresponsive to antibiotic treatment which was initially hampered by the unsuitable social and financial conditions of the patient. Amputation, though radical a surgical procedure, still represents a viable solution in these difficult to treat cases.

CASE REPORT

In 1980 a 23 year old mulatto man sought for medical attention complaining of a lesion on his left foot. He reported having scratched his foot on the ground while working under a car. The skin surface of the affected area showed small nodules, some with a sinus opening that drained serosanguinous purulent exudate. Small white yellowish grains were seen in the exudate. His infection responded partially to irregular use of dapsone, sulfamethoxazole + trimethoprim, and sulfadiazine. After periods of therapy, the infection relapsed and spread with progressive deterioration of his clinical state (Fig. 1), and functional loss of the left lower limb. In 1989 amputation was performed below the left knee.

Foot X-ray before surgery showed increase of soft tissue that prevented observation of bone lesions. The anatomo-pathological examination of the amputated foot, however, showed extensive bone lesions (Fig. 2).

Mycologic examination of the purulent exudate in 20% potassium hydroxide revealed the presence of yellowish small granules. Gram positive filaments were seen in Gram stained granules. On Sabouraud-dextrose agar there was growth of glabrous heaped folded orange yellowish colonies that micromorphologically were composed of gram positive acid fast filaments. Colonies were only isolated after several plates of Sabouraud dextrose agar were streaked with purulent material obtained by needle aspiration from closed softened nodular lesions. The isolated actinomycete decomposed urea, but not gelatin and casein, thus identifying it as *Nocardia asteroides*.

Histological sections of the skin biopsy of initial lesion and tissue samples collected from differ-

ent areas of the amputated foot showed small amorphous grains which were stained blue with a narrow eosinophilic fringe in acute abscesses with a polymorphonuclear infiltrate. Dense fibrosis, granulation tissue rich in capillaries, epithelioid cells, histiocytes and giant cells completed the picture seen in hematoxylin eosin stains.

These granules could also be observed in PAS stained sections (Fig.3). On Gram-Brown-Brenn stain of histological sections gram positive filaments could be demonstrated. These were acid fast on the Wade stain. The bacterial filaments in the grain were highlighted by silver methanamine stain.

DISCUSSION

Actinomycetoma is more susceptible to drug therapy than eumycetoma¹², some authors advocating the idea that the smaller grains of actinomycetoma allowed better penetration and action of therapeutic agents¹¹, so cure often is obtained in Nocardial mycetoma^{4,11,13}, no relapse observed even after a long follow-up.¹¹ Even in advanced forms of infection, the disease is considered amenable to medical management. A number of different antibiotics and antimicrobials have been used in the therapy of actinomycetoma. The most effective regimen involves sulphonamides and sulphones, either dapsone with streptomycin sulfate or sulfamethoxazole + trimethoprim with streptomycin. Sulphisoxazole and sulfamethoxipridazine have also been used with variable success. Sulfadoxine-pyrimethamine plus streptomycin or rifampicin have also been useful. Sulfadiazine and tetracycline compounds (oxytetracycline and minocycline) represent therapeutic options, the latter achieving positive results in *Actinomadura madurae* infection. Various penicillins in combination with various other drugs were used in the past, these associations being supplanted at present. The use of amikacin alone or in combination with sulfamethoxazole + trimethoprim is recommended for extensive treatment unresponsive cases, synergistic effect of the antimicrobials having been demonstrated *in vitro* in *N. brasiliensis* strains.¹⁴

At first medical examination the patient presented with tumour and sinus formation and grains, the so-called triad of a mycetoma¹⁵. This diagnosis was confirmed by laboratorial findings, and appropriate therapy initiated. Lack of financial re-

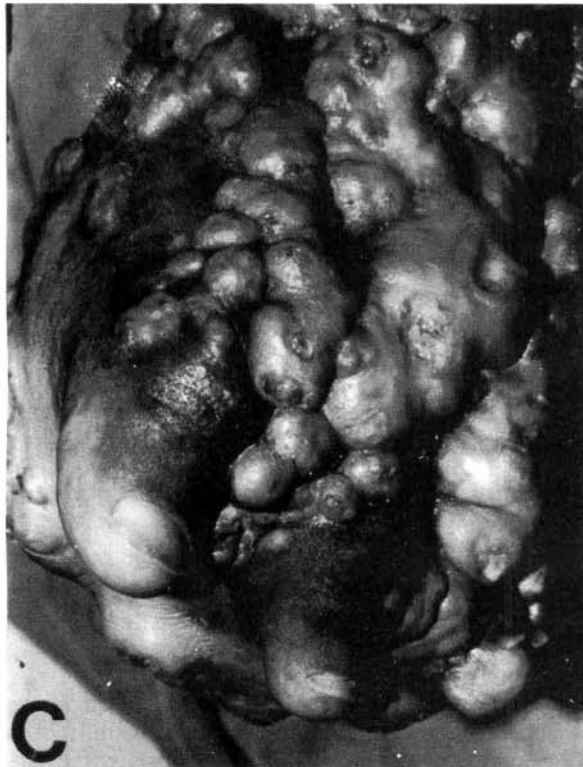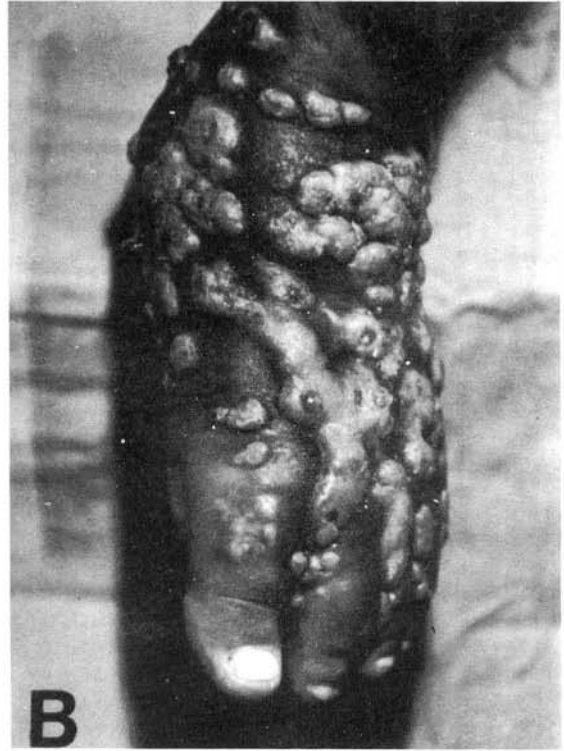

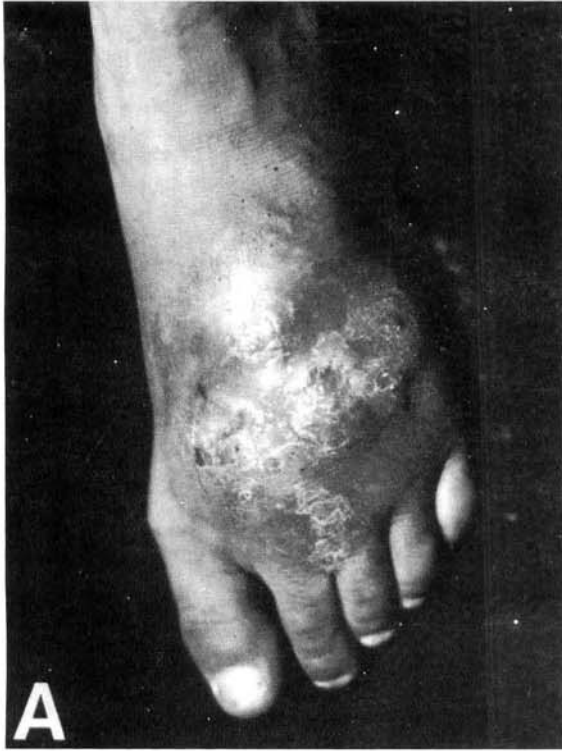
Fig. 1 - A, Initial aspect of mycetoma pedis caused by *Nocardia asteroides* in 1981. B, Extensive and severe involvement of the left lower limb with active and cicatricial lesions of mycetoma in 1987. C, Progressive infection with disfigurement of the affected foot in 1989

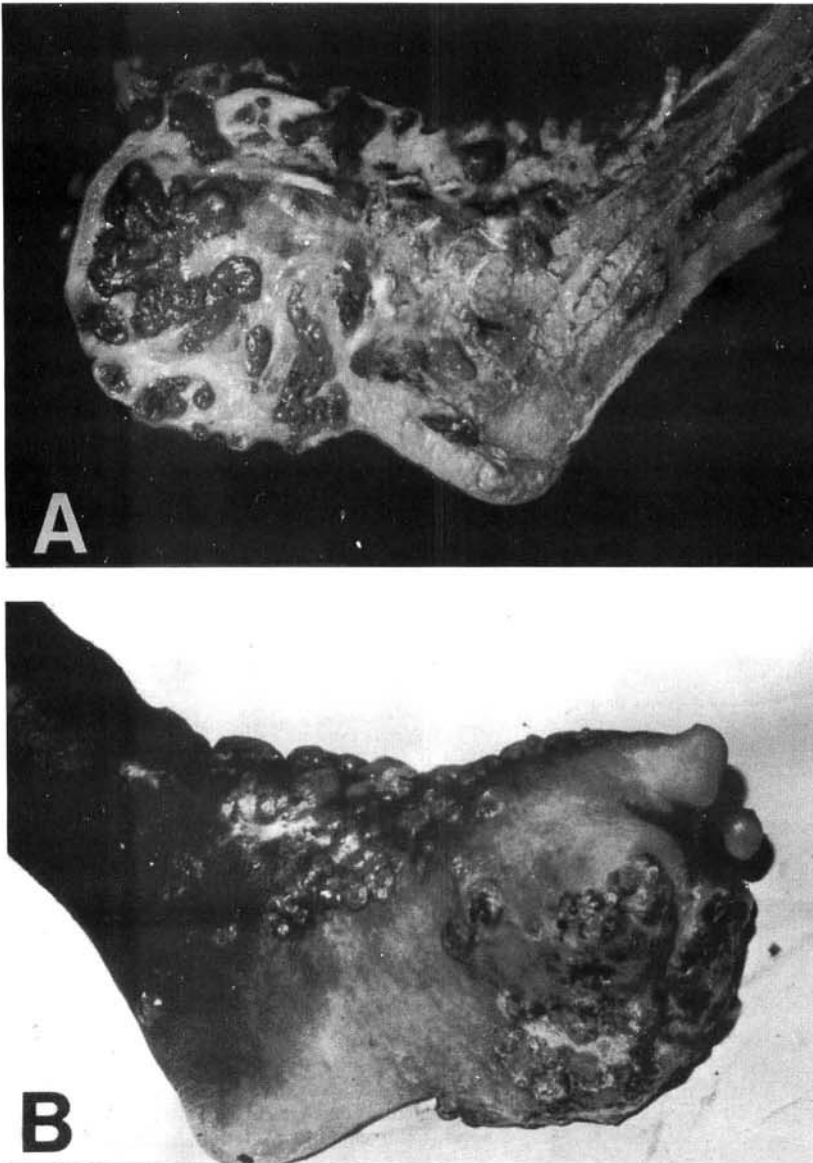


Fig. 2 - A, Severity of osseous damage of the amputated foot by *Nocardia asteroides* mycetoma bone invasion. B, Clinical picture before amputation.

sources, and personal problems led him to abandon therapy repeatedly each time there was sufficient clinical improvement to return to work. Progressive involvement of the affected limb with increasing massive fibrosis and problems in lymphatic drainage made chemotherapy inefficient because of the inability of the drugs to penetrate into cystic or fibrotic areas in sufficient concentrations to inhibit the causal agent⁷. Bone lesions also represented a therapeutical problem¹². Disfigurement and disability followed. Amputation allowed the patient to readjust professionally, and return to a productive life with the aid of a prosthesis. No

signs of a recurrence of infection were evident in the three years of follow-up after surgery. *Trichophyton rubrum* infection of the amputation stump, following occlusion by prosthesis was the only abnormality observed since. This case illustrates the natural evolution of actinomycetoma with local spread. In spite of the long duration of the infection only a limited area of the limb was affected.

Actinomycetoma is predominant in Brazil, eumycetoma representing less than one third of the reported cases. *Nocardia brasiliensis* is the most

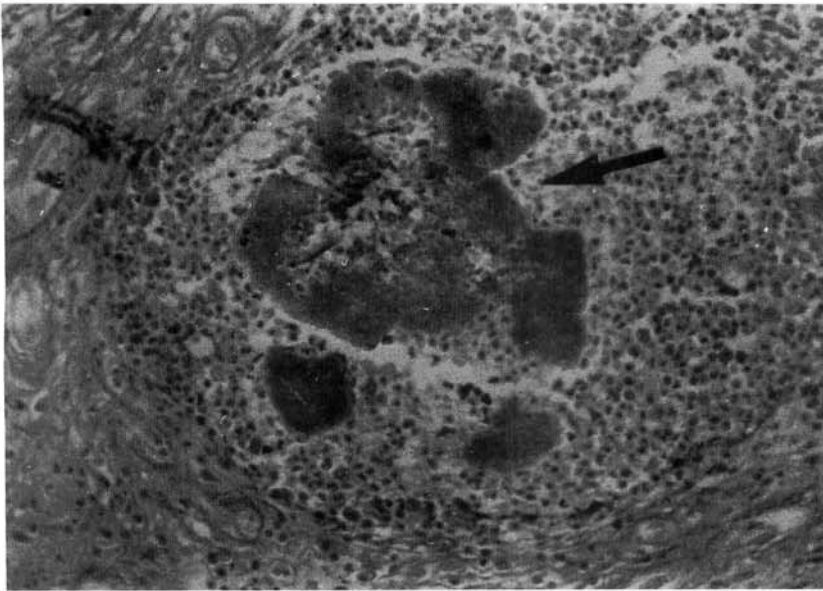


Fig. 3 - *Nocardia asteroides* granule (arrow) in histopathologic section (PAS, original magnification X100).

common agent of the infection. *Nocardia asteroides*, *Actinomadura madurae*, *Actinomadura pelletieri*, *Streptomyces somaliensis* have been less frequently isolated^{9,10}. Rarely reported in Brazil^{3,10}, *N. asteroides* mycetoma has been found in Uruguay⁴, but has not been isolated from mycetomas in Rio Grande do Sul¹¹, the Southern Brazilian State which has a frontier with Uruguay and presents many geographic, climatic and socio economic similarities. A common immunodominant protein has been recently identified in three medically important *Nocardia* species (*N. asteroides*, *N. brasiliensis*, *N. caviae*).² Host immune response and virulence of the infective organism are undoubtedly important in the pathophysiology of *Nocardia* infections, mycetoma inclusively. *Nocardia* species, which are soil inhabitants, adapt to parasitism by mechanisms so far poorly understood. In experimental *Nocardia caviae* mycetoma infection the loss of cell-wall constituents and formation of L-forms appears to favour resistance to destruction by macrophages, evasion of host defense mechanisms, prolonging parasite survival, leading to chronic infection.⁶ Differences in experimental pathogenicity of *Nocardia* species isolated from different sources (environmental X human)¹ emphasize the need for comprehensive studies in order to understand better the adaptative mechanisms that allow the organism to survive.

This knowledge may be used to improve therapy⁶, provided social and financial conditions

are suitable. Amputation is the only possible solution for drug treatment failures.

RESUMO

Micetoma por *Nocardia asteroides*: Acompanhamento de 9 anos

É relatado um caso de micetoma actinomicótico por *Nocardia asteroides*, raro agente desta infecção no Brasil, acompanhado ao longo de 9 anos de evolução, com lesões extensas e profundas. As precárias condições sócio-econômicas do paciente tornaram a amputação a única solução viável para este caso, não tendo sido observados sinais de recidiva da infecção em três anos após a cirurgia.

REFERENCES

1. ANGELES, A. M. & SUGAR, A. M. - Identification of a common immunodominant protein in culture filtrates of three *Nocardia* species and use in etiologic diagnosis of mycetoma. *J. clin. Microbiol.*, 25: 2278-2280, 1987.
2. CALEGARI, L.; ASCONEGUY, F. & CONTI-DIAZ, I. A. - Experimental pathogenicity of isolates of *Nocardia asteroides*, *Nocardia brasiliensis* and *Nocardia caviae* from different sources. *Sabouraudia*, 20: 295-302, 1982.
3. CARINI, A. - Um caso de micetoma actinomicótico da perna produzido por "*Nocardia asteroides*". *Arq. Biol.*, 14: 132-137, 1930.

4. CONTI-DIAZ, I. A. - Mycetoma and premycetomatous lesions in Uruguay. *Mycopathologia (Den Haag)*, 72: 59-64, 1980.
5. HAY, R. J. - Nocardial infection of the skin. *J. Hyg. (London)*, 91: 385-391, 1983.
6. HAY, R. J. - A thorn in the flesh. A study of the pathogenesis of subcutaneous infections. *Clin exp. Derm.*, 14: 407-415, 1989.
7. HAY, R. J. & COLLINS, M. J. - An ultrastructural study of pale eumycetoma grains. *Sabouraudia*, 21: 261-269, 1983.
8. HAY, R.J. & MACKENZIE, D.W.R. - Mycetoma (madura foot) in the United Kingdom - a survey of forty-four cases. *Clin. exp. Derm.*, 8: 553-562, 1983.
9. KALB, R.R.; KAPLAN, M.H. & GROSSMAN, M.E. - Cutaneous nocardiosis. Case reports and review. *J. Amer. Acad. Derm.*, 13: 125-133, 1985.
10. LACAZ, C.S. - Distribuição geográfica dos micetomas no Brasil. *An. bras. Derm.*, 56: 167-172, 1981.
11. LONDERO, A.T.; RAMOS, C. D. & MATTE, S.W. - Micetomas actinomicóticos no Rio Grande do Sul: relato de quatro casos. *Mem. Inst. Oswaldo Cruz*, 81: 73-77, 1986.
12. MAGANA, M. - Mycetoma. *Int. J. Derm.*, 23: 221-236, 1984.
13. MELLO FILHO, A.; PROENÇA, N. G. ; ROSA, I.P. & PEREIRA, W. A. - Um caso de micetoma nocardioso. Reavaliação doze anos após cura clínica. *An. bras. Derm.*, 57: 215-218, 1982.
14. WELSH, O. - Amikacina-Trimethoprim-Sulfamethoxazole en el tratamiento de micetoma actinomicóticos. Monterrey, Mexico. 1989. (Tesis Doctoral - Facultad de Medicina de la Universidad Autonoma de Nuevo Leon).
15. ZAIAS, N. & REBELL, G. - Mycetoma. *Arch. Derm.*, 99: 215-225. 1969.

Recebido para publicação em 23/07/1992
Aceito para publicação em 14/12/1992