

ACUTE DISSEMINATED HISTOPLASMOSIS AND ENDOCARDITIS

Pablo G. SCAPELLATO(1), Javier DESSE(1) & Ricardo NEGRONI(2)

SUMMARY

Acute disseminated histoplasmosis is a frequent condition in HIV carriers. Thirty-five cases of endocarditis caused by *Histoplasma capsulatum* have been reported in international literature, and all these descriptions correspond to a context of subacute disseminated histoplasmosis.

This paper presents the case of a HIV-positive patient with fever, dyspnea, weight loss, vomiting and polyadenopathies to whom histoplasmosis was diagnosed following blood-cultures and isolation of the agent responsible for cutaneous lesions, and in whom aortic-valve vegetations were found during an echocardiogram.

The patient was treated with amphotericin B and had a good outcome; subsequent echocardiograms showed no vegetations.

Literature on the subject is reviewed, with special emphasis on diagnosis and treatment of previously described cases.

KEYWORDS: Histoplasmosis in AIDS; Endocarditis; Mycotic endocarditis.

INTRODUCTION

Histoplasmosis frequently affects AIDS patients in areas where this mycosis is endemic. Endocardial involvement is rare, and up to the moment there are few reports (35 cases) on endocarditis caused by *Histoplasma capsulatum*.

CASE REPORT

A 24-year old man, HIV-positive, addict to intravenous drugs, was admitted to the Hospital F. J. Muñiz on April 10th 1994 with a thirty-days history of fever, dyspnoea, weight loss and vomiting.

He had a past history of psychiatric hospitalization six years before; positive HIV diagnosis had been made one year before and no controls of the disease had been performed.

Concerning his epidemiological background, he declared that he lived in Buenos Aires, in a poor socioeconomical environment, in two rooms, with another 9 persons, including a brother who suffered from chronic coughing. He had dogs, cats and birds at home. He had been in prison several times. On admission, he was thin, and his axillary temperature was 38°C (100°F).

He had multiple tattoos and scars. Multiple inguinal and cervical adenopathies were palpable. He presented "muguet" and a very poor dental condition. The patient had tachycardia and tachypnea. Respiratory examination revealed left-dominant, bibasal crepitan rales and disseminated rhonchus. Cardiovascular examination showed two sounds in four focuses with free silences. The liver was palpable three centimeters under the ribs edge. The remainder of the patient's physical examination disclosed no further abnormalities.

On April 15th an abdominal echography revealed no pathologic alterations. On April 18th tuberculosis treatment with isoniazide, rifampin, ethambutol and pirazinamide was empirically indicated, following obtention of blood culture samples for investigation of mycobacteria, fungi and usual organisms.

Later, axillary and supraclavicular adenopathies appeared and papulopustular lesions developed on the face (Fig. 1). Scrapping with Tzank cytodiagnosis and blood cultures yielded positive results for *Histoplasma capsulatum*. Amphotericin B (1 mg/kg/day) was added to the medication.

On May 2nd a routine echocardiography showed vegetations in the aortic valve without systolic function involvement (Fig. 2).

(1) Residents in Infectology. Hospital de Infecciosas F. J. Muñiz, Buenos Aires, Argentina.

(2) Chief of the Mycology Unit. Hospital de Infecciosas F. J. Muñiz, Buenos Aires, Argentina.

Correspondence to: Prof. Dr. Ricardo Negroni. Hospital F. J. Muñiz, Uspallata 2272, Capital Federal C.P.: 1228, Argentina.

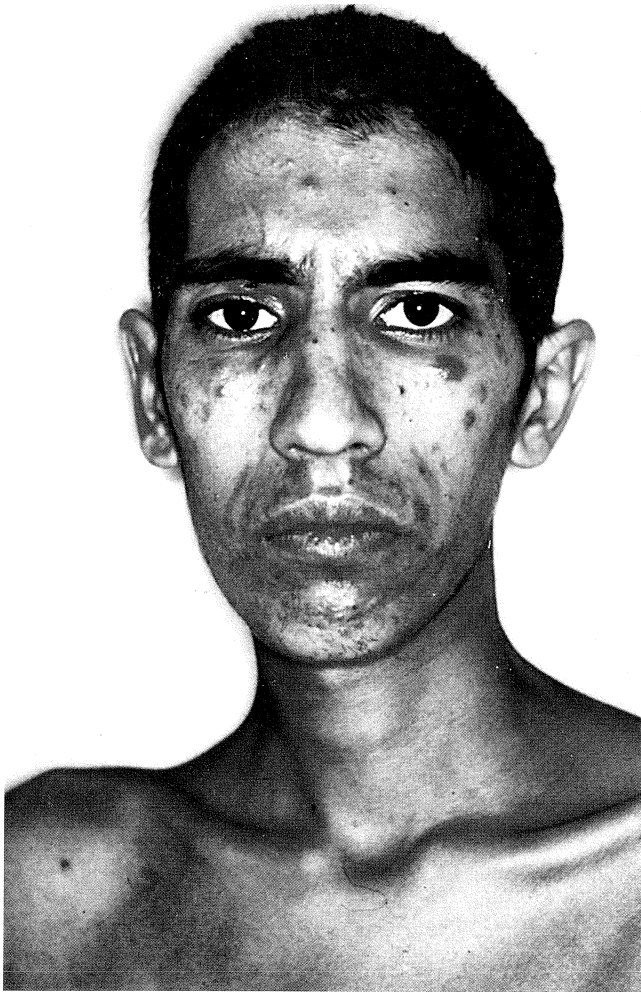

Fig. 1 – Skin papulopustular lesions on the face, due to *H. capsulatum*

The patient was afebrile, and cutaneous lesions had clearly improved. During hospitalization, the patient underwent both an episode of respiratory failure with no isolation of microbial agents, that was treated as a pneumocystosis, with cotrimoxazole, and an episode of nosocomial pneumonia in which *Streptococcus pneumoniae* was isolated from sputum, and treatment consisting in ceftriaxone for 14 days was indicated.

On June 22nd the patient was discharged, after 64 days of tuberculosis therapy, and with an accumulated amphotericin B dose of 1,770 mg. He was advised to continue on isoniazide and rifampicin and to make secondary prophylaxis with 50 mg of amphotericin B weekly.

The patient immediately discontinued the antituberculosis medication on his own decision, and he continued to attend controls and to receive amphotericin B weekly.

All the cultures performed during and before his hospitalization were negative for mycobacteria.

Three months later, the patient was asymptomatic and a control echocardiogram showed a neat reduction in vegetations size, an echocardiogram performed in November 1994 revealed no vegetations at all. The patient was treated up to December 1994 with weekly amphotericin B until he ceased to attend controls.

On April 1995 he was readmitted with caquexia and a picture of encefalopathy associated to HIV, and he died during hospitalization. This time, he presented no cutaneous lesions and mycological blood cultures were repeatedly negative.

DISCUSSION

Acute disseminated histoplasmosis, an evolutive form of infection by *Histoplasma capsulatum* affecting children and individuals with cell-mediated immunity impairment, is often diagnosed in AIDS patients in endemic areas³. Clinically, it manifests as a serious infectious process, with fever, weight loss, diarrhoea, hepatosplenomegaly, adenomegalies, pancytopenia and frequently, in Latin America, with cutaneous involvement⁸. Endocardial involvement has not been described in this sort of disease.

Endocarditis by *H. capsulatum* is an unusual condition^{2, 3, 5, 11} and, although it has been described as the third cause of mycotic endocarditis, only 35 cases have been reported in international literature^{5, 11}. This condition develops in the course of a subacute disseminated histoplasmosis³ and its evolution until diagnosis is, on average, of 9 months, with a range of 2 to 37 months².

Diagnosis of mycotic endocarditis is difficult, due to a high incidence of negative blood cultures⁶; for that reason, it is usually delayed.

Some authors think that positive blood culture is enough proof for its diagnosis⁶. According to Duke's criteria^{1, 4} our patient fulfilled two major criteria (positive blood cultures and typical echocardiographic images of valvular involvement) and two minor criteria (intravenous drug addiction and fever > 38°C), for the diagnosis of mycotic endocarditis due to *H. capsulatum*. However, we believe that these findings are not enough certain in this type of patients, since non infectious endocardic lesions are often found in intravenous drugs abusers and positive blood cultures are observed in more than 60% of cases suffering disseminated histoplasmosis associated with AIDS⁷ even though the majority of these patients do not present endocarditis. Consequently, Duke's criteria should be revised in drug addict patients suffering AIDS.

Histoplasma capsulatum can affect normal, diseased and prothetic valves, heart tumors and even atheromas¹¹, although a previous valvulopathy is present in 50% of cases². The aortic valve is the one most frequently involved (58%), followed by the mitral valve (31%) and the tricuspid valve (8%)².

Cardiovascular as well as NCS involvement are often associated with a fatal outcome^{9, 10}.

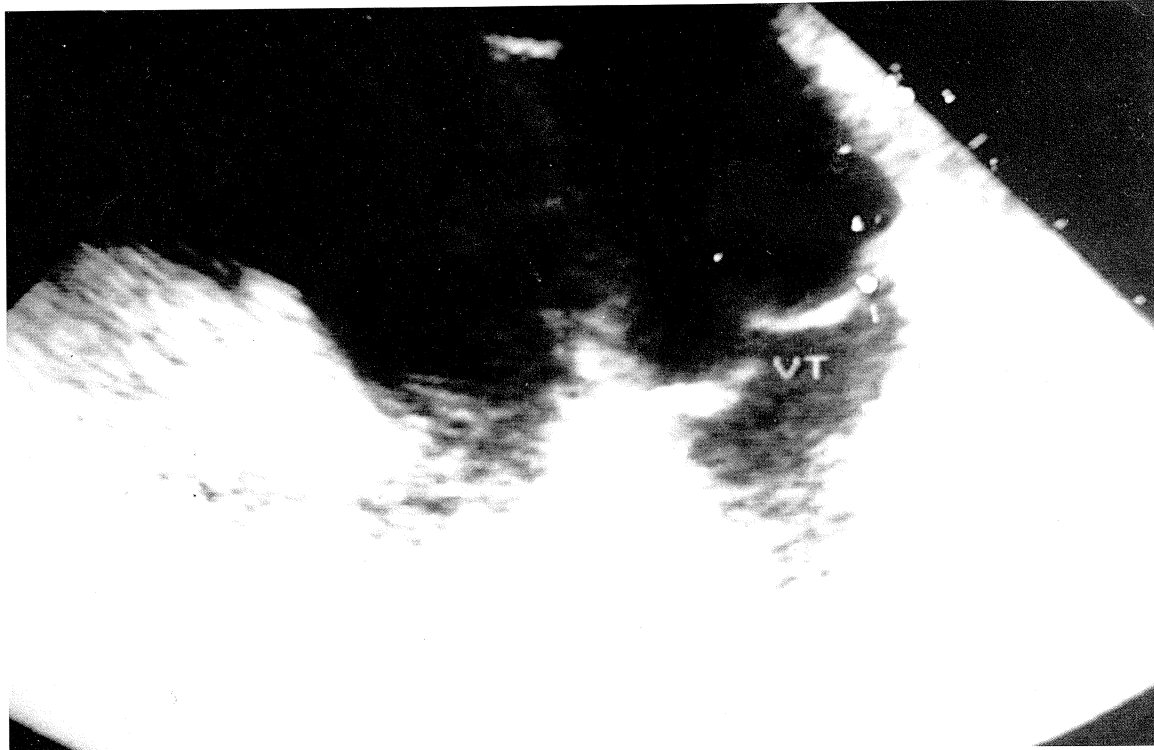


Fig. 2 - Echocardiography showing aortic vegetations

The greatest review on this subject⁵ includes 34 patients; 17 received no treatment and died; 9 were treated with amphotericin B – 4 recovered and 5 died –; and 7 received surgical treatment – 5 recovered and 2 died.

The optimum dose of amphotericin B has not yet been established; total doses reported by literature vary from 1.49 g to 7.4 g⁵.

Our patient received an accumulated dose of 1.77 g, and then he was put on a secondary-prophylactic dose of 50 mg/week, which he discontinued approximately 8 months after the onset of treatment.

Although it is impossible to talk of a cure in endocarditis caused by *Histoplasma capsulatum*^{5, 11}, echocardiographic controls showed that vegetations had disappeared; the patient died eleven months after the diagnosis, with a clinical picture apparently not related to histoplasmosis, and the presence of *Histoplasma capsulatum* could not be demonstrated in the cultures performed.

The serological follow-up, used by many authors to evidence outcome and cure¹¹, is scarcely valuable in AIDS patients^{8, 9}.

RESUMO

Histoplasmoze disseminada aguda e endocardite

Histoplasmoze disseminada aguda é uma entidade freqüente nos pacientes portadores do HIV.

Na literatura internacional foram descritos trinta e cinco casos de endocardite causada por *Histoplasma capsulatum*, sendo todas as descrições correspondentes a histoplasmoze disseminada subaguda.

Este artigo relata o caso de um paciente HIV positivo com febre, dispnea, perda de peso, vômitos e poliadenopatias, no qual foi diagnosticado histoplasmoze através de hemoculturas e isolamento do agente responsável das lesões cutâneas, e observadas vegetações na válvula aórtica durante uma ecocardiografia.

O doente foi tratado com anfotericina B com boa evolução e as ecocardiografias posteriores não mostraram vegetações.

Revisão da literatura sobre o tema foi realizada com ênfase especial quanto ao diagnóstico e tratamento dos casos anteriormente descritos.

REFERENCES

1. BAYER, A. S.; WARD, J. I.; GINTZTON, L. E. & SHAPIRO, S. M. – Evaluation of new clinical criteria for the diagnosis of infective endocarditis. *Amer J. Med.*, 96: 211-219, 1994.
2. BLAIR, T. & RAYMOND, L. – *Histoplasma capsulatum* endocarditis. *Chest*, 79: 620-621, 1981.
3. BULLOCK, W. E. – *Histoplasma capsulatum*. In: MANDELL, G. L.; BENNETT, J. E. & DOLIN, R., ed. *Mandell, Douglas & Bennett's principles and practice of infectious diseases*. 4. ed. New York, Churchill Livingstone, 1995. p. 2340-2353.

4. DURACK, D. T.; LUKES, A. S. & BRIGHT, D. K. – New criteria for diagnosis of infective endocarditis: utilization of specific echocardiographic findings. **Amer. J. Med.**, 96: 200-210, 1994.
5. KANAWATY, D. S.; STALKER, J. B. & MUNT, P. W. – Nonsurgical treatment of Histoplasma endocarditis involving bioprosthetic valve. **Chest**, 99: 253-256, 1991.
6. MOYER, D. V. & EDWARDS, J. E. – Fungal endocarditis. In: KAYE, D., ed. *Infective endocarditis*. 2. ed. New York, Raven Press, 1992. p. 301-306.
7. NEGRONI, R. – Avances en el diagnóstico de laboratorio de las micosis profundas. **Rev. argent. Micol.**, 1: 3-13, 1994.
8. NEGRONI, R. – Histoplasmosis. **Monogr. Derm.**, 7: 271-284, 1994.
9. NEGRONI BRIZ, R. – Histoplasmosis. In: TORRES RODRIGUEZ, J. M.; DEL PALACIO HERNANZ, A.; GUARRO ARTIGAS, J.; NEGRONI BRIZ, R. & PEREIRO MIGUENS, M., ed. *Micología médica*. Barcelona, M. Masson S. A., 1993. p. 247-255.
10. THERKELD, M. G. & COBBS, C. G. – Infectious disorders of prosthetic valves and intravascular devices. In: MANDELL, G. L.; BENNETT, J. E. & DOLIN, R., ed. – **Mandell, Douglas & Bennett's principles and practice of infectious diseases**. 4. ed. New York, Churchill Livingstone, 1995. p. 783-792.
11. WILMSHURST, P. T.; VENN, G. E. & EYKYN, S. J. – Histoplasma endocarditis on a stenosed valve presenting as dysphagia and weight loss. **Brit. Heart J.**, 70: 565-567, 1993.

Recebido para publicação em 23/05/1997

Aceito para publicação em 16/02/1998