

CASE REPORT

HEMOPHAGOCYtic SYNDROME ASSOCIATED WITH HEPATITIS A: CASE REPORT AND LITERATURE REVIEW

Felipe Francisco TUON(1), Virginia Soares GOMES(1), Valdir Sabbaga AMATO(2), Maria Esther GRAF(1), Guilherme Henrique Hencklain FONSECA(3), Carolina LAZARI(1) & Antonio Carlos NICODEMO(1)

SUMMARY

Virus-Associated Hemophagocytic Syndrome (VAHS) is a severe hematological disorder related to some viral infections. It is an illness characterized by persistent fever, pancytopenia, splenomegaly, hyperferritinemia and, the most important, hemophagocytosis observed in the bone marrow, liver and/or lymph nodes. VAHS associated with hepatitis A virus infection is rarely described, despite the high incidence of this viral infection in the population in general. There is no consensus in the literature regarding the optimal treatment of VAHS. In this article the clinical features, presumed pathogenesis, diagnostic criteria and treatment of VAHS are discussed, including description of cases of VAHS related to hepatitis A virus infection found in the medical literature.

KEYWORDS: Hemophagocytic syndrome; Hemophagocytosis; Viral-associated hemophagocytic syndrome; Hepatitis A virus; Intravenous immunoglobulin; Thrombocytopenia; Pancytopenia.

INTRODUCTION

Virus-Associated Hemophagocytic Syndrome (VAHS) is a severe hematological disorder related to some viral infections⁸. Among these viral infections, the most likely to be associated with VAHS are Epstein-Barr virus, cytomegalovirus, human herpesvirus type 6 (HHV-6) and HHV-8¹⁰. Nevertheless, some reports have described the association with human immunodeficiency virus (HIV), adenovirus, coxsackie virus, measles, dengue, rubella, parvovirus B19, herpes simplex virus and varicella zoster virus³⁹. Moreover, some cases of hemophagocytic syndrome have been reported in bacterial and protozoan infections^{16,21}.

VAHS was described by RISDALL *et al.* in 1979. He associated some hematological disorders with systemic viral infections in immunosuppressed patients which had clinical criteria of hemophagocytic syndrome³⁶. These diagnostic criteria were later reviewed by IMASHUKU and include persistent high fever, peripheral blood cytopenia (two or more series), hyperferritinemia, hyperlipidemia, and hemophagocytosis in the bone marrow (hemophagocytic cell ratio over 3%), spleen and/or lymph nodes⁵. All these diagnostic criteria should be present in a patient with an active viral infection to confirm the diagnosis of VAHS^{15,17}.

Hemophagocytic syndrome associated with hepatitis A virus

infection is rarely described, despite the high incidence of this infection in the population in general^{4,7,9,32,33,42,47}. There are only 12 cases reported in the medical literature.

The purpose of this manuscript is to describe a case of hepatitis A virus (HAV) infection, which developed into a VAHS and to review the literature on this matter.

CASE REPORT

A 24-year-old woman was hospitalized for the first time on October 15, 2006, complaining of nausea, vomiting, myalgia, jaundice, asthenia and fever. A diagnosis of acute hepatitis A was established based on the presence of specific IgM antibody anti-HAV. She was discharged from the hospital in better conditions. Thirty days later, all signs except jaundice were improved and she was admitted to another hospital with a diagnosis of severe anemia. Four blood units were transfused. After ten days she became febrile again and was admitted at the Hospital das Clínicas of University of São Paulo, Medical School.

The patient had presented severe jaundice and hepatosplenomegaly. Initial and further laboratory data are described in Table 1. Serology testing for toxoplasmosis, cytomegalovirus, rubella, EBV, hepatitis B and C, HIV and HTLV I/II were negative. Autoimmune hepatitis

(1) Department of Infectious and Parasitic Diseases, University of São Paulo Medical School, São Paulo, SP, Brazil.

(2) Infectious and Parasitic Diseases Clinic, Hospital das Clínicas, University of São Paulo Medical School, São Paulo, SP, Brasil.

(3) Department of Hematology, University of São Paulo Medical School, São Paulo, SP, Brazil.

Correspondence to: Dr. Antonio Carlos Nicodemo, Rua Barata Ribeiro, 414, Conjunto 104, 01308-000 São Paulo, SP, Brasil. Tel.: +55 11 32144251, Fax: +55 11 32591318. E-mail: ac_nicodemo@uol.com.br

Table 1
Laboratory findings in a patient with VAHS and HAV

Laboratory finding	25/Oct.	16/Nov.	4/Dec.
Hemoglobin (g/L)	6	9.5	9.2
leukocytes (cells/ μ L)	10,190	4,570	4,311
Platelets (no. $\times 10^3/\mu$ L)	307	132	183
Direct bilirubin (mg/dL)	24.5	6.45	0.8
Indirect bilirubin (mg/dL)	6.43	1.33	0.7
AST (U/L)	451	112	71
ALT (U/L)	350	116	97
Ferritin (ng/mL)	125,340	16,780	6,542
Reticulocytes (%)	0.22	8.12	5.22
Triglycerides (mg/dL)	555	-	212
C-reactive Protein (mg/L)	66	24	11
Lactate dehydrogenase (U/L)	5,679	1,356	632

antibodies were absent and the presence of IgM antibodies for hepatitis A was confirmed.

Ten days after admission, the patient still had fever and several blood units were required due to persistent severe anemia. A bone marrow aspiration was performed and hemophagocytosis was then diagnosed. Intravenous human immunoglobulin (IVIG) 400 mg/kg/day was prescribed for five days. After that, she did not require any further blood transfusion (Fig. 1). Despite the increased hemoglobin level, the patient developed a neutropenia ($600 \text{ cells}/\text{mm}^3$) which was successfully treated with G-CSF for three days. Three weeks later the patient was discharged without any complaints. She was in good health at the one year of follow-up.

DISCUSSION

The case here described has complied with all diagnostic criteria and, as far as we know, it is the first case of hemophagocytic syndrome associated with HAV infection in the Americas. Previous publications

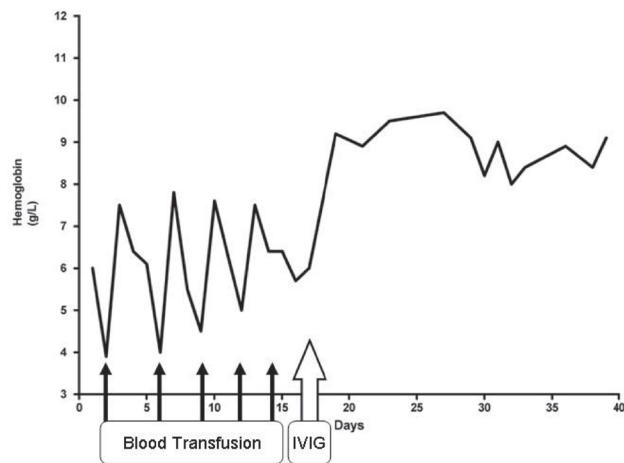


Fig. 1 - Level of hemoglobin following treatment of VAHS and HAV.

came from Japan, Taiwan and one case from England, totaling twelve cases related to VAHS and HAV infection^{18,23,24,30,34,40,48,49}. These manuscripts were found in the medical literature online on the LILACS, EMBASE, Web of Science and MEDLINE databases, including references from selected studies and case series of VAHS^{19,41}. Regarding these cases, some epidemiological and laboratorial findings are described in Table 2. Unfortunately, we were unable to describe three cases because they were published in Japanese language.

Leukocyte count is either normal or slightly low in the HAV infection and fever, in particular, rarely persists through the icteric phase, unless in atypical cases or if complication occurred^{27,46}. Hyperferritinemia is described in HAV infection, but not higher than 5,000 ng/mL. Hypertriglyceridemia can occur in several infectious diseases, including viral infections, but the levels usually do not exceed 500 mg/dL. Nevertheless, all previous clinical and laboratory features are uncommon in a later phase of HAV infection. These findings and hemophagocytosis in the bone marrow confirmed the diagnosis of VAHS in the case reported here.

Table 2
Cases published of hepatitis A associated with hemophagocytic syndrome

Author/Year	Country	Ref	Age/gender	Comorbidities	Lukocytes cells/ μ L	Hb (g/L)	Platelets no. $\times 10^3/\mu$ L	Date of cytopenia (after begin symptoms)	ALT IU/L	Total bilirubin mg/L	LDH IU/L	Ferritin ng/mL	Bone marrow
Tuon 2006	Brazil	-	24/F	None	10,190	6	307	10 days	340	30.9	5,679	125,340	+
Watanabe 2002	Japan	15	45/M	None	2,000	18.1	54	7 days	6,210	3.5	15,600	1,298	+
Watanabe 2002	Japan	15	41/M	HCV	3,700	16.9	88	7 days	2,661	3.0	2,882	5,801	+
Tai 2005	Taiwan	16	32/M	None	2,140	13.0	114	3 days	1,579	3.6	698	1,002	+
Wu 1995	Taiwan	17	23/M	HCV	7,800	4.2	40	14 days	355	31	-	-	+
Onaga 2000	Japan	14	19/F	None	2,800	14.9	97	4 days	11,510	4.0	20,210	66,096	+
Kyoda 1998	Japan	12	40/M	None	5,800	15.9	37	admission	2,000	1.6	3,482	4,652	+
McPeake 1993	England	13	20/F	Still's disease	2,900	6.9	18	> 6 days	119	9	-	-	+
Kondo 1995	Japan	11	49/F	None	0,500	5.9	32	12 days	600	17	800	?	+
Ishii 2002	Japan	10	37/M	Alcohol abuse	6,000	13.8	10	21 days	Normal	30	Normal	?	+

(Ref - reference; Hb - hemoglobin; ALT - alanine aminotransferase; LDH - lactate dehydrogenase; HCV - hepatitis C virus)

Thrombocytopenia is the most common cytopenia in VAHS with HAV infection, followed by leucopenia. Only one case presented anemia in the literature reviewed. Some previous reports describe aplastic anemia or pure red cell aplasia related to hepatitis A^{14,43}. These and other extrahepatic manifestations of HAV infection may be more common in patients who have protracted disease, such as relapsing or cholestatic hepatitis^{37,38}. Cholestatic form of HAV infection is usually characterized by marked jaundice, pruritus, fever, weight loss and diarrhea. Biochemical and serologic abnormalities typically show high levels of serum bilirubin and alkaline phosphatase, elevated serum cholesterol, mild elevation of serum aminotransferases and often show maintenance of the anti-HAV IgM. The symptoms and signs may last for three months or more before complete recovery. This scenario is similar to the case reported herein.

Neutropenia is found in these patients and it is a risk factor of infections. Recent reports support the safety of Granulocyte-Colony Stimulating Factor (G-CSF) in patients with VAHS and severe neutropenia^{3,23,44,45}. M-CSF is described as a trigger to the macrophage activation, increasing hemophagocytosis and worsening cytopenia^{11,12,35}. The possibility of G-CSF to increase the macrophage activation is not confirmed and it seems a useful drug to be used in patients with neutropenia due to VAHS.

The physiopathology of VAHS is established in the phagocytosis of blood cells precursors by macrophages^{2,22} (Fig. 2). KEREVEUR *et al.* described increasing expression of MHC class I and II molecules and increasing Macrophage-Colony Stimulating Factor (M-CSF) receptor expression in the macrophages²⁰. Phagocytosis of platelets may be enhanced due to the presence of antiplatelet immunoglobulin G. Nevertheless, WATANABE *et al.* verified the presence of phagocytosis of platelets in the bone marrow⁴⁸. Exaggerated activation of this group of cells may be due to high levels of activated cytokines, mainly of the inflammatory pattern. High levels of interferon- γ , interleukin-2 receptor, tumor necrosis factor- α , interleukin-1 and interleukin-6 have been demonstrated. This suggests that these cytokines produced by the T-helper cells promote macrophages activation³¹. The mechanism of abnormal cytokines production by these "hyperactivated" T lymphocytes remains unclear. Some authors explain this sustained activation by the persistence of antigens released by the

trigger infection. The maintenance of antigen expression can be an innate immune defect found in natural killer cells⁴⁶. Sometimes these cells can not destroy the infected cell by inducing apoptosis due to defect in the production of perforins or granzyme^{13,28}. In the case described herein, the persistent cholestasis of the HAV infection could support this concept⁴¹.

The prognosis of the VAHS is mainly based in the severity and duration of the cytopenias. Long-term neutropenia increases the risk of severe infections, including gram-positive bacteria, such as *S. aureus*. Thrombocytopenia should be cautiously observed because of the possibility of spontaneous bleeding, which can occur in the central nervous system as a fatal outcome. Anemia is a risk factor for infections and can promote organ dysfunctions, such as heart failure and tissue hypoxia. Despite of cytopenias, some cases of VAHS developed disseminated intravascular coagulation and fatal organic dysfunction due to severe sepsis, contributing to the mortality of more than 40% in the largest series⁶.

The treatment of VAHS is not well defined because there are no controlled studies, once this disease is not common⁴⁸. The supportive therapy consists of correcting the severe cytopenias and treating the causal infection.

The specific action of IVIG in the treatment of VAHS is not well-known²⁶. LARROCHE *et al.* in France evaluated nine cases of VAHS treated with IVIG and concluded that the treatment was effective and reduced the time of hemophagocytosis²⁵. However, more studies are necessary to verify the real efficacy of IVIG in the treatment of VAHS.

Some authors consider the immunosuppressive therapy a base to control hemophagocytosis. Although steroids have been commonly used in the treatment of VAHS, several reports showed failure⁴⁹. Pulse therapy with steroid has showed improvement in some reports¹. Plasmapheresis may be an alternative therapy in order to improve symptoms and laboratory abnormalities in the VAHS. Some reports have been successfully treated, including some cases after high doses of corticoid therapy²⁹.

More studies are necessary in order to clarify the physiopathology and the immune mechanisms involved in this life-threatening disease.

RESUMO

Síndrome hemofagocitária associada com hepatite A: relato de caso e revisão da literatura

A síndrome hemofagocitária associada a vírus é uma doença hematológica grave relacionada com algumas síndromes virais. É doença caracterizada por febre persistente, pancitopenia, esplenomegalia, hiperferritinemia e hemofagocitose na medula óssea, fígado e/ou linfonodos. A síndrome hemofagocitária associada ao vírus da hepatite A é raramente descrita, apesar da alta incidência desta infecção viral na população como um todo. Não existem consensos na literatura a respeito do tratamento desta morbidade. Neste artigo, os aspectos clínicos, patogênese, critérios diagnósticos e tratamento da síndrome hemofagocitária associada a vírus, incluindo a descrição de casos publicados da síndrome associada ao vírus da hepatite A.

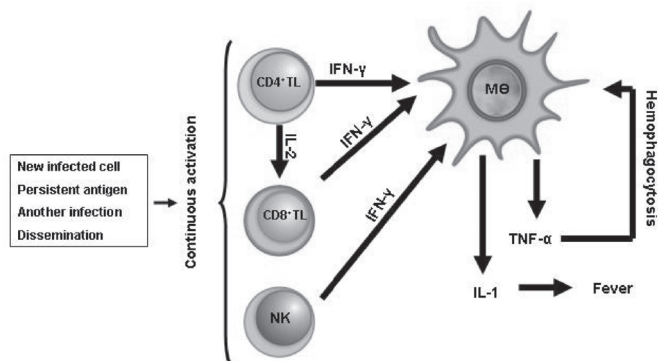


Fig. 2 - Schema of viral associated hemophagocytic syndrome. (NK - Natural killer cell; CD4+TL - Lymphocyte T CD4+; CD8+TL - Lymphocyte T CD8+; MΦ - Macrophage, IL-1 - Interleukin-1; IL-2 - Interleukin-2; IFN- γ - Interferon gamma; TNF- α - Tumor necrosis factor alpha.)

ACKNOWLEDGEMENTS

We thank Mariana Pinheiro by the clinical assistance. We thank Vivian Iida da Silva, Alan Brito Neves, Helena Petta, André Machado, André Siqueira Machado, Silvia Goulart, Juliana Yamashiro, Luciana Campos, Margarete Vicentine and Hermes Higashino by the clinical and laboratorial assistance.

REFERENCES

- AL-TALAG, A.H.; MOHAMED, A.E.; DAFULLA, M.M. *et al.* - Hemophagocytic syndrome. **Saudi med. J.**, 21: 979-982, 2000.
- ARICO, M.; DANESINO, C.; PENDE, D. & MORETTA, L. - Pathogenesis of haemophagocytic lymphohistiocytosis. **Brit. J. Haemat.**, 114: 761-769, 2001.
- AZUMA, E.; TABATA, N.; SHIBATA, T. *et al.* - G-CSF enhanced granulocyte production in a child with severe neutropenia in the setting of fatal virus-associated hemophagocytic syndrome. **Amer. J. Hemat.**, 35: 266-268, 1990.
- CASTRODALE, L.; FIORE, A. & SCHMIDT, T. - Detection of immunoglobulin M antibody to hepatitis A virus in Alaska residents without other evidence of hepatitis. **Clin. infect. Dis.**, 41: e86-e88, 2005.
- CHEN, C.J.; HUANG, Y.C.; JAING, T.H. *et al.* - Hemophagocytic syndrome: a review of 18 pediatric cases. **J. Microbiol. Immunol. Infect.**, 37: 157-163, 2004.
- DELLINGER, R.P. - Inflammation and coagulation: implications for the septic patient. **Clin. infect. Dis.**, 36: 1259-1265, 2003.
- DINELLI, M.I.; FISBERG, M. & MORAES-PINTO, M.I. - Anti-hepatitis A virus frequency in adolescents at an outpatient clinic in São Paulo, Brazil. **Rev. Inst. Med. trop. S. Paulo**, 48: 43-44, 2006.
- FAVARA, B.E. - Hemophagocytic lymphohistiocytosis: a hemophagocytic syndrome. **Semin. Diagn. Pathol.**, 9: 63-74, 1992.
- FIORE, A.E. - Hepatitis A transmitted by food. **Clin. infect. Dis.**, 38: 705-715, 2004.
- FISMAN, D.N. - Hemophagocytic syndromes and infection. **Emerg. infect. Dis.**, 6: 601-608, 2000.
- FRANÇOIS, B.; TRIMOREAU, F.; DESACHY, A. *et al.* - Hemophagocytosis during multiple organ failure: M-CSF overproduction or viral reactivation? **Ann. Franç. Anesth. Reanim.**, 20: 514-519, 2001.
- FRANÇOIS, B.; TRIMOREAU, F.; VIGNON, P. *et al.* - Thrombocytopenia in the sepsis syndrome: role of hemophagocytosis and macrophage colony-stimulating factor. **Amer. J. med.**, 103: 114-120, 1997.
- GROSSMAN, W.J.; VERBSKY, J.W.; TOLLEFSEN, B.L. *et al.* - Differential expression of granzymes A and B in human cytotoxic lymphocyte subsets and T regulatory cells. **Blood**, 104: 2840-2848, 2004.
- GUNDERSEN, S.G.; BJOERNEKLETT, A. & BRUUN, J.N. - Severe erythroblastopenia and hemolytic anemia during a hepatitis A infection. **Scand. J. infect. Dis.**, 21: 225-228, 1989.
- HENTER, J.I.; HORNE, A.; ARICO, M. *et al.* - HLH-2004: diagnostic and therapeutic guidelines for hemophagocytic lymphohistiocytosis. **Pediat. Blood Cancer**, 48: 124-131, 2007.
- HEYDARI, A.A.; AHMADI, F.; SARVGHAD, M.R. *et al.* - Hemophagocytosis and pulmonary involvement in brucellosis. **Int. J. infect. Dis.**, 11: 89-90, 2007.
- IMASHUKU, S. - Advances in the management of hemophagocytic lymphohistiocytosis. **Int. J. Hemat.**, 72: 1-11, 2000.
- ISHII, H.; YAMAGISHI, Y.; OKAMOTO, S. *et al.* - Hemophagocytic syndrome associated with fulminant hepatitis A: a case report. **Keio J. med.**, 52: 38-51, 2003.
- KAITO, K.; KOBAYASHI, M.; KATAYAMA, T. *et al.* - Prognostic factors of hemophagocytic syndrome in adults: analysis of 34 cases. **Europ. J. Haemat.**, 59: 247-253, 1997.
- KEREVEUR, A.; MCILROY, D.; SAMRI, A. *et al.* - Up-regulation of adhesion and MHC molecules on splenic monocyte/macrophages in adult haemophagocytic syndrome. **Brit. J. Haemat.**, 104: 871-877, 1999.
- KILANI, B.; AMMARI, L.; KANOUN, F. *et al.* - Hemophagocytic syndrome associated with visceral leishmaniasis. **Int. J. infect. Dis.**, 10: 85-86, 2006.
- KOMP, D.M.; McNAMARA, J. & BUCKLEY, P. - Elevated soluble interleukin-2 receptor in childhood hemophagocytic histiocytic syndromes. **Blood**, 73: 2128-2132, 1989.
- KONDO, H. & DATE, Y. - Effects of simultaneous rhG-CSF and methylprednisolone "pulse" therapy on hepatitis A virus-associated haemophagocytic syndrome. **Europ. J. Haemat.**, 54: 271-273, 1995.
- KYODA, K.; NAKAMURA, S.; MACHI, T. *et al.* - Acute hepatitis A virus infection-associated hemophagocytic syndrome. **Amer. J. Gastroent.**, 93: 1187-1188, 1998.
- LARROCHE, C.; BRUNEEL, F.; ANDRE, M.H. *et al.* - Intravenously administered gamma-globulins in reactive hemophagocytic syndrome. Multicenter study to assess their importance, by the immunoglobulins group of experts of CEDIT of the AP-HP. **Ann. med. interne (Paris)**, 151: 533-539, 2000.
- LARROCHE, C. & MOUTHON, L. - Pathogenesis of hemophagocytic syndrome (HPS). **Autoimmun. Rev.**, 3: 69-75, 2004.
- MAJLUF-CRUZ, A.; SOSA-CAMAS, R.; PEREZ-RAMIREZ, O. *et al.* - Hemophagocytic syndrome associated with hematological neoplasias. **Leukemia Res.**, 22: 893-898, 1998.
- MANCEBO, E.; ALLENDE, L.M.; GUZMAN, M. *et al.* - Familial hemophagocytic lymphohistiocytosis in an adult patient homozygous for A91V in the perforin gene, with tuberculosis infection. **Haematologica**, 91: 1257-1260, 2006.
- MATSUMOTO, Y.; NANIWA, D.; BANNO, S. & SUGIURA, Y. - The efficacy of therapeutic plasmapheresis for the treatment of fatal hemophagocytic syndrome: two case reports. **Ther. Apher.**, 2: 300-304, 1998.
- McPEAKE, J.R.; HIRST, W.J.; BRIND, A.M. & WILLIAMS, R. - Hepatitis A causing a second episode of virus-associated haemophagocytic lymphohistiocytosis in a patient with Still's disease. **J. med. Virol.**, 39: 173-175, 1993.
- MUROHASHI, I.; YOSHIDA, K.; IHARA, N. *et al.* - Serum levels of Th1/Th2 cytokines, angiogenic growth factors, and other prognostic factors in young adult patients with hemophagocytic syndrome. **Lab. Hemat.**, 12: 71-74, 2006.
- MUTSCH, M.; SPICHER, V.M.; GUT, C. & STEFFEN, R. - Hepatitis A virus infections in travelers, 1988-2004. **Clin. infect. Dis.**, 42: 490-497, 2006.
- NELSON, K.E. - Global changes in the epidemiology of hepatitis A virus infections. **Clin. infect. Dis.**, 42: 1151-1152, 2006.
- ONAGA, M.; HAYASHI, K.; NISHIMAGI, T. *et al.* - A case of acute hepatitis A with marked hemophagocytosis in bone marrow. **Hepat. Res.**, 17: 205-211, 2000.
- PRALORAN, V. & MECHINAUD-LACROIX, F. - Production and role of macrophage colony stimulating factor (CSF-1 or M-CSF) in hematological pathology. **Nouv. Rev. franç. Hémat.**, 35: 227-229, 1993.
- RISDALL, R.J.; McKENNA, R.W.; NESBIT, M.E. *et al.* - Virus-associated hemophagocytic syndrome: a benign histiocytic proliferation distinct from malignant histiocytosis. **Cancer**, 44: 993-1002, 1979.

37. SCHIFF, E.R. - Atypical clinical manifestations of hepatitis A. **Vaccine**, 10 (suppl. 1): S18-S20, 1992.
38. SHENOY, R.; NAIR, S. & KAMATH, N. - Thrombocytopenia in hepatitis A: an atypical presentation. **J. trop. Pediat.**, 50: 241-242, 2004.
39. SHIRONO, K. & TSUDA, H. - Virus-associated haemophagocytic syndrome in previously healthy adults. **Europ. J. Haemat.**, 55: 240-244, 1995.
40. TAI, C.M.; LIU, C.J. & YAO, M. - Successful treatment of acute hepatitis A-associated hemophagocytic syndrome by intravenous immunoglobulin. **J. Form. med. Ass.**, 104: 507-510, 2005.
41. TAKAHASHI, N.; CHUBACHI, A.; KUME, M. *et al.* - A clinical analysis of 52 adult patients with hemophagocytic syndrome: the prognostic significance of the underlying diseases. **Int. J. Hemat.**, 74: 209-213, 2001.
42. TAYLOR, R.M.; DAVERN, T.; MUNOZ, S. *et al.* - Fulminant hepatitis A virus infection in the United States: incidence, prognosis, and outcomes. **Hepatology**, 44: 1589-1597, 2006.
43. TOMIDA, S.; MATSUZAKI, Y.; NISHI, M. *et al.* - Severe acute hepatitis A associated with acute pure red cell aplasia. **J. Gastroent.**, 31: 612-617, 1996.
44. TSUDA, H.; MAEDA, Y.; NAKAGAWA, K. *et al.* - Parvovirus B19-associated haemophagocytic syndrome with prominent neutrophilia. **Brit. J. Haemat.**, 86: 413-414, 1994.
45. TSUDA, H. & SHIRONO, K. - Successful treatment of virus-associated haemophagocytic syndrome in adults by cyclosporin A supported by granulocyte colony-stimulating factor. **Brit. J. Haemat.**, 93: 572-575, 1996.
46. VERBSKY, J.W. & GROSSMAN, W.J. - Hemophagocytic lymphohistiocytosis: diagnosis, pathophysiology, treatment, and future perspectives. **Ann. med.**, 38: 20-31, 2006.
47. VITRAL, C.L.; GASPAR, A.M. & SOUTO, F.J. - Epidemiological pattern and mortality rates for hepatitis A in Brazil, 1980-2002: a review. **Mem. Inst. Oswaldo Cruz**, 101: 119-127, 2006.
48. WATANABE, M.; SHIBUYA, A.; OKUNO, J. *et al.* - Hepatitis A virus infection associated with hemophagocytic syndrome: report of two cases. **Intern. med.**, 41: 1188-1192, 2002.
49. WU, C.S.; CHANG, K.Y.; DUNN, P. & LO, T.H. - Acute hepatitis A with coexistent hepatitis C virus infection presenting as a virus-associated hemophagocytic syndrome: a case report. **Amer. J. Gastroent.**, 90: 1002-1005, 1995.

Received: 14 August 2007

Accepted: 2 January 2008