

## CASE REPORT

### ANAL SQUAMOUS CARCINOMA: A NEW AIDS-DEFINING CANCER? CASE REPORT AND LITERATURE REVIEW

Marcelo CORTI(1), María F. VILLAFANE(1), Esteban MARONA(2) & Daniel LEWI(3)

---

#### SUMMARY

Squamous anal cell carcinoma is a rare malignancy that represents the 1.5% to 2% of all the lower digestive tract cancers. However, an increased incidence of invasive anal carcinoma is observed in HIV-seropositive population since the widespread of highly active antiretroviral therapy. Human papillomavirus is strongly associated with the pathogenesis of anal cancer. Anal intercourse and a high number of sexual partners appear to be risk factors to develop anal cancer in both sexes. Anal pain, bleeding and a palpable lesion in the anal canal are the most common clinical features. Endo-anal ultrasound is the best diagnosis method to evaluate the tumor size, the tumor extension and the infiltration of the sphincter muscle complex. Chemoradiotherapy plus antiretroviral therapy are the recommended treatments for all stages of localized squamous cell carcinoma of the anal canal in HIV-seropositive patients because of its high rate of cure. Here we present an HIV patient who developed a carcinoma of the anal canal after a long time of HIV infection under highly active antiretroviral therapy with a good virological and immunological response.

**KEYWORDS:** Squamous anal cell carcinoma; Human papillomavirus; HIV; AIDS; Antiretroviral therapy; HAART.

---

#### INTRODUCTION

Anal intraepithelial neoplasm (AIN) and squamous anal cell carcinoma (SACC) are uncommon malignancies that represent the 1.5% to 2% of all digestive tract cancers<sup>9</sup>. However, in the last two decades, the incidence of SACC has increased in relation with the human immunodeficiency virus (HIV) infection, especially in men who have sex with men (MSM). In addition, patients with a longer history of HIV infection (> 15 years) have a 12-fold higher rate of SACC in comparison with those who have < 5 years<sup>5</sup>. Although the screening for AIN and the vaccination against human papillomavirus (HPV) oncogenic subtypes may reduce the risk for development of anal cancer, at present, these neoplasms remain as a significant comorbidity in HIV/AIDS patients.

Here, we present a patient with AIDS who develop an SACC after a long time history of HIV infection and under highly active antiretroviral therapy (HAART).

#### CASE REPORT

A 58-year-old homosexual male with diagnosis of HIV infection since 1986 was referred to our HIV-AIDS Division because he presented anal pain and several episodes of proctorrhagia. Anal examination showed

multiple lesions compatible with condyloma acuminatum (anogenital warts). A digital examination was performed and detected an intra-anal indurated lesion. The 3D endo-rectal ultrasonography demonstrated the presence of an intra-anal lesion of 3 cm x 1 cm of diameters that involve the anal sphincter muscle. Abdominal computed tomography was negative to detect prerectal, internal iliac or inguinal adenopathies (T3N0) (Fig. 1). A videocolonoscopy was made and multiple biopsy smears of the lesion were performed. Histopathological examination revealed anal mucosae with preservation of squamous epithelium and regular number of koilocytes (Fig. 2). In other area, a proliferation of atypical cells that infiltrate the stromal was observed (Fig 3). Final histopathological diagnosis was squamous cell carcinoma in the anal canal. At the time of neoplasm diagnosis, the plasma viral load was undetectable (< 20 copies/mL) and the CD4 T-cell count was 373 cell/ $\mu$ L.

He was treated with the combination of HAART based on tenofovir plus darunovir boosted with ritonavir and raltegravir, three dimensional radiotherapy and chemotherapy according with Nigro scheme (5-Fluoruracil + Mitomycin C). During the first three months of chemotherapy, the patient presented a reduction of CD4 T-cell count below 200 cell/ $\mu$ L but there were no changes in the HIV viral load that remained undetectable. A new 3D endo-rectal ultrasound was performed after treatment and showed the resolution of the tumoral mass with the

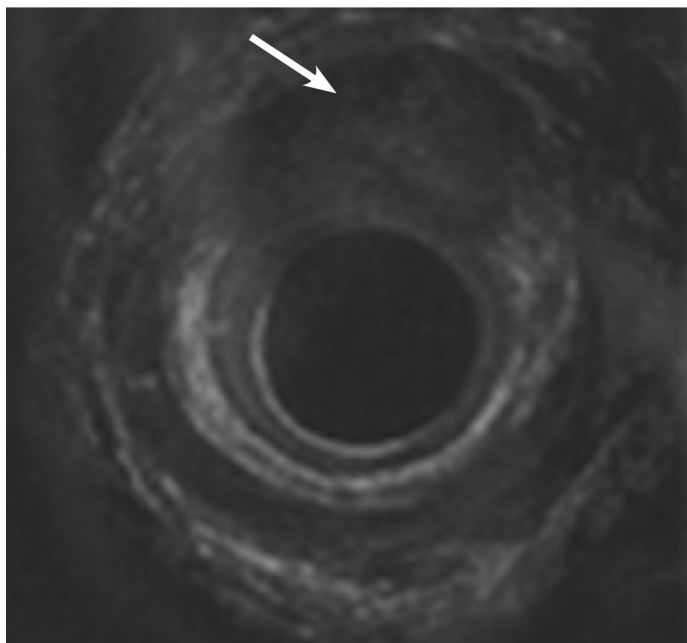
---

(1) Division of HIV/AIDS, Infectious Diseases F. J. Muñiz Hospital, Buenos Aires, Argentina.

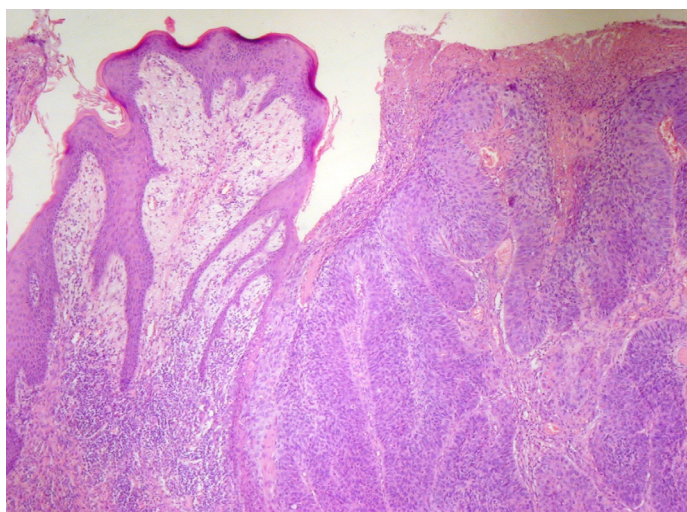
(2) Histopathology Laboratory, Infectious Diseases F. J. Muñiz Hospital, Buenos Aires, Argentina.

(3) Oncology Unit, Fernández J. A. General Hospital, Buenos Aires, Argentina.

**Correspondence to:** Marcelo Corti, Puán 381, 2° C1406CQG, Buenos Aires, Argentina. E-mail: marcelocorti@fibertel.com.ar



**Fig. 1** - 3D endo-rectal ultrasonography demonstrated the presence of an intra-anal lesion of 3 cm x 1 cm of diameters that involve the anal sphincter muscle. (arrow)

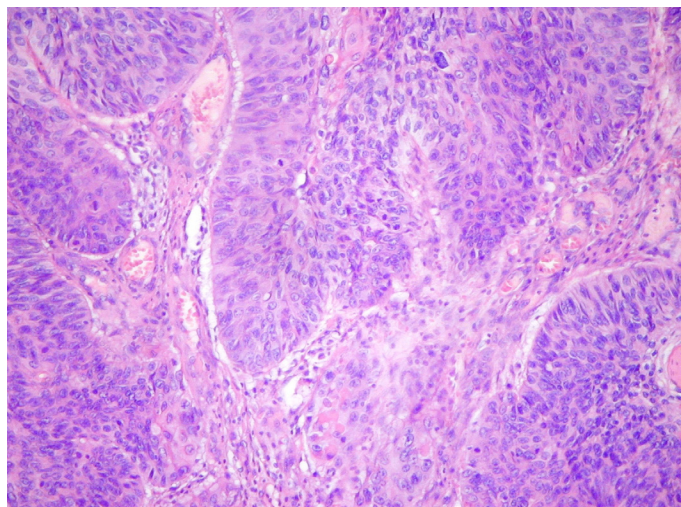


**Fig. 2** - Hematoxylin-eosin staining of tissue (40X): infiltrating sheets and islands of squamous epithelium surrounded by fibrous connective tissue with chronic inflammatory cell infiltrate.

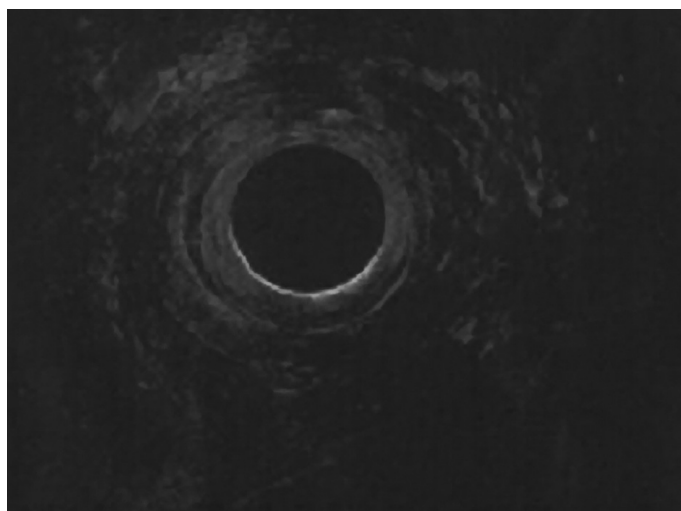
normal aspect of both sphincters (Fig. 4). After 18 months of follow-up the patient is still in a good clinical condition, with undetectable viral load (< 20 copies/mL) and CD4 T-cell count > 200 cell/ $\mu$ L.

## DISCUSSION

Anal cancer may arise from the anal canal or from the anal margin; 85% of the anal cancers involve the anal canal and the remaining 15% occur on the anal margin. Anal carcinomas are characterized by aggressive local invasion including the infiltration of the sphincter muscle. In contrast, the tumors originated in the peri-anal skin have a



**Fig. 3** - Hematoxylin-eosin staining of biopsy smear (100X): islands of squamous tumor cells with nuclear pleomorphism and keratin formation.



**Fig. 4** - Normal aspect of 3D endo-rectal ultrasonography after treatment.

better prognosis and their evolution is similar to other skin cancers<sup>3</sup>. Anal cancer is much more frequent in HIV-positive MSM in comparison with HIV-seronegative persons<sup>13</sup>. Some evidences suggest that male partners may be a reservoir for high-risk HPV subtypes, probably located in penile lesions. HPV infection is highly prevalent in sexually active men and HPV-16 seems to be the most common subtype detected in anal lesions. The prevalence of HPV-16 in this population range from 73% to 93%<sup>2</sup>. Additionally, multiple subtypes of infection are more frequent in men than in women<sup>7</sup>.

One of the most important risk factors for HPV infection in homosexual men is the HIV coinfection. The probability to develop anal cancer has been reported as two to 14 times higher in HIV-positive MSM in comparison with those who are HIV-negative<sup>20</sup>. Anal cancer presents a higher incidence than other HPV-related genital cancers as vulvar, vaginal or penile tumors<sup>20</sup>. Between 1973 and 2004, the rate of anal cancer increased in the United States from 0.5 to 1.3 per 100,000<sup>12</sup>. Finally, anal cancer is also frequent in women that practice receptive anal intercourse.

The relation between anal cancer and receptive anal intercourse is similar in both sexes and is independent of immunosuppression<sup>11</sup>.

As other non-AIDS defining malignancies, as lung cancer, Hodgkin's disease and liver carcinoma, the incidence of AIN and SACC does not seem to correlate with the CD4 T-cell counts<sup>8</sup>. Additionally, the risk of anal cancer not decline with the widespread of HAART<sup>15</sup>. High-grade of AIN is the precursor lesion to anal cancer similar to cervical intraepithelial neoplasia (CIN) and cervical cancer<sup>3</sup>.

Clinical presentation of anal cancer in HIV-seropositive patients does not differ substantially with the general population<sup>10</sup>. Anal pain, anal fissure or fistulae, diarrhea, bleeding and exophytic verrucous anal and intra-anal infiltrative lesions are the most common clinical manifestations. The presence of these clinical manifestations should be carefully evaluated, especially in those patients that refer anal pain, including the examination under anesthesia and multiple biopsy smears should be obtained.

When the patients refer rectal tenesmus or painful defecation, the clinician should suspect the probable infiltration of the sphincter muscle<sup>4</sup>.

A careful histopathological examination of the biopsy smears is very important in these kind of patients; in this aspect, it is important to arise the regional extension of the tumor and the histopathological grade that is based on the same criteria used for CIN from normal, AIN-1, AIN-2, AIN-3 or carcinoma *in situ*<sup>10,18</sup>. Tumors longer than 5 cm in diameter (T3) and with metastases in regional lymph nodes (N1-3) have an increased risk for recurrence after chemoradiation<sup>3</sup>. Endo-anal ultrasound represents the better diagnosis method to determine the grade of tumor infiltration and to evaluate the involvement of the sphincter muscle complex, as we can see in our patient.

HPV play an important role in the pathogenesis of both CIN and AIN, and HPV DNA was found in many anal cancers biopsy smears<sup>14,15</sup>.

Predictive factors to develop AIN-2, AIN-3 or anal carcinoma in HIV positive patients include the infection by HPV oncogenic subtypes, especially HPV 16 and the infection due to multiple subtypes of HPV<sup>6,8,13</sup>.

Although HAART reduce the incidence of opportunistic infections and AIDS-defining cancers, the incidence of SACC is increasing since the widespread use of antiretroviral therapy<sup>8</sup>. The cumulative incidence of AIN-2, 3 in a two large cohort studies was 37% and 34%, respectively, over a three and four-year period of follow up<sup>1,13</sup>. PALEFSKY *et al.*<sup>14</sup> demonstrate that the use of HAART does not provide a greater protection against AIN and for other malignancies related with HPV as CIN. In the majority of the cases, the standard treatment for AIDS-associated anal cancer is based on chemoradiotherapy regimen with 5-fluoruracil (5FU) and mitomycin (MMC) named as Nigro scheme and three dimensional radiotherapy, as we use in our patient<sup>1,19</sup>. SEO *et al.*<sup>17</sup> reported that the combination of HAART and chemoradiotherapy is as safe and effective for immunodeficient and immunocompetent patients. Anal cancer is usually curable. The three major prognostic factors are the site (anal canal vs. perianal skin), the size (primary tumors < 2 cm in size have better prognosis), and the nodal status.

VATRA *et al.*<sup>19</sup> compared 20 HIV-positive patients with diagnosis

of SACC with 24 HIV-negative subjects. Survival rates at one year after chemoradiotherapy with preserved anal sphincter was significantly higher in the HIV-negative group (88%) in comparison with the HIV-positive patients (45%) ( $p < 0.05$ ). At three years, the median survival in the HIV-seropositive group was 18 months, significantly shorter than the 28 months observed in the HIV-negative ( $p < 0.001$ ). Also, in this study, the CD4 T cell count for less than 250 cell/ $\mu$ L at the time of neoplasm diagnosis was a predictive factor of poor prognosis and a shorter survival.

In conclusion, we consider that SACC should be included as an AIDS-defining illness based on the high rate incidence in this population. A better prognosis is related with the early diagnosis and the treatment based on the combination of HAART plus chemoradiotherapy.

## RESUMO

### Carcinoma de células escamosas do canal anal: a nova neoplasia associada com AIDS?

O carcinoma de células escamosas do canal anal é uma malignidade rara que representa 1,5% a 2% de todos os cânceres do trato gastrointestinal inferior. Entretanto, é observada uma incidência aumentada do carcinoma anal invasivo, na população soropositiva para o HIV desde a difusão da terapia antirretroviral altamente ativa. O vírus do papiloma está fortemente associado com a patogênese do câncer anal. Sexo anal e um alto número de parceiros sexuais parecem ser os fatores de risco para desenvolver câncer anal em ambos os sexos. Dor anal, sangramento e lesão palpável no canal anal são as manifestações clínicas mais comuns. O ultrassom endoanal é o melhor método diagnóstico para avaliar o tamanho do tumor, sua extensão e a infiltração para o complexo do músculo esfíncteriano. A quimioradioterapia mais terapia antirretroviral é o tratamento recomendado para todos os estádios do carcinoma localizado de células escamosas do canal anal nos pacientes HIV soropositivos, devido a sua alta taxa de cura. Apresentamos um paciente que desenvolveu carcinoma do canal anal depois de um longo tempo de infecção por HIV sob tratamento com a terapia antirretroviral altamente ativa, com boa resposta virológica e imunológica.

## REFERENCES

1. Alfa-Wali M, Allen-Mersh T, Antoniou A, Tait D, Newsom-Davis T, Gazzard B, *et al.* Chemoradiotherapy for anal cancer in HIV patients causes prolonged CD4 cell count suppression. *Ann Oncol.* 2012;23:141-7.
2. Bruland O, Fluge O, Immervoll H, Balteskard L, Myklebust M, Skarstein A, *et al.* Gene expression reveals two distinct groups of anal carcinomas with clinical implications. *Br J Cancer.* 2008;98:1264-73.
3. Buchs NC, Allal AS, Morel P, Gervaz P. Prevention chemoradiation and surgery for anal cancer. *Expert Rev Anticancer Ther.* 2009;9:483-9.
4. Corman ML. Malignant tumors of the anal canal. In: *Colon & Rectal Surgery.* 4<sup>th</sup> ed. Philadelphia: Lippincott-Raven; 1998. p. 863-83.
5. Crum-Cianflone NF, Hullsiek KH, Marconi VC, Ganesan A, Weintrob A, Barthel RV, *et al.* Anal cancers among HIV-infected persons: HAART is not slowing rising incidence. *AIDS.* 2010;24:535-43.
6. de Pokomandy A, Rouleau D, Ghattas G, Trotter H, Vézina S, Coté P, *et al.* HAART and progression to high-grade anal intraepithelial neoplasia in men who have sex with men and are infected with HIV. *Clin Infect Dis.* 2011;52:1174-81.

7. Dunne EF, Nielson CM, Stone KM, Markowitz LE, Giuliano AR. Prevalence of HPV infection among men: a systematic review of the literature. *J Infect Dis*. 2006;194:1044-57.
8. Frisch M, Biggar RJ, Goedert JJ. Human papillomavirus-associated cancer patients with human immunodeficiency virus infection and acquired immunodeficiency syndrome. *J Natl Cancer Inst*. 2000;92:1500-10.
9. Jemal A, Siegel R, Ward E, Murray T, Xu J, Thun MJ. Cancer statistics, 2007. *CA Cancer J Clin*. 2007;57:43-66.
10. Lorenz HP, Wilson W, Leigh B, Crombleholme T, Schecter W, *et al*. Squamous cell carcinoma of the anus and HIV infection. *Dis Colon Rectum*. 1991;34:336-8.
11. Moscicki AB, Hillas NK, Shiboski S, Darragh TM, Jay N, Powell K, *et al*. Risk factors for abnormal anal cytology in young heterosexual women. *Cancer Epidemiol Biomarkers Prev*. 1999;8:173-8.
12. Nyitray A, Nielson CM, Harris RB, Flores R, Abrahamsen M, Dunne EF, *et al*. Prevalence of and risk factors for anal human papillomavirus infection in heterosexual men. *J Infect Dis*. 2008;197:1676-84.
13. Palefsky JM, Holly EA, Efirde JT, Da Costa M, Jay N, Berry JM, *et al*. Anal intraepithelial neoplasia in the highly active antiretroviral therapy era among HIV-positive men who have sex with men. *AIDS*. 2005;19:1407-14.
14. Palefsky JM, Holly EA, Ralston ML, Jay N, Berry JM, Darragh TM. High incidence of anal high-grade squamous intra-epithelial lesions among HIV-positive and HIV-negative homosexual and bisexual men. *AIDS*. 1998;12:495-503.
15. Patel P, Hanson DL, Sullivan PS, Novak RM, Moorman AC, Tong TC, *et al*. Incidence of types of cancer among HIV-infected persons compared with the general population in the United States, 1992-2003. *Ann Intern Med*. 2008;148:728-36.
16. Powles T, Robinson D, Stebbing J, Shamash J, Nelson M, Gazzard B, *et al*. Highly active antiretroviral therapy and the incidence of non-AIDS-defining cancers in people with HIV infection. *J Clin Oncol*. 2009;27:884-90.
17. Seo Y, Kinsella M, Reynolds HL, Chipman G, Remick SC, Kinsella TJ. Outcomes of chemotherapy with 5-fluorouracil and mitomycin C for anal cancer in immunocompetent versus immunodeficient patients. *Int J Radiat Oncol Biol Phys*. 2009;75:143-9.
18. Severini A. Anal intraepithelial neoplasia in men living with HIV in the era of highly active antiretroviral therapy. *Clin Infect Dis*. 2011;52:1182-3.
19. Vatra B, Sobhani I, Aparicio T, Girard PM, Puy Montbrun TD, Housset M, *et al*. Caractéristiques cliniques, thérapeutiques et pronostiques des carcinomes épidermoïdes du canal anal chez les maladies VIH positifs. *Gastroenterol Clin Biol*. 2001;25:150-6.
20. Zbar AP, Fenger C, Efron J, Beer-Gabel M, Wexner SD. The pathology and molecular biology of anal intraepithelial neoplasia: comparisons with cervical and vulvar intraepithelial carcinoma. *Int J Colorectal Dis*. 2002;17:203-15.

Received: 3 May 2012

Accepted: 5 June 2012