

## CASE REPORT

# HISTOPLASMOSIS PRESENTING WITH MULTIPLE PULMONARY NODULES. A CASE MIMICKING RADIOLOGICAL FEATURES OF PULMONARY METASTASIS

Aline Gehlen DALL BELLO(1), Cecília Bittencourt SEVERO(2), Flávio de Mattos OLIVEIRA(2), Ramon Joaquim HALLAL JUNIOR(3), Bruno HOCHHERGGER(4) & Luiz Carlos SEVERO(2,5)

### SUMMARY

We present a case of histoplasmosis with multiple pulmonary nodules in a patient with a history of melanoma. This case closely simulated malignancy, including the presence of feeding vessel sign, which occurs in pulmonary metastasis. We emphasize the need to be aware of this infection in areas where histoplasmosis is endemic.

**KEYWORDS:** Histoplasmosis; *Histoplasma capsulatum*; Pulmonary nodules; Metastatic lesions.

### INTRODUCTION

Classic histoplasmosis, a granulomatous disease caused by the dimorphic fungus *Histoplasma capsulatum* var. *capsulatum* (*H. capsulatum*), is endemic in certain areas of North and Latin America<sup>9</sup>. Brazil is an area of higher prevalence of cases<sup>13</sup>.

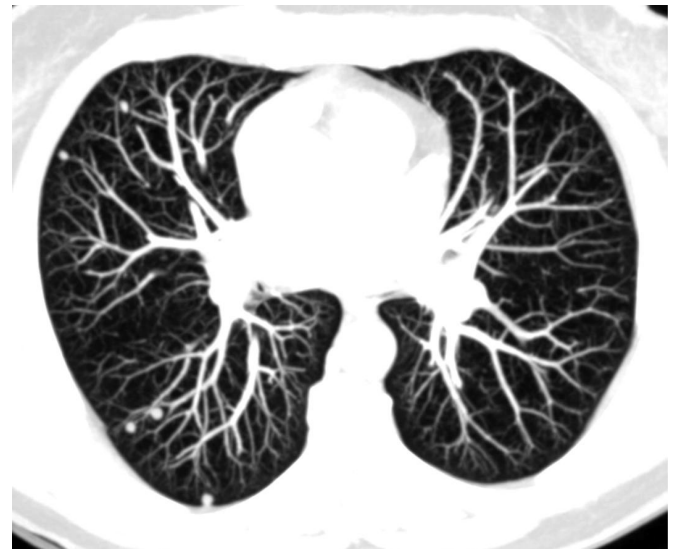The vast majority of infections with *H. capsulatum* are completely asymptomatic or, at least, subclinical. The disease is resolved spontaneously over a period of 2-4 weeks. The roentgenographic signs are resolved completely in 2-4 months or leave calcified hilar and/or mediastinal lymph nodes or pulmonary histoplasmoses<sup>6,14-16</sup>.

On the other hand, histoplasmosis may mimic metastatic lesions by having similar radiographic findings when presenting the tendency to be peripheral on the lower lobes. The aim of this report is to present one of such case with feeding vessel sign that occurs in pulmonary metastasis<sup>10</sup> in a patient with a history of previously diagnosed melanoma.

### CASE REPORT

We present a 64-year-old asymptomatic woman with a history of a wide local excision of a superficial melanoma (Clark level II<sup>5</sup>) eight years ago. During this time she showed no signs of recurrence upon periodic examinations. Presently, a chest x-ray revealed multiple pulmonary nodules in the right lower lobe. On physical examination, she appeared well. No lymphadenopathy was found. A high-resolution axial computed tomography (CT) scan with maximum intensively projection

(MIP) technique that highlighted pulmonary nodules showed numerous small nodules in random distribution. The high-resolution coronal CT scan with MIP technique demonstrated a right lung nodule with feeding vessel sign, which occurs in pulmonary metastasis (Fig. 1 and 2). Histopathological examinations of lung biopsy specimens stained



**Fig. 1** - High-resolution axial CT scan with MIP technique that highlighted pulmonary nodules shows numerous small nodules in random distribution.

(1) Programa de Pós-Graduação em Ciências Pneumológicas, Faculdade de Medicina, Universidade Federal do Rio Grande do Sul (UFRGS), Brazil.

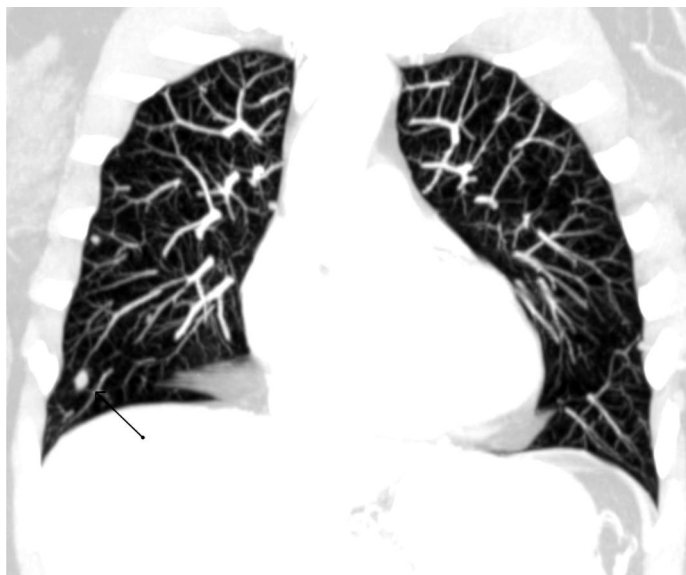
(2) Laboratório de Micologia, Hospital Santa Rita, Irmandade Santa Casa de Misericórdia Porto Alegre (ISCMPA), RS, Brazil.

(3) Estudante, Faculdade de Medicina, Universidade Católica de Pelotas, RS, Brazil.

(4) Professor de Radiologia da Universidade de Ciências Médicas de Porto Alegre, RS, Brazil.

(5) Professor Associado (Nível 3), Departamento de Medicina Interna, Faculdade de Medicina, UFRGS, Brazil. Pesquisador 1B CNPq.

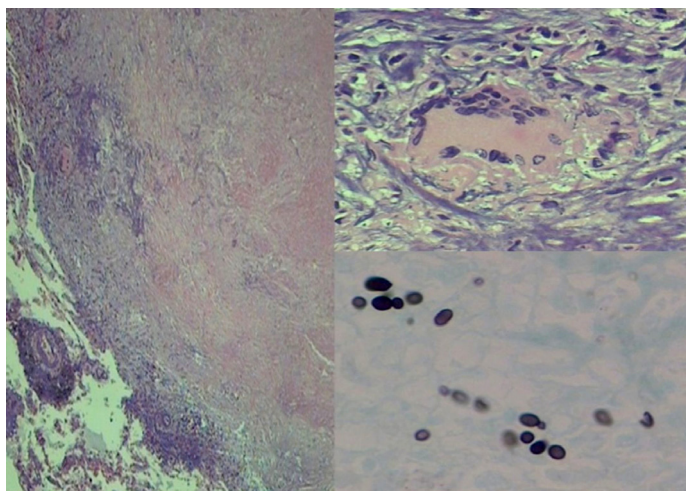
**Correspondence to:** Dr. Luiz Carlos Severo, Laboratório de Micologia, Hospital Santa Rita, Irmandade Santa Casa de Misericórdia Porto Alegre, Annes Dias 285, 90020-090 Porto Alegre, RS, Brazil. Phone: + 55 51 32285208. E-mail: severo@santacasa.tche.br; severo@pesquisador.cnpq.br



**Fig. 2** - High-resolution coronal CT scan with MIP technique demonstrated a right lung nodule with feeding vessel sign that occurs in pulmonary metastasis (arrow).

by hematoxylin and eosin (H&E) showed multiple small white nodules (0.5 - 1.0 cm), and tuberculoid granuloma with central caseous necrosis surrounded by fibrous connective tissue presenting giant cells (Fig. 3A and B). Replicate section stained by Gomori-Grocott methenamine silver (GMS) showed multiple small, round to oval yeasts of *H. capsulatum*. The patient was treated with itraconazole, 200 mg/day for one month, followed by 100 mg daily for six weeks. The antifungal treatment was suspended after six weeks according to the guideline 2007<sup>17</sup>. In a recent follow-up she appeared to be in good clinical condition.

Finally, in a retrospective mycological evaluation the serologic (immunodiffusion) test for histoplasmosis was negative, and the



**Fig. 3** - Tuberculous granuloma. a) An area central of caseous necrosis is surrounded by fibroblastic proliferation, macrophages, and b) multinucleated giant cell (H&E, x40 and x400, respectively). Within the amorphous necrotic debris, c) the ovoid rarely, budding yeast forms of *H. capsulatum* are distinguishable (GMS, x1000).

epidemiologic history showed that the patient had cleaned out a bat-infested attic three years earlier.

## DISCUSSION

Microconidia of *H. capsulatum* (2 to 5  $\mu\text{m}$ ) are small enough to be inhaled into the lungs during environmental disturbances. These primary infectious particles are observed in the mycelial form of the fungus, which finds a natural habitat in soil with high nitrogen content, such as areas contaminated with bat and chicken excrements. Prevention of histoplasmosis infections can often be accomplished by avoiding such areas. If this is not possible, any procedure that minimizes the production of aerosolized dust should be instituted. Especially given that after a heavy exposure, most infections are symptomatic and result in acute pulmonary histoplasmosis<sup>2,12</sup>.

In this case, the patient was exposed to inoculum for a short period of time and developed mild clinical symptoms, and later, chest roentgenograms revealed some peripheral lung nodules, mimicking metastatic lesions. MACKIE *et al.* report a similar case, in which a patient with known metastatic melanoma who was presenting for restaging was initially considered to have widespread mediastinal and cervical metastasis on the bases of the imaging findings<sup>8</sup>.

The incidence of melanoma has increased during the past several decades, and approximately 70% of new cases of melanoma are thin lesions<sup>17</sup>. Patients with these lesions are generally considered to be at low risk for metastasis<sup>4</sup>. However, it is well known that a portion of this group will eventually experience disease recurrence<sup>4</sup>, which was suspected to occur in our case with a melanoma Clark level II history.

In conclusion, histoplasmosis as a self-limited disease in most patients continues to complicate the evaluation of pulmonary nodules and often leads to surgical resection. Exploration in patients with presumed pulmonary metastases from melanoma is justified to rule out benign disease<sup>11</sup>. Ideally, samples of the lung lesions should be taken for culture. This procedure is not always possible, as in this case, because the tissue was immersed in formalin. Therefore, the pathologist, rather than microbiologist, must assume the responsibility for the identification of the infection agent by special tissue stain<sup>3</sup>.

## RESUMO

### **Histoplasmosse apresentando múltiplos nódulos pulmonares. Um caso simulando características radiológicas de metástase pulmonar**

Apresentamos caso de histoplasmosse com múltiplos nódulos pulmonares em paciente com história de melanoma. Este caso simula malignidade, incluindo o sinal de vaso nutridor que ocorre na metástase pulmonar. Enfatizamos a necessidade de considerar esta infecção em áreas onde a histoplasmosse é endêmica.

## REFERENCES

1. Bonfá R, Bonamigo RR, Bonfá R, Duro KM, Furian RD, Zelmanowicz AM. A precocidade diagnóstica do melanoma cutâneo: uma observação no sul do Brasil. *An Bras Dermatol*. 2011;86:215-21.

2. Deepe GS Jr. *Histoplasma capsulatum*. In: Mandell GL, Bennett JE, Dolin, editors. R Mandell, Douglas, and Bennett's principles and practice of infectious diseases. 7<sup>th</sup> ed. Philadelphia: Churchill Livingstone Elsevier; 2010. p. 3305-18.
3. El-Zammar OA, Katzenstein A-L. Pathologic diagnosis of granulomatous lung disease: a review. *Histopathology*. 2007;50:289-310.
4. Faries MB, Wanek LA, Elashoff D, Wright BE, Morton DL. Predictors of occult nodal metastasis in patients with thin melanoma. *Arch Surg*. 2010;145:137-42.
5. Gimotty PA, Botbyl J, Soong SJ, Guerry D. A population-based validation of the American Joint Committee on Cancer Melanoma Staging System. *J Clin Oncol*. 2005;31:8065-75.
6. Goodwin RA, Loyd JE, Des Prez RM. Histoplasmosis in normal hosts. *Medicine (Baltimore)*. 1981;60:231-66.
7. Jemal A, Devesa SS, Hartge P, Tucker MA. Recent trends in cutaneous melanoma incidence among whites in the United States. *J Natl Cancer Inst*. 2001;93:678-83.
8. Mackie GC, Pohlen JM. Mediastinal histoplasmosis: F-18 FDG PET and CT findings simulating malignant disease. *Clin Nucl Med*. 2005;30:633-5.
9. Mata-Essayag S, Colella MT, Roselló A, de Capriles CH, Landaeta ME, de Salazar CP, *et al*. Histoplasmosis: a study of 158 cases in Venezuela, 2000-2005. *Medicine (Baltimore)*. 2008;87:193-202.
10. Murata K, Takahashi M, Mori M, Kawaguchi N, Furukawa A, Ohnaka Y, *et al*. Pulmonary metastatic nodules: CT-pathologic correlation. *Radiology*. 1992;182:331-5.
11. Pogrebniak HW, Stovroff M, Roth JA, Pass HI. Resection of pulmonary metastases from malignant melanoma: results of a 16-year experience. *Ann Thorac Surg*. 1988;46:20-3.
12. Severo LC, Petrillo VF, Camargo JJ, Geyer GR, Porto NS. Acute pulmonary histoplasmosis and first isolation of *Histoplasma capsulatum* from soil of Rio Grande do Sul, Brazil. *Rev Inst Med Trop Sao Paulo*. 1986;28:51-5.
13. Severo LC, Oliveira FM, Irion K, Porto NS, Londero AT. Histoplasmosis in Rio Grande do Sul, Brazil: a 21-years experience. *Rev Inst Med Trop Sao Paulo*. 2001;43:183-7.
14. Severo LC, Lemos ACM, Lacerda HR. Mediastinal histoplasmosis: report of the first two Brazilian cases of mediastinal granuloma. *Rev Inst Med Trop Sao Paulo*. 2005;47:103-5.
15. Unis G, Pêgas KP, Severo LC. Histoplasmoma pulmonar no Rio Grande do Sul. *Rev Soc Bras Med Trop*. 2005;38:11-4.
16. Wheat LJ, Conces D, Allen SD, Blue-Hnidy D, Loyd J. Pulmonary histoplasmosis syndromes: recognition, diagnosis, and management. *Semin Respir Crit Care Med*. 2004;25:129-44.
17. Wheat LJ, Freifeld AG, Kleiman MB, Baddley JW, McKinsey DS, Loyd JE, *et al*. Clinical practice guidelines for the management of patients with histoplasmosis: 2007 update by the Infectious Diseases Society of America. *Clin Infect Dis*. 2007;45:807-25.

Received: 12 September 2012

Accepted: 9 November 2012

# LIBRARY OF THE SÃO PAULO INSTITUTE OF TROPICAL MEDICINE

**Website:** [www.imt.usp.br/portal](http://www.imt.usp.br/portal)

**Address:** Biblioteca do Instituto de Medicina Tropical de São Paulo da Universidade de São Paulo  
Av. Dr. Enéas de Carvalho Aguiar, 470. Prédio 1 – Andar térreo.  
05403-000 São Paulo, SP, Brazil.

**Telephone:** 5511 3061-7003 - **Fax:** 5511 3062-2174

The screenshot shows the website for the Biblioteca do Instituto de Medicina Tropical de São Paulo. At the top left is the logo of the Instituto de Medicina Tropical de São Paulo (IMT USP) and the Universidade de São Paulo. To the right is an 'Intranet' button and social media icons. A navigation bar includes 'Início', 'Sobre o IMTSP', 'Pesquisa', 'Ensino', 'Extensão', and 'Buscar'. Below this is a secondary menu with 'Organização', 'Notícias', 'Administração', 'Biblioteca', 'Revista IMTSP', 'Apoio', 'Concursos e Editais', and 'Contato e Localização'. The main content area is titled 'Biblioteca do Instituto de Medicina Tropical de São Paulo' and includes a mission statement, objectives, and vision. It also features a 'Biblioteca Menu' with links to 'Guia do Usuário', 'Links', 'Livros com texto integral', 'Congressos da Sociedade Brasileira de Medicina Tropical', 'Espaço do Pós-Graduando', 'Pesquisa na Internet', 'Publicações da Biblioteca', 'Revistas Eletrônicas', 'Revistas Gratuitas', 'Sites (Bases de Dados)', and '+informações'. Logos for 'Lattes' and 'QUALIS' are displayed, along with contact information: 'Contato: bibimt@usp.br' and 'Atualizada em 01/12/2010'. A 'Voltar ao Topo' link is at the bottom left.

The Library of the São Paulo Institute of Tropical Medicine (IMTSP Library) was created on January 15, 1959 in order to serve all those who are interested in tropical diseases. To reach this objective, we select and acquire by donation and / or exchange appropriate material to be used by researchers and we maintain interchange between Institutions thorough the Journal of the São Paulo Institute of Tropical Medicine, since the Library has no funds to build its own patrimony.

The IMTSP Library has a patrimony consisting of books, theses, annals of congresses, journals, and reference works.

The collection fo journals existing in the Library can be verified through the USP – Bibliographic Database – OPAC – DEDALUS <http://dedalus.usp.br:4500/ALEPH/eng/USP/USP/DEDALUS/start> of the USP network.