

ASPECTS OF THE GRANULOMATOUS REACTION IN THE LIVER OF MICE INFECTED AND REINFECTED WITH TWO DIFFERENT GEOGRAPHICAL STRAINS OF *SCHISTOSOMA MANSONI*

Pedro Raso, Paulo Marcos Z. Coelho, Nivaldo H. Toppa and
Rômulo T. Mello

In this study, which was undertaken in relation to the histopathologic behavior of two different strains (LE - Belo Horizonte, MG and SJ - São José dos Campos, SP) in infections and reinfections (homologous or heterologous) with Schistosoma mansoni, the authors confirmed a more accentuated pathogenicity of the SJ strain. All the reinfections showed the presence of typical granulomas of the acute phase, when performed either with the same strain (homologous) or with a different strain (heterologous) of the parasite of the primo infection. The possible mechanisms responsible for reactivation of the immunopathologic response in reinfections are discussed.

Key-words: Granuloma. Granulomatous reaction. Schistosoma mansoni. Geographical strains.

Though recent investigations have elucidated some aspects of the interdependence of local reactions against evolutive forms of *Schistosoma mansoni* related to the clinical form of schistosomiasis, further work is needed to clarify the interrelations that command and regulate the appearance of the various hepato-splenic forms of the disease more comprehensively. Aiming at explaining the hepato-splenic forms of the disease, it is important to consider some factors related to the host such as immunological response, age, organ prominently affected, etc., several intimately connected with the parasite must be taken into account, as the parasite's strain, intensity of infection, and number of reinfections with the same or different strains. While our former work showed that the SJ strain of *S. mansoni* caused severer granulomatous lesions around eggs than the ones elicited by the LE strain⁵, the present study aims to

determine whether reinfection performed in mice with both strains would result in new acute phases of the disease.

MATERIALS AND METHODS

Schistosoma mansoni (LE and SJ strains)

LE strain. This strain was isolated from feces of a patient living in the region of Belo Horizonte, and kept in *Biomphalaria glabrata* for more than 30 years at the laboratories of the Schistosomiasis Research Unit, Federal University of Minas Gerais, Brazil.

SJ strain. It was isolated from field *Biomphalaria tenagophila* snails coming from the region of São José dos Campos, Paraíba Valley, State of São Paulo, Brazil, and maintained by laboratory passage in *B. glabrata* and *B. tenagophila*, alternatively, at the Schistosomiasis Research Unit, for more than 15 years.

Using 28 male outbred mice, same age and same weight, we distributed the animals into 7 groups of 4 mice each. All the animals were transcutaneously infected with about 30 cercariae (LE or SJ strains). Four out of the 7 groups (III, IV, V and VI) were reinfected with 30 cercariae (LE or SJ strains), at 90 days after primo infection.

Universidade Federal de Ouro Preto, Ouro Preto, MG e Departamentos de Parasitologia do Instituto de Ciências Biológicas, de Anatomia Patológica da Faculdade de Medicina e de Análises Clínicas e Toxicológicas da Faculdade de Farmácia, Universidade Federal de Minas Gerais, MG, Brasil. Financial support from CNPq, FAPEMIG, FINEP, PRPq, Brazil and WHO, Switzerland.

Address to: Prof. Paulo Marcos Z. Coelho. GIDE/ICB/UFMG, Caixa Postal 486, 30161-970 Belo Horizonte, MG, Brasil.

Recebido para publicação em 10/03/94.

Afterwards, the groups were divided as follows:

- group I - Mice infected with the LE strain.
- group II - Mice infected with the SJ strain.
- group III - Mice infected with the LE strain and reinfected with the same strain.
- group IV - Mice infected with the SJ strain and reinfected with the same strain.
- group V - Mice infected with the LE strain and reinfected with the SJ strain.
- group VI - Mice infected with the SJ strain and reinfected with the LE strain.
- group VII - Control mice (non-infected).

The animals were sacrificed at 150 days after primo infection, that is, 60 days after the last infection, and their livers were removed. From each liver, a 3.0mm thickness slices were formalin-fixed and paraffin-embedded. For histological examination tissue sections were stained with hematoxylin and eosin (HGE) and Sirius Supra-Red F3 BA⁹, and examined using a Zeiss Microscope with polarized light.

RESULTS

Group I - As regards the livers pertaining to this group, which received a single infection with cercariae (LE strain), and whose animals were sacrificed 150 days later, the microscopic features were identical. The fundamental lesion was represented by granulomatous reaction around eggs scattered in the portal tracts and parenchyma. The granulomas were found to be coetaneous, thus indicating the same origin related to just one egg-laying or various ones very close to one another. All of them evidenced (through hematoxylin and eosin staining) the characteristic aspect of the 3rd and 4th evolutive phases, that is, productive phase or in process of cure by fibrosis, both of them denoting the chronicity of infection. The granulomas were small-sized, with little exudation surrounding eggs, and presented irregular fibrosis clearly.

There was no significant cuffing in the periportal connective tissue, which contained mild infiltrate of eosinophils, lymphocytes and plasma cells.

The hepatocytes showed mild degenerative phenomena (loss of basophilia, hydropic or

vacuolar degeneration) and severe polyploidy.

The sinusoids revealed a moderate congestion and dilation. The Kupffer cells were hypertrophic and hyperplastic and contained sometimes schistosome pigment.

Under polarized light the collagen fibrillae appeared in most granulomas in the form of irregular fibrillae, with variable thickness, generally short-sized, intercrossed and oriented in various directions, so as to confer them a "bird's nest" aspect (Figure 1). Unusually, the collagen fibrillae tended to form arched sets of parallel fibers, superposed like a onion skin appearance.

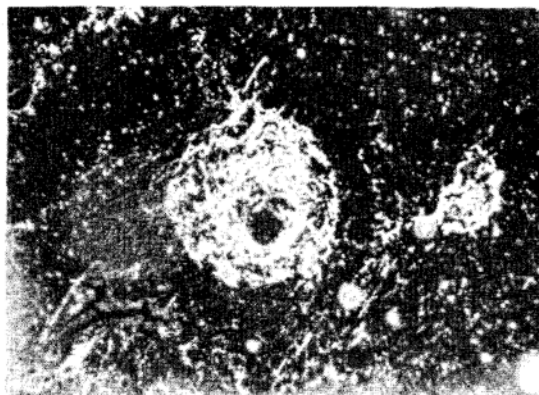


Figure 1 - A small granuloma from group III (stained by Sirius Supra Red) showing an aspect similar to a "bird's nest" due to parallel fibers.

Group II - In this group the mice underwent single infection with the SJ strain. The animals were sacrificed at 150 days after infection. Observation of this group was done with the purpose to compare the results obtained with the ones of group I. In general terms, the microscopic features were found to be similar to group I, but with the following differences: a) the number of granulomas was clearly larger than in group I, not only in the parenchyma but also in the portal tracts, although the fundamental characteristics were the same before mentioned; b) the inflammatory cells (eosinophils, lymphocytes, plasma cells) in the portal tracts were more severe, distending and suppressing some of periportal hepatocytes; c) little foci of intralobular inflammatory infiltrate could be seen in some animals, independently of the granulomatous lesion;

d) the degenerative phenomena of the hepatocytes and polyploidy were more severe; e) the dilated and congested sinusoids showed hypertrophic and hyperplastic Kupffer cells, with a large amount of schistosome pigment.

Observation of the granulomas (under polarized light) revealed the same aspect above mentioned. As occurred on the animals from group I, no worms or lesions caused by them could be seen in this group.

Based on this comparative result, it appears to be valid to affirm that the SJ strain was more virulent than the LE strain, when used under the experimental conditions previously described. These findings corroborate our early results⁵.

Groups III, IV, V and VI were included in the experiments aiming at verifying the effect of reinfections performed with the same or different strains.

Group III - This group comprised four mice infected with the LE strain and reinfected 90 days later, with the same number of cercariae and same strain. They were sacrificed at 60 days after reinfection. As far as the microscopic features of these animals' liver are concerned, it seems to be much the same. The most important lesion was represented by granulomatous reaction around eggs spread on the portal tracts and parenchyma. Two different types of granulomas could be seen clearly: some of them were small, completely taken by fibrosis, whereas the other ones were large and at the exudative phase. A discrete infiltrate of mononuclear and eosinophil could also be seen in the portal tracts. The hepatocytes showed discrete degenerative phenomena and intense polyploidy. The sinusoids were congested and well-dilated, the Kupffer cells were hypertrophic and hyperplastic, and sometimes loaded with schistosome pigment.

The collagen distribution in the smaller granulomas under polarized light was very similar as described in group I. In the larger granulomas - therefore younger - fibrosis detected was less pronounced. The collagen fibers were oriented in various directions, without the tendency to form parallel lamellae. These findings were identical to the ones found in the control animals (uninfected) (group VII). It is important to note that outside the

granulomas, no significant differences could be seen as far as the amount of collagen fibers in relation to the control animals was concerned.

Group IV - We purpose a further attempt to compare the importance of the strain among different reinfections. Thus, the animals of this group were infected with the SJ strain, and reinfected with the same strain 90 days later, following the same procedure used for group II. Mice were sacrificed at 150 days after primo infection, and the results were compared with the ones of group II. Since two different types of granulomas (with different ages, some of them little-sized, fibrous, the other ones larger-sized) could be seen in this group, in general terms the results obtained were similar to the ones from group II. Nevertheless, some differences could be observed: a) the number of granulomas at both evolutive phases (fibrous and exudative granulomas) was larger than in group II; b) as could be seen in group II, the exudative granulomas (caused by reinfection) were predominant in relation to the granulomas in process of cure by fibrosis (originated from primo infection); c) the peri-portal inflammatory exudate, that was composed of eosinophils, lymphocytes and plasma cells, was found to be more pronounced than in groups I, II and III; d) the regressive phenomena in the hepatocytes, such as polyploidy, dilation and sinusoidal congestion were more severe too, and the amount of schistosome pigment was larger.

For all the reasons previously shown, we can conclude that this study demonstrates once more that reinfection with the SJ strain is more virulent than the one caused by the LE strain.

Groups V and VI - Reinfection with crossed strains was carried out in these groups. Animals from group V were infected with the LE strain, and reinfected with cercariae (SJ strain) at 90 days later; mice from group VI were infected with the SJ strain, and submitted to reinfection with the LE strain. The results obtained were compared among themselves, as well as with the ones from groups II and IV.

In all the animals from these groups, there were two types of granulomas, as could be seen in groups II and IV too, with similar characteristics. The

following fundamental differences could be observed, when groups V and VI were compared: a) the number of granulomas in the animals infected with the LE strain and reinfected with the SJ strain was found to be larger than in mice infected with the SJ strain, and reinfected with the LE strain; b) in group V, the amount of fibrous granulomas was larger than in group VI; c) the exudative granulomas were more numerous in group V than in group VI; d) the peri-portal inflammatory exudate was more accentuated in group V; e) the degenerative phenomena in the hepatocytes, as well as polyploidy, were more evident in the animals from group V.

Finally, group VII (control animals, uninfected) was included in this experiment aiming at verifying a possible interference of pathologies others than schistosomiasis, specially allowing to compare the behavior of the periportal connective tissue in infected animals. No hepatic lesions could be detected in the four animals of this group.

DISCUSSION

The results of the present study corroborate our earlier conclusions⁵, showing a severer histopathological features as far as the SJ strain of *S. mansoni* is concerned.

It was possible to verify a more severe compromising of the hepatocytes (degeneration, necrosis, polyploidy), as well as foci of larger intralobular inflammatory infiltrate around little foci of necrosis in the histological preparations related to the SJ strain.

On the other hand, a surprising evidence was the appearance of a new acute phase in the groups of reinfected animals, with both heterologous and homologous strains. It is important to point out that egg-laying connected with the second infection started when primo infection was in process of chronic phase of the disease (about 130 days after primo infection). In principle, the presence of typical granulomas of the acute phase in the groups submitted to infection with heterologous strain could be explained by some differences found in the constituents of the soluble egg antigen (SEA), as stated in our earlier study⁵, which showed a stronger pathogenicity of the SJ strain, these data being

corroborated by the present work. Since these granulomas found to be typical of the acute phase appeared also in reinfections with the same strain of the parasite, other mechanisms could be present too, altering the control or modulation of the granulomatous response, which was maintained in the groups submitted to a single infection. Modulation of the inflammatory response around *S. mansoni* egg at the chronic phase of the disease was first described by Andrade & Warren¹. Nowadays, it is mentioned as a well-known phenomenon, as can be seen in Boros' review².

Possibly, the factors that could be pointed out as being related to alteration in the process of modulation of the granulomatous response in reinfections are as follows: overload of the host's immune system, with migration of the worms from reinfections (skin - lungs - portal system), a larger amount of antigens deriving either from adult worms related to reinfections or mainly from secretions originated in eggs, that are acknowledged to be the fundamental elements in the immunopathology of schistosomiasis^{2 3 8}. This antigenic overload could surpass the immunoregulatory capacity, that was elementary adapted to a lower worm burden.

A larger number of granulomas could also be seen in reinfections with the SJ strain. This finding allows the supposition that concomitant immunity connected with the SJ strain could be less efficient. Our earlier data showed a weaker immunoprotective capacity in mice with mature infections performed with the SJ strain, and submitted to reinfections with homologous and heterologous strains⁴.

These findings on strengthen of infection at the chronic phase of experimental schistosomiasis led us to repeat this experiment with a larger number of animals to obtain additional corroborative evidence⁶.

Presently, in murine schistosomiasis, it has been demonstrated a predominance of Th1-cells at the acute phase of the disease¹². At the chronic phase, with the modulate smaller-sized granulomas, a decrease in the amount of interferon-gamma and interleukin-2 secretions occurs, coincidentally with an increase in the levels of interleukins 4 and 5, these facts suggesting a binding between the Th2-response and modulation of function of the Th1-cells¹¹.

On the other hand, still regarding the murine schistosomiasis, a significant increased level of interleukin-10 was detected when the Th1-response was found to be modulated^{7 10 13}. Thus, the interleukins 4 and 10, both of them produced by Th2, should play an important role, that is, modulating the inflammatory responses in schistosome infections. The process of modulation of the granulomatous response is complex and, besides the factors related to the host's immunological mechanism, such as cellular response and production of lymphocines, other factors connected with the parasite must be taken into account, such as: immunodepressor factor derived from *S. mansoni* (SIDIF) and tetrapeptide TKP (threonine, lysine, proline) produced by cleavage of the host's immunoglobulins through proteolytic enzymes of the parasite that act on the suppression of macrophage activation, thus reducing the formation of granulomas *in vitro*¹². Some factors connected with the *S. mansoni* strain may also act in a different manner, since various *S. mansoni* strains produce granulomatous reactions with diversified intensity. Our results show that the lesions caused by the SJ strain are always severer, including the ones caused by reinfections. These corroborate our earlier conclusion⁵.

Further detailed studies are needed to establish with accuracy the mechanism responsible for altering the modulation of the granulomatous response in reinfections.

Therefore, further research dealing with quantification of lymphocines before and after reinfections, mainly interferon-gamma and interleukins 2, 4, 5 and 10, would be helpful in order to give substantial agreement related to the factors that are possibly bound to strengthen of the granulomatous inflammatory response around eggs.

When one wants to extrapolate the present results obtained in mice applying them to humans, it is important to take into account the enormous phylogenetic distance, as well as the difference in body weight between these two hosts. Nevertheless, in part, these findings can be helpful to clear up the matter on the variations of the anatomoclinic forms of schistosomiasis mansoni in different geographical regions. These various geographical areas present *S. mansoni* strains well defined by the different

biological behaviors concerning the various lineages and species of snails pertaining to the genus *Biomphalaria*.

RESUMO

No presente estudo, verificou-se o comportamento histopatológico das infecções e reinfecções, homólogas ou heterólogas, das cepas LE (Belo Horizonte, MG) e SJ (São José dos Campos, SP) de *Schistosoma mansoni*. Confirmou-se uma maior patogenicidade da cepa SJ de *S. mansoni*. As reinfecções, independentemente de terem sido feitas com a mesma cepa (homóloga) ou cepa diferente da primo infecção (heteróloga) do parasito, mostraram a presença de granulomas típicos da fase aguda. São discutidos os possíveis mecanismos responsáveis pela reagudização da resposta imunopatológica nas reinfecções.

Palavras-chaves: Granuloma. Reação granulomatosa. *Schistosoma mansoni*. Cepas geográficas.

ACKNOWLEDGEMENTS

To CNPQ, FINEP, FAPEMIG, PRPq-UFMG, Brazil and WHO, Switzerland, for financial support. To Mrs. Vera de Paula Ribeiro for translating the manuscript. To Mr. Alberto G. dos Santos, Mrs. Alice Neni F. Balzuweit and Miss Zenir de Souza for technical assistance.

REFERENCES

1. Andrade ZA, Warren, KS. Mild prolonged schistosomiasis in mice: alteration in host response with time and the development of portal fibrosis. *Transactions of the Royal Society of Tropical Medicine and Hygiene* 58:53-57, 1964.
2. Boros DL. Immunopathology of *Schistosoma mansoni* infection. *Clinical Microbiology Reviews* 2:250-269, 1989.
3. Boros DL, Warren KS. Delayed hypersensitivity granuloma formation and dermal reaction induced and elicited by a soluble factor isolated from *Schistosoma mansoni* eggs. *Journal Experimental Medicine* 132:488-507, 1970.
4. Coelho PMZ, Raso P, Mello RT, Toppa NH. *Schistosoma mansoni*: Diferenças entre cepas no hospedeiro vertebrado. In: I International Symposium on Schistosomiasis. Rio de Janeiro, RJ, p.132, 1987.

Raso P, Coelho PMZ, Toppa NH, Mello RT. Aspects of the granulomatous reaction in the liver of mice infected and reinfected with two different geographical strains of *Schistosoma mansoni*. *Revista da Sociedade Brasileira de Medicina Tropical* 27:221-226, out-dez, 1994.

5. Coelho PMZ, Raso P, Mello RT, Toppa NH. Dimensões do granuloma hepático produzido por ovos de duas cepas geográficas de *Schistosoma mansoni*. *Memórias do Instituto Oswaldo Cruz* 84:213-217, 1989.
6. Coelho PMZ, Raso P, Mello RT, Toppa NH. *Schistosoma mansoni* in mice: Modulation of granulomatous response after reinfection and chemotherapeutic treatment. *Revista da Sociedade Brasileira de Medicina Tropical* 27:119-125, 1994.
7. Fiorentino DF, Zlotnik A, Mosmann JR, Howard O'Garra A. IL-10 Inhibits cytokine production by activated macrophages. *Journal of Immunology* 147:3815-3822, 1991.
8. Hang LM, Warren KS, Boros DL. *Schistosoma mansoni*: antigenic secretions and the etiology of egg granulomas in mice. *Experimental Parasitology* 35:288-298, 1974.
9. Junqueira LCV, Bignolas G, Brentani R. Picrosirino staining plus polarization microscopy, a specific method for collagen detection in tissues sections. *Histochemical Journal* 11:47-54, 1979.
10. Mosmann TR, Moore KW. The role of IL-10 in cross regulations of Th1 e Th2 responses. *Immunology Today* 12:A49-A53, 1991.
11. Pearce EG, Caspar P, Grzych JM, Lewis FA, Sher A. Row regulations of Th1 cytokine production accompanies induction of Th2 response by a parasitic helminth, *Schistosoma mansoni*. *Journal of Experimental Medicine* 173:159-166, 1991.
12. Phillips SM, Lammie PJ. Immunopathology of granuloma formation and fibrosis in schistosomiasis. *Parasitology Today* 2:296-302, 1986.
13. Scott P, Kaufmann SHE. The role of T cell subsets and cytokines in the regulation of infection. *Immunology Today* 12:346-348, 1991.