

Recurrent oedema associated with the co-formulation of lopinavir and ritonavir

Edema recorrente associado à co-formulação de lopinavir e ritonavir

To the Editor:

Highly active antiretroviral regimens that include the HIV-1 protease inhibitor lopinavir, co-formulated with ritonavir, have recently been associated with episodes of inflammatory oedema, most frequently of the feet, ankles and legs, in patients with severely advanced HIV-1 disease²⁻⁴. One of these previously reported patients experienced a recurrence of oedema of the feet and ankles seven months after the first episode (Figure 1A). We report a case of remitting and relapsing oedema of the left hand, wrist and fingers in a patient on a lopinavir-including antiretroviral//HAART regimen.

A 34-year old HIV-1-infected male patient with a six-year history of uninterrupted antiretroviral therapy was started on a new regimen consisting of stavudine, lamivudine, nevirapine and lopinavir/ritonavir. He had already been exposed to the first three antiretroviral agents, but was naïve to both ritonavir and lopinavir. He had a CD4 cell count of 195 cells/mm³ and an HIV-1 plasma

viral load of 10,000 copies/ml. Eight months after starting the new regimen he developed an oedema of moderate intensity of his left hand and wrist that fully recovered over the ensuing two weeks. One month later, a second and milder episode occurred (Figure 1B) followed by two other recurrences during the next five months. One year later, he had experienced several such episodes, occasionally involving his left fingertips. These oedema episodes were only mildly painful but sometimes frightening due to their speed of installation. They were not associated with additional clinical or new laboratory abnormalities and invariably remitted spontaneously over the ensuing 24 to 72 hours without treatment other than maintenance of the antiretroviral medications.

Our patient's clinical presentation of relapsing and remitting oedema of the hand, wrist and fingers shares a resemblance to the recently described syndrome of inflammatory oedema associated with lopinavir-including antiretroviral//HAART

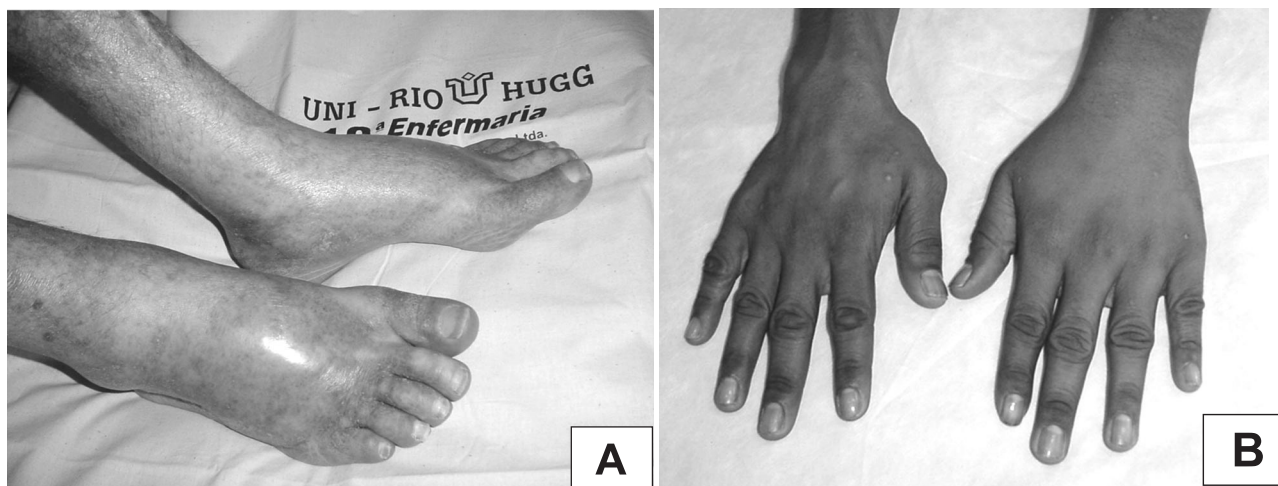


Figure 1 - A) Recurrence of feet and ankle oedema, more pronounced on the right, in a 41-year-old male patient on lopinavir/ritonavir (reported in reference 2). B). Dorsal view of the first relapse of oedema of the left hand and wrist of the patient reported in the present communication.

1. Serviço de Alergia e Imunologia Clínica do Hospital Universitário Gaffrée e Guinle da Universidade Federal do Estado do Rio de Janeiro, Rio de Janeiro, RJ.
Address to: Prof. Jorge Francisco C. Pinto. Hospital Universitário Gaffrée e Guinle/10ª enfermaria/UNIRIO. Rua Mariz e Barros 775, 20270-004 Rio de Janeiro, RJ.
e-mail: pintojf@uol.com.br
Recebido para publicação em 26/3/2004
Aceito em 31/5/2004

regimens. In particular, its remitting nature resembles the feet and ankle oedema experienced by the patient previously reported in reference 2. The latter patient, however, developed only one, not several, oedema episodes. Due to its benign evolution, we found that these oedema episodes did not justify any change in the antiretroviral regimen of the patient reported herein.

Other syndromes of peripheral oedema associated with antiretroviral agents have also been described. The protease

inhibitor ritonavir has been associated once with acute painless oedema of the legs¹. More recently, a syndrome of slowly developing, severe lower extremity oedema associated with high blood flow of the common femoral arteries has been linked to the use of the reverse transcriptase inhibitor stavudine⁴. Physicians caring for HIV-1-infected patients should be aware of these syndromes of peripheral oedema, so that appropriate counseling and management can be instituted.

**Jorge Francisco C. Pinto¹, Walter A. Eyer-Silva¹
and Carlos Alberto Morais-de-Sá¹**

REFERENCES

1. Dol L, Geffray L, El Khoury S, Cevallos R, Veysier P. Œdèmes des membres inférieures chez un patient séropositif pour le VIH: effet secondaire du ritonavir? *Presse Médicale* 28:75, 1999.
2. Eyer-Silva WA, Motta RN, Pinto JF, Morais-de-Sá CA. Inflammatory oedema associated with lopinavir-including HAART regimens in advanced HIV-1 infection: report of 3 cases. *AIDS* 16:673-674, 2002.
3. Guyot S, Hayoz D, Telenti A, Cavassini M. Peripheral oedema and high arterial blood flow as a complication of antiretroviral therapy. *AIDS* 18:356-358, 2004.
4. Lascaux A-S, Lesprit P, Bertocchi M, Levy Y. Inflammatory oedema of the legs: a new side effect of lopinavir. *AIDS* 15:819-821, 2001.