

# Clinical and ultrasound findings before and after praziquantel treatment among Venezuelan schistosomiasis patients

Achados clínicos e no ultra-som pré e pós tratamento com praziquantel em pacientes venezuelanos com esquistossomose

Raiza Ruiz-Guevara<sup>1</sup>, Belkisyolé Alarcón de Noya<sup>1</sup>, Sharon Kay Valero<sup>2</sup>, Pablo Lecuna<sup>2</sup>, Miguel Garassini<sup>2</sup> and Oscar Noya<sup>1</sup>

## ABSTRACT

*Abdominal ultrasound can be a useful tool for diagnosing periportal fibrosis related to Schistosoma mansoni infection, and also for planning and monitoring the evolution of hepatic morbidity following control measures. We evaluated the standardized ultrasound methodology proposed by the World Health Organization for detecting periportal fibrosis and portal hypertension, among patients from an endemic area in Venezuela, and the impact of praziquantel treatment 3-5 years later. After chemotherapy, complete reversal of periportal lesions was observed in 28.2% of the cases and progression of the disease in 5.1%. Improvement in the hepatic disease started with a reduction in the periportal thickening followed by a decrease in the size of the left hepatic lobe, spleen and mesenteric and spleen veins. Ultrasound confirmed the clinical findings after chemotherapy among the patients with reversal of the disease. However, in patients with more advanced disease, these findings were contradictory. There was no correlation between evolution of the disease seen on ultrasound and age, intensity of infection or serological findings.*

**Key-words:** Schistosoma mansoni. Ultrasound. Low transmission area. Venezuela. Praziquantel.

## RESUMO

*O ultra-som abdominal pode ser uma ferramenta útil para o diagnóstico da fibrose periportal relacionada à infecção por Schistosoma mansoni, e também para planejar e monitorar a evolução da morbidade hepática após medidas de controle. Nós avaliamos a metodologia padronizada no ultra-som, proposta pela Organização Mundial da Saúde, para a detecção da fibrose periportal e hipertensão porta, em pacientes de área endêmica da Venezuela e o impacto do tratamento com praziquantel 3-5 anos depois. Após quimioterapia, houve reversão completa das lesões periportais em 28,2% dos casos e progressão da patologia em 5,1%. A melhora da patologia hepática começou com a redução do espessamento periportal seguida pela diminuição do tamanho do lobo esquerdo, baço e veias mesentérica e esplênica. O ultra-som confirma os achados clínicos após quimioterapia em pacientes com reversão da patologia; contudo, naqueles com patologia mais avançada, estes achados foram contraditórios. Não houve correlação entre evolução da patologia ultra-sonográfica com idade, intensidade da infecção ou achados sorológicos.*

**Palavras-chaves:** Schistosoma mansoni. Ultra-som. Área de baixa transmissão. Venezuela. Praziquantel.

Schistosomiasis is the main cause of periportal fibrosis worldwide<sup>34</sup> and is responsible for the classic hepatointestinal clinical manifestations of chronic schistosomiasis. Abdominal ultrasound (US) is an alternative method for epidemiological fieldwork, because it is not an expensive or invasive method and provides immediate results<sup>3</sup>. In studies on periportal fibrosis, some authors have found that US is comparable with liver biopsy<sup>2,10,13</sup> and

angiography<sup>21</sup>, but not with fibrogenesis markers<sup>8,16,17</sup>. Since 1992, World Health Organization (WHO) experts and other investigators have proposed some standardized methods for defining the presence and degree of periportal fibrosis. US can be used to plan strategies for controlling schistosomiasis-related morbidity and monitoring its evolution after treatment. Anti-*Schistosoma mansoni* drugs allow partial or complete reversal of periportal

1. Cátedra de Parasitología, Instituto de Medicina Tropical, Universidad Central de Venezuela, Caracas, Venezuela. 2. Cátedra de Gastroenterología. Escuela de Medicina Luis Razetti, Facultad de Medicina, Universidad Central de Venezuela, Caracas, Venezuela.

Financial support: The first part of the present work was supported by a grant obtained by the PCEE/PNUD (Project VEN/96/002) through a grant from FONACIT. The second part was financed by the "Agenda Salud" - FONACIT (Projects N° 2000001878 and 2005000199).

**Address to:** Dra. Raiza Ruiz-Guevara. Cátedra de Parasitología. Instituto de Medicina Tropical, Universidad Central de Venezuela, Los Chaguaramos, Caracas 1041-A, Apartado Postal 47706, Venezuela.

Tel: 0058212605-3548/0058212605-3587; Fax: 0058212605-3563.

e-mail: raizaruiz@yahoo.com

Recebido para publicação em: 24/02/2006

Aceito em: 19/09/2007

fibrosis as assessed by US<sup>7 11 14 25</sup>. While the majority of these studies have been conducted in high or moderate transmission areas, information about areas of low endemicity is scarce. In this study, we evaluated periportal fibrosis in schistosomiasis cases using US before and after specific treatment, in one community of our low endemic transmission area in Venezuela.

## MATERIAL AND METHODS

This work was carried out between 1998 and 2003 in Belén (Carabobo State) in the central-northern region of Venezuela. In this focus of schistosomiasis, large-scale control programs based on selective praziquantel (PZQ) chemotherapy, environmental measures, water supply measures, sanitation and snail control had been applied. However, in 1998-2000, we demonstrated that transmission had re-emerged, since we found infected *Biomphalaria glabrata* snails and prevalence of 12.6% using parasitological and serological criteria<sup>5</sup>.

The parasitological diagnosis of schistosomiasis was made using the Kato-Katz method<sup>18</sup>. Before and after treatment, two Kato smears were prepared from one fecal sample. Based on the WHO criteria<sup>35</sup>, three categories of infection intensity (expressed as eggs per gram of feces) were considered: mild (1-100 eggs per gram of feces), moderate (101-400) and severe (>400).

Venous blood was collected from each person and sera were stored at -80°C. The following serological tests were performed: enzyme-linked immunosorbent assay with soluble antigen of *Schistosoma mansoni* egg using sodium metaperiodate (ELISA-SEA-SMP)<sup>4</sup>, alkaline phosphatase immunoassay (APIA)<sup>24</sup> and the circumoval precipitin test (COPT)<sup>31</sup>.

Parasitological and immunological tests made it possible to allocate patients to one of three categories of schistosomiasis case<sup>5</sup>: Criterion I: people with *Schistosoma mansoni* eggs in stools, who usually had positive results from all the serological tests; Criterion II: people without *Schistosoma mansoni* eggs in stools, but with positive results from COPT and from one or both of the immunoassays, and without previous anti-schistosomal treatment over the last 12 months; and Criterion III: people without *Schistosoma mansoni* eggs in stools, with negative results from COPT and simultaneously positive results from both immunoassays, and without previous anti-schistosomal treatment.

Physical examination of the liver and spleen were performed as described in Ruiz-Guevara et al<sup>30</sup>. The clinical classification of previously defined "schistosomiasis cases" was based on the following criteria modified from Prata<sup>22</sup> and Prata & Andrade<sup>23</sup>: Asymptomatic: people without symptoms or any pathological findings from the physical examination; Intestinal: people with intestinal symptoms but without findings from the physical examination of the abdomen; Hepatointestinal: people with palpable liver (right or left hepatic lobe) of any consistency or surface shape (soft/hard or smooth/nodular), but without splenomegaly; and hepatosplenic: people with palpable liver that was usually hard, with or without a prominent left hepatic lobe

and with or without a nodular surface, and with a palpable spleen at the costal margin or below.

Abdominal ultrasound was performed using a Toshiba portable ultrasound scanner equipped with a 3.75 MHz convex transducer. The left hepatic lobe was measured in longitudinal view along the left parasternal line, and the right hepatic lobe was measured in longitudinal view along the anterior axillary line. The main portal vein was studied in an oblique subcostal view: its external diameter was measured, as well as its internal diameter and its wall. In an oblique right subcostal view, the diameters of three second-order portal branches were determined; their external (outer-to-outer) diameter (D), their internal (inner-to-inner) diameter (d) and the wall itself were measured. For each measurement, the mean value was obtained. Four approaches were used to define periportal thickening: a) according to the D value; b) according to the D-d value; c) according to the wall measured directly, and d) according to the D/d ratio. The internal diameters of the superior mesenteric and splenic veins were determined<sup>21</sup>. The spleen was evaluated in a left oblique view along its maximum diameter, at the hilum. Measurement of the gallbladder wall was obtained in longitudinal view along the right midclavicular line. The presence or absence of collateral vessels or ascites was determined<sup>15</sup>. To define US periportal fibrosis, the indicators proposed by the Niamey-Belo Horizonte Working Group<sup>27 28</sup> (N-BH classification) were used. To simplify the N-BH classification, we grouped the interpretation of the scores into degrees of fibrosis, as described by Richter et al<sup>28</sup>.

Once the parasitological, serological, clinical and ultrasound evaluations had been done, the patients presenting *Schistosoma mansoni* infection were treated with a single dose of PZQ (40mg/kg). Other intestinal parasites were treated with the corresponding drug. Only volunteers participated in this study. For this longitudinal descriptive cohort study, we included the schistosomiasis patients who heeded the convocations before and after the treatment convocations, with a full set of laboratory tests done and with pretreatment US and at least one US thereafter, either 3 or 5 years later.

The data were analyzed using SPSS for Windows (Version 10.0; Copyright SPSS Inc., 1989-1999). Following descriptive analysis, the information was compared using Student's t test for paired samples when the normality and variance homogeneity analyses allowed. Otherwise, non-parametric tests for two related samples were used.

## RESULTS

Out of 974 people evaluated in Belén up to 1998, 184 (18.9%) were diagnosed as "schistosomiasis cases". Of these, 150 were examined using US: 114 men and 36 women, with ages between 8 and 54 years. Among these individuals, 84 (56%) eliminated a mean of 133.1 *Schistosoma mansoni* eggs per gram of feces and were considered to be cases within Criterion I. The majority presented mild infection (64.3%), while 32.1% had moderate and 3.6% had severe infection. Fifty-two people (34.7%) were

considered to be *schistosomiasis* cases according to Criterion II, and a further 14 (9.3%) were within Criterion III.

Figure 1 explains the work sequence three to five years post-chemotherapy. Only 78 out of the 150 patients with schistosomiasis had one or two post-treatment evaluations with all the inclusion criteria (Figure 1). The mean egg output from the 49 patients classified under Criterion I was 126.7 eggs per gram of feces. Individuals aged 20 years and under predominated at the three observed times (67.9%, 75% and 64.8%). Among the 28 schistosomiasis patients evaluated three years after treatment, 17 (60.7%) remained infected, among whom four presented a mean of 57 *Schistosoma mansoni* eggs per gram of feces (range: 24-96) and 13 were in accordance with Criterion II. Out of the 71 reevaluated five years later, 33 (46.4%) were infected, and 38 (53.5%) did not present active infection; of those infected, 20 eliminated a mean of 97 *Schistosoma mansoni* eggs per gram of feces (range: 12-408) and the other 13 were diagnosed under Criterion II. There was no statistically significance difference between US evolution after treatment and intensity of infection or diagnostic criteria. Among the 78 clinically evaluated individuals, 70 were re-examined thereafter (Table 1). The size of the liver was significantly reduced. None of them presented a prominent left hepatic lobe, nodular liver or splenomegaly five years post-treatment. However, eight individuals (11.4%) showed moderately increased consistency of the liver in relation to the pretreatment evaluation.

There were no significant changes with regard to the clinical diagnosis of schistosomiasis. In the pretreatment evaluation, 39 (50%) patients were diagnosed as asymptomatic, and this number remained five years after PZQ therapy. The prevalence of the hepatointestinal form was very similar in the two clinical evaluations (46.2% in 1998 and 50% in 2003). After therapy, none of the patients exhibited hepatosplenic schistosomiasis, whereas in 1998 three (3.8%) individuals had that condition. None of the intestinal forms appeared in either of the two studies.

The ultrasound measurements of the left hepatic lobe, mesenteric and splenic vein, spleen, D-d, D/d, periportal branch wall and gallbladder wall showed statistically significant reductions ( $p < 0.05$ ) when the mean values before and after treatment were compared (Table 2). In contrast, the right hepatic lobe augmented

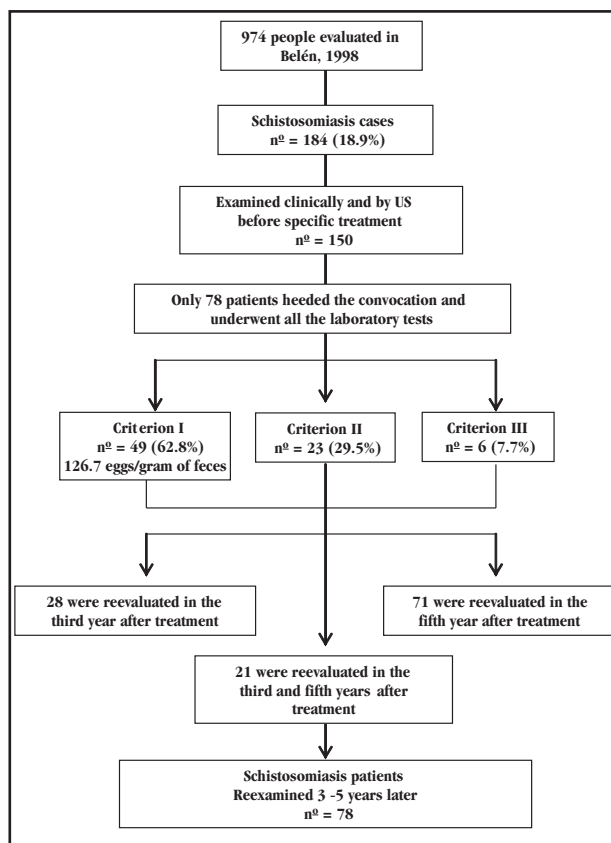


Figure 1 - *Schistosoma mansoni*-infected persons diagnosed and evaluated clinically and by abdominal ultrasound pre and post-praziquantel treatment, Belén, Venezuela, 1998-2003.

significantly, by a mean of 6.8cm thereafter ( $p < 0.05$ ). The internal diameter and D of the main portal vein were not different before and after PZQ therapy. D-d, D/d and periportal branch walls were the first parameters to vary after treatment (Table 2).

Table 3 shows the US findings using the parameters proposed by the N-BH classification for periportal fibrosis among the patients with pretreatment US and the 78 individuals who underwent at least one post-treatment US examination. In the pretreatment examination, 23 (24.5%) schistosomiasis patients had variable degrees of periportal fibrosis. Analyzing each degree of fibrosis, we did not find any statistical differences in fibrosis in relation to age, diagnostic criteria or egg output before treatment. The results

Table 1- Findings from abdominal examination of patients with schistosomiasis, Belén, Venezuela, 1998-2003.

Signs	Pre-treatment (n° = 78)	5 Years post-treatment (n° = 70)	Statistical significance*
Palpable liver	43 (55.1%)	34/69 (49.3%)	no
Mean distance (cm) below the costal margin along the MCL	3.5cm	2.8cm	yes
AAL > 9cm	59/73 (80.8%) mean 12.1cm	23/57 (40.4%) mean 9.9cm	yes
Liver measurement**	MCL > 11cm	10/57 (17.5%) mean 9.5cm	yes
MSL > 9cm	31/72 (43.1%) mean 8.9cm	13/56 (23.2%) mean 7.6cm	yes
Increased consistency	0 (0%)	8 (11.4%)	yes
Left hepatic lobe prominent	13 (16.7%)	0 (0%)	yes
Nodular liver	0 (0%)	0 (0%)	no
Splenomegaly	3 (3.8%)	0 (0%)	no

\*according to Student's t test for paired samples ( $p < 0.05$ )

\*\* liver measurement, AAL: anterior axillary line, MCL: midclavicular line, MSL: midsternal line

**Table 2 - Evolution of ultrasound parameters (mean values in mm and SD) among 78 schistosomiasis patients before and after chemotherapy, Belén, Venezuela, 1998-2003.**

Ultrasound parameter	Before treatment	3 years after treatment	5 years after treatment
	(n <sup>o</sup> = 78)	(n <sup>o</sup> = 28)	(n <sup>o</sup> = 71)
Left hepatic lobe	86.6 (± 1.4)	84.5 (± 2.3)*	62.2 (± 1.2)***
Right hepatic lobe	113.1 (± 1.2)	112.8 (± 1.9)*	121.1 (± 1.4)***
Main portal vein	8.4 (± 0.2)	8.3 (± 0.3)	8.2 (± 0.2)
Mesenteric vein	7.5 (± 0.2)	8.7 (± 0.4)*	4.2 (± 0.1)***
Spleen	98.8 (± 1.9)	86.0 (± 4.6)	94.6 (± 1.4)***
Splenic vein	5.8 (± 0.2)	6.1 (± 0.5)	5.0 (± 0.1)***
D	4.1 (± 0.1)	4.0 (± 0.3)	4.0 (± 0.1)
D-d	2.7 (± 0.1)	2.3 (± 0.1)**	2.2 (± 0.1)***
D/d	3.3 (± 0.1)	2.6 (± 0.1)**	2.3 (± 0.1)***
Periportal branch wall	1.4 (± 0.1)	1.2 (± 0.04)**	1.2 (± 0.02)***
Gallbladder wall	2.2 (± 0.1)	-	1.7 (± 0.1)***

\*Statistically significant difference between mean values 3 years and 5 years after treatment

\*\*Statistically significant difference between mean values pretreatment and 3 years after treatment

\*\*\*Statistically significant difference between mean values pretreatment and 5 years after treatment

Spleen, splenic vein, D-d and periportal branch wall were analyzed by non-parametric tests for two related samples, while the other parameters were analyzed using Student's t test for paired samples.

**Table 3- Evolution of periportal fibrosis (Niamey-Belo Horizonte classification) following anti-schistosomal treatment among 78 patients, Belén, Venezuela, 1998-2003.**

Degree of fibrosis	Pre-treatment		Post-treatment					
			without changes		reversal of disease		increased disease	
	n <sup>o</sup>	%	n <sup>o</sup>	%	n <sup>o</sup>	%	n <sup>o</sup>	%
No sign of PPF	55	70.5	52	94.5	0	0.0	3	5.5
Incipient PPF	6	26.1	0	0.0	5	83.3	1	16.7
Probable PPF	10	43.5	0	0.0	10	100.0	0	0.0
Fibrosis	4	17.4	0	0.0	4	100.0	0	0.0
Advanced PPF	2	8.7	0	0.0	2	100.0	0	0.0
Advanced PPF + PH	1	4.3	0	0.0	1	100.0	0	0.0
Total evaluated	78	100	52	66.7	22	28.2	4	5.1

PPF: periportal fibrosis, PH: portal hypertension

were no different when all the fibrosis criteria were compared as a whole. Six patients without any sign of periportal fibrosis according to the N-BH classification had a dilated main portal vein. Three patients without signs of periportal fibrosis before treatment presented probable periportal fibrosis in the third US and 52 continued not to present any disease in successive US. Out of the six patients with incipient periportal fibrosis in the first examination, one progressed to more advanced disease and the other five presented reversal of periportal lesions. The other 17 patients with fibrosis on the initial US presented reversal of the disease on the second or third US (Table 3). Overall, out of the 78 individuals re-examined after chemotherapy, 22 (28.2%) presented complete reversal of fibrosis and four (5.1%) presented deterioration (Table 3). Among the patients with more advanced disease after chemotherapy, three had no signs of periportal fibrosis on the first US; the mean age of that group was 23 years. One very young person with incipient periportal fibrosis in the initial evaluation, also became worse after treatment, and presented probable periportal fibrosis in the post-treatment US evaluation. Among the people with more advanced disease, some abnormalities in the image pattern of the liver parenchyma

were observed. However, the measurements of the walls of the second-order portal branches and the portal vein diameters were normal (these criteria were qualitative, not quantitative). Out of 53 reevaluated individuals who were less than 21 years old, 15 (28.3%) presented reversal of US lesions, and three (5.7%) had advanced disease. Among the 25 individuals aged more than 20 years, seven (28%) presented reversal of US lesions and one (4%) got worse. Reversal or deterioration of the disease was not statistically related to age, allocation to diagnostic criteria or egg output prior to treatment.

With regard to clinical findings, the group with more advanced disease on US presented palpable liver at the first and second clinical evaluations, and the mean measurement below the right costal margin diminished from 3.6 to 2.5cm at the post-treatment examination. Liver measurements also decreased after chemotherapy. Nobody in this group presented a hard liver at the pretreatment evaluation, but one individual presented moderately hard consistency at the post-treatment evaluation. The prominent left hepatic lobe was not found after treatment, nor was nodular liver or splenomegaly. Among the individuals in the US reversal group, the prevalence of palpable liver increased slightly. However,

the size of the liver decreased from 3.6cm to 2.2cm following PZQ therapy.

Based on the N-BH classification, the prevalences of left lobe hepatomegaly (60.3%), splenomegaly (11.5%) and gallbladder wall thickening (2.6%) reduced significantly to 2.8%, 0% and 0% respectively, but the prevalence of right hepatic lobe atrophy (0%) increased to 1.4%. Ascites and collateral vessels were not found.

## DISCUSSION

In spite of the large-scale control measures against schistosomiasis that had been applied in Belén, reemergence of transmission was observed in 1998-2001<sup>5</sup>. We diagnosed and made full evaluations on 150 people, but only 78 attended 3-5 years later, following PZQ therapy. The main cause of this was student movements to urban areas. In this group, active infection decreased from 92.3% to 60.7% by the third year, and to 46% by the fifth year, based on laboratory tests. The likelihood of reinfection (rather than diminished susceptibility to PZQ) was high, considering that more than 70% of these people admitted having contact with watercourses<sup>5</sup>. In a previous study in an area where transmission was interrupted, we obtained a cure rate of 63.8% after one year<sup>6</sup>, in comparison to 46% in the present study, in which interruption of transmission cannot be ruled out.

The US findings demonstrated that PZQ chemotherapy improved the liver disease and decreased the markers for periportal thickening, such as D-d, D/d and periportal wall branches. Other parameters such as left hepatic lobe, splenic vein and spleen, decreased significantly; the mesenteric vein was increased at the first post-treatment US but subsequently decreased. Small periportal branches seem to be the first structure in which the fibrosis starts to regress, since the changes were already notable at the third year evaluation. One important finding was the inverse relationship between decreased left hepatic lobe and enlarged right hepatic lobe following treatment. We do not have a satisfactory explanation for this, or for the transitory increased diameter of the mesenteric vein after PZQ therapy. Decreased frequency of hypertrophy of the right hepatic lobe on US, following chemotherapy for *Schistosoma japonicum* infection has been found by other investigators<sup>20</sup>.

In spite of the predominance of low parasitic burden in all the evaluations, as evaluated using the latest US proposal from WHO (N-BH classification), we found that 23 people (29.5%) with pretreatment evaluations had some degree of periportal fibrosis, and seven of them had defined signs of periportal disease. The prevalence of pathological changes is not always associated with egg output or laboratory tests; it is possible that disease is present, but that *Schistosoma mansoni* eggs are not being excreted and remain trapped in fibrous lesions<sup>12</sup>. Previous studies on experimental animals have estimated that 50% of the eggs are retained in tissues, especially in the liver<sup>33</sup>.

We observed that six people with portal vein dilatation did not show any sign of periportal fibrosis. King et al<sup>19</sup>, Vennervald et al<sup>32</sup>

and Prata (personal communication) also found high prevalence of portal dilatation in normal subjects. This could reduce its predictive value for assessing the risk of variceal bleeding, since the diameter of the portal vein correlates with portal pressure<sup>1</sup> and degrees of esophageal varices<sup>26-29</sup>.

In people with more advanced disease on US, the impaired criteria were qualitative, not quantitative, while in those with reversal of the disease, who were mostly young people, the improved criteria were quantitative and qualitative. The N-BH classification takes into account the image pattern of the liver parenchyma. It is possible that some subjectivity may influence the mild pathological changes found among patients with deterioration. In fact, the quantitative scores did not confirm the disease.

Organ measurement using the N-BH classification demonstrated a reduction in left hepatic lobe size, as well as in the spleen and gallbladder wall thickness, and also right hepatic lobe atrophy. This is the first time that this protocol has been used for evaluating the impact of treatment on hepatic morbidity. The advantage of this classification system is that it adjusts organ and vessel measurements for body height and also includes disease descriptions, since it incorporates the degree of fibrosis according to its location and extent within the liver. We believe that this protocol for US represents an important improvement in the recognition of periportal fibrosis associated with *Schistosoma mansoni* infection and that it may be used for evaluating and monitoring the control measures for morbidity in endemic areas. However, like King et al<sup>19</sup>, we think that this protocol requires further adjustments and simplification.

In our study, we tried to find the most useful markers for periportal thickening, in order to detect early forms of periportal fibrosis. For this reason, we included analysis of the D/d ratio that was proposed by Cerri and reported by Jenkins & Hatz<sup>15</sup>. This approach towards periportal thickening seems to be comparable with the approach proposed in the N-BH US classification (D-d). Both D/d and D-d may be more specific than D.

In general, the clinical findings improved in all cases but, unexpectedly among those with disease reversal, the liver measurements of the right hepatic lobe increased while the left hepatic lobe (MEC, MEL) reduced. Unless some hemodynamic factors are implicated, we do not have any rational explanation for this observation.

The impact of the treatment could probably be better evaluated in this area, where transmission had been interrupted, especially because in this area 70% of the individuals followed up were less than 20 years old, i.e. in the group at highest risk of water contact<sup>9</sup>. Even though the intensity of infection was low, the *Schistosoma mansoni* egg load in the liver among the present study group allowed the appearance of periportal disease in 9% of the infected individuals. Although this was not a case-control study, this group could have progressed to evident signs of portal hypertension if chemotherapy had not been given, considering that 5.1% of these individuals progressed to disease in spite of PZQ therapy.

In conclusion, for evaluating the effectiveness of treatment in areas with low parasite burden, US is a good approach for

evaluating morbidity, while coprological and immunological tests remain the best parameters for evaluating infection. On the other hand, clinical examination in these areas is less sensitive and specific, which diminishes its value at primary health centers unless it is accompanied by ultrasound examination. However, the current protocols have limitations, in spite of the improvements achieved with the latest protocol developed by WHO. A standard classification must be assumed, including height or body surface, in order to compare results between different studies and to overcome variables depending on the body changes within the same person such as growth or obesity.

## ACKNOWLEDGMENTS

We are very grateful to all persons from the endemic area who voluntarily participated in the present investigation.

## REFERENCES

- Andel-Latif Z, Abdel-Wahab F, El-Kady NM. Evaluation of portal hypertension in cases of hepatosplenic schistosomiasis using ultrasound. *Journal of Clinical Ultrasound* 9: 409-412, 1981.
- Abdel-Wahab MF, Esmat G, Milad M, Abdel-Razek S, Strickland GT. Characteristic sonographic pattern of schistosomal hepatic fibrosis. *American Journal of Tropical Medicine and Hygiene* 40: 72-76, 1989.
- Abdel-Wahab MF, Strickland GT. Abdominal ultrasonography for assessing morbidity from schistosomiasis 2. Hospital studies. *Transactions of the Royal Society of Tropical Medicine and Hygiene* 87: 135-137, 1993.
- Alarcón de Noya B, Colmenares C, Lanz H, Caracciolo MA, Losada S, Noya O. *Schistosoma mansoni*: Immunodiagnosis is improved by sodium metaperiodate which reduces cross-reactivity due to glycosylated epitopes of soluble egg antigen. *Experimental Parasitology* 95:106-112, 2000.
- Alarcón de Noya B, Ruiz R, Colmenares C, Losada S, Cesari IM, Toro J, Noya O. Schistosomiasis mansoni in areas of low transmission. *Epidemiological characterization of Venezuelan foci. Memórias do Instituto Oswaldo Cruz* 97 (supl 1): 5-10, 2002.
- Alarcón de Noya B, Spencer L, Noya O. Pre and post-treatment immunodiagnostic evaluation in human schistosomiasis mansoni. *Memórias do Instituto Oswaldo Cruz* 87: 271-276, 1992.
- Boisier P, Ramarokoto CE, Ravaoalimalala VE, Rabarijaona L, Serieye J, Roux J, Esterre P. Reversibility of *Schistosoma mansoni*-associated morbidity after yearly mass praziquantel therapy: ultrasonographic assessment. *Transactions of the Royal Society of Tropical Medicine and Hygiene* 92: 451-453, 1998.
- Burchard GD, Guissé-Sow F, Diop M, Ly A, Lanuit R, Gryseels B, Gressner AM. *Schistosoma mansoni* infection in a recently exposed community in Senegal: lack of correlation between liver morphology in ultrasound and connective tissue metabolites in serum. *Tropical Medicine and International Health* 3: 234-241, 1998.
- Butterworth AE. Immunological aspects of human schistosomiasis. *British Medical Bulletin* 54: 357-368, 1998.
- Cerri GG, Alves VAF, Magalhães A. Hepatosplenic schistosomiasis mansoni: Ultrasound manifestations. *Radiology* 153: 777-780, 1984.
- Doehring-Schwedtfeger E, Abdel-Rahim IM, Kardorff R, Kaiser C, Franke D, Schlake J, Richter J, Elsheikh M, Ali QM, Ehrlich JHH. Ultrasonographical investigation of periportal fibrosis in children with *Schistosoma mansoni* infection: reversibility of morbidity twenty-three months after treatment. *The American Journal of Tropical Medicine and Hygiene* 46: 409-415, 1992.
- Hatz CRF. The use of ultrasound in schistosomiasis. *Advances in Parasitology* 48: 225-284, 2000.
- Homeida M, Abdel-Gadir AF, Cheever AW, Bennett JL, Arbab BMO, Ibrahim SZ, Abdel-Salam IM, Dafalla AA, Nash TE. Diagnosis of pathologically confirmed Symmers' periportal fibrosis by ultrasonography: a prospective blinded study. *American Journal of Tropical Medicine and Hygiene* 38: 86-91, 1988.
- Homeida MA, Eltoum IA, Ali MM, Suliman SM, Elobied E A, Mansour M, Saad AM, Bennett JL. The effectiveness of annual versus biennial mass chemotherapy in reducing morbidity due to schistosomiasis: a prospective study in Gezira-Managil, Sudan. *American Journal of Tropical Medicine and Hygiene* 54: 140-145, 1996.
- Jenkins JM, Hatz C, Cairo Working Group. The use of diagnostic ultrasound in schistosomiasis –attempts at standardization of methodology. *Acta Tropica* 51: 45-63, 1992.
- Kardorff R, Gabone RM, Mugashe C, Obiga D, Ramarokoto CE, Mahler C, Spannbrucker N, Lang A, Günzler V, Gryseels B, Ehrlich JHH, Doehring E. *Schistosoma mansoni*-related morbidity on Ukerewe Island, Tanzania: clinical, ultrasonographical and biochemical parameters. *Tropical Medicine and International Health* 2: 230-239, 1997.
- Kardorff R, Mugashe C, Gabone RM, Mahler C, Doehring E. Diagnostic value of connective tissue metabolites in *Schistosoma mansoni* related liver disease. *Acta Tropica* 73: 153-164, 1999.
- Katz N, Chaves A, Pellegrino J. A simple device for quantitative stool thick-smear technique in schistosomiasis mansoni. *Revista do Instituto de Medicina Tropical de São Paulo* 14: 397-400, 1972.
- King CH, Magak P, Abdel-Salam E, Ouma JH, Kariuki HC, Blanton RE. Measuring morbidity in schistosomiasis mansoni: relationship between image patterns, portal vein diameter and portal branch thickness in large scale surveys using new WHO coding guidelines for ultrasound in schistosomiasis. *Tropical Medicine and International Health* 8: 109-117, 2003.
- Ohmae H, Tanaka M, Hayashi M, Matsuzaki Y, Kurosaki Y, Blas BL, Portillo GG, Sy OS, Irie Y, Yasuraoka K. Improvement of ultrasonographic and serologic changes in *Schistosoma japonicum*-infected patients after treatment with praziquantel. *American Journal of Tropical Medicine and Hygiene* 46: 99-104, 1992.
- Pinto-Silva RA, Abrantes WL, Antunes CME, Lambertucci JR. Sonographic features of portal hypertension in schistosomiasis mansoni. *Revista do Instituto de Medicina Tropical de São Paulo* 36: 353-361, 1994.
- Prata A. Como caracterizar a forma hepatoplênica da esquistossomose. *In: Resumos do II Simpósio sobre Esquistossomose; Salvador, p: 179-18, 1970.*
- Prata A, Andrade ZA. Fibrose hepática de Symmers sem esplenomegalia. *O Hospital* 63: 609-623, 1963.
- Pujol FH, Cesari IM. Antigenicity of adults *Schistosoma mansoni* alkaline phosphatase. *Parasite Immunology* 12: 189-198, 1990.
- Quarashi MA, Doehring-Schwedtfeger E, Abdel-Rahim IM, Schlake J, Kardorff R, Franke D, Kaiser C, Elsheikh M, Abdalla M, Schafer P, Ehrlich JHH. Ultrasonographical investigation of periportal fibrosis in children with *Schistosoma mansoni* infection: reversibility of morbidity seven months after treatment. *American Journal of Tropical Medicine and Hygiene* 44: 444-451, 1991.
- Richter J, Correia-Dacal AR, Siqueira JGV, Poggensee G, Mannsmann U, Deelder A, Feldmeier H. Sonographic prediction of variceal bleeding in patients with liver fibrosis due *Schistosoma mansoni* *Tropical Medicine and International Health* 3: 728-735, 1998.
- Richter J, Domingues ALC, Barata CH, Prata A, Lambertucci JR. Report of the Second Satellite Symposium on ultrasound in schistosomiasis. *Memórias do Instituto Oswaldo Cruz* 96 (supl 1): 151-156, 2001
- Richter J, Hatz C, Campagne G, Bergquist NR, Jenkins JM editors. Ultrasound in schistosomiasis. A practical guide to standardized use of ultrasonography for the assessment of schistosomiasis-related morbidity. World Health Organization, Geneva, Switzerland. TDR/STR/SCH/00.1, 2000.
- Richter J, Silva-Monteiro E, Moreira-Braz R, Abdalla M, Abdel-Rahim IM, Fano U, Huntgburth U, Feldmeier H. Sonographic organometry in Brazilian and Sudanese patients with hepatosplenic schistosomiasis mansoni and its relation to the risk of bleeding from esophageal varices. *Acta Tropica* 51: 281-290, 1992.
- Ruiz-Guevara R, Candia P, Garassini M, Tombazzi C, Certad G, Bruce AC, Losada S, Colmenares C, Noya O, Alarcón de Noya B. Schistosomiasis mansoni in low transmission areas. *Abdominal ultrasound. Memórias do Instituto Oswaldo Cruz* 97 (supl 1): 153-160, 2002.

31. Spencer L, Alarcón de Noya B, Noya O, Masroua O. Análisis comparativo entre la prueba de precipitación circumoval y ELISA con antígenos crudos para el diagnóstico de la esquistosomiasis en Venezuela. *Revista de la Sociedad Venezolana de Gastroenterología* 45: 77-83, 1991.
32. Vennervald BJ, Kenty LC, Butterworth AE, Kariuki CH, Kadzo H, Ireri E, Amaganga C, Kimani G, Mwatha J, Otedo A, Booth M, Ouma JH, Dunne DW. Detailed clinical and ultrasound examination of children and adolescents in a *Schistosoma mansoni* endemic area in Kenya: hepatosplenic disease in the absence of portal fibrosis. *Tropical Medicine and International Health* 9: 461-470, 2004.
33. Warren KS. The pathology, pathobiology and pathogenesis of schistosomiasis. *Nature* 273: 609-612, 1978.
34. Warren KS. The kinetics of hepatosplenic schistosomiasis. *Seminars in Liver Diseases* 4: 293-300, 1984.
35. World Health Organization. The control of schistosomiasis. Report of a WHO Expert Committee. WHO. Technical Report Series N° 728, Geneva, 1985.