



Case Report/Relato de Caso

Actinomycosis affecting the spinal cord: a case report

Actinomicose comprometendo a medula espinhal: um relato de caso

Maria Isabela Alves Ramos¹, Jair Almeida Carneiro², Fabiano de Oliveira Poswar², Daniella Cristina Nassau³ and Fernando Antônio Colares⁴

ABSTRACT

Actinomycosis is a rare, chronic, suppurative, granulomatous infection caused by a group of gram-positive anaerobic bacteria belonging to the natural flora of the oral cavity and gastrointestinal and urogenital tracts. It may involve several organs. This case study refers to pulmonary actinomycosis with chest wall involvement and cord compression in a 29-year-old male who presented with fever, cough, hemoptysis, neck pain, and paresis and plegia of the lower limbs of 5-month duration.

Keywords: Actinomycosis. Lung. Chest wall.

RESUMO

A actinomicose é uma infecção rara, crônica, supurativa e granulomatosa, causada por um grupo de bactérias anaeróbias Gram-positivas que pertencem à flora natural da cavidade oral, do aparelho gastrointestinal e urogenital. Pode envolver diversos órgãos. O estudo refere-se à actinomicose pulmonar com envolvimento da parede torácica e compressão medular em um paciente masculino com 29 anos que apresentava febre, tosse, hemoptise e cervicalgia, além de paresia e plegia em membros inferiores com cinco meses de evolução.

Palavras-chaves: Actinomicose. Pulmão. Parede torácica.

INTRODUCTION

Actinomycosis is a rare, suppurative, granulomatous disease that may involve several organs. It is more common in males (3:1) and in immunocompromised patients¹. It is a chronic infection caused by gram-positive anaerobic commensal bacteria (*Actinomyces*) that normally colonize the oral cavity and gastrointestinal and urogenital tracts². A total of 14 species have been identified, 6 of which are pathogenic to humans; the most common is *Actinomyces israelii*, followed by *A. naeslundii*, *A. odontolyticus*, *A. viscosus*, *A. meyeri*, and *A. gerencseriae*³. The risk factors include aspiration of oropharyngeal or gastrointestinal contents as well as poor hygiene and oral health. There is higher prevalence in chronic alcoholics and in patients with structural lung disease³. Five clinical forms have been described: cervicofacial (55%), abdominopelvic (20%), thoracic (15%), as well as in various organs (10%) due to hematogenous dissemination of occult lung injury, mimicking tumors in skin, brain, pericardium, and thighs⁴.

Chest wall involvement occurs in 12% of pulmonary cases^{4,5}. Actinomycosis can also invade the spinal canal and cause cord compression. This event is extremely rare and occurs in <5% of infections⁶.

This study reports a case of pulmonary actinomycosis with chest wall involvement and cord compression.

CASE REPORT

O.R.S., a 29-year-old man, was admitted with complaints of fever, cough, hemoptysis, urinary incontinence, neck pain, and paresis and plegia of the lower limbs for ~5 months.

The patient also reported alterations in bowel habits, which oscillated between bouts of diarrhea and constipation. At the time of ectoscopy, the patient was dehydrated and malnourished, with diffuse atrophy, edema in the lower limbs, and pressure ulcers over the sacrum, trochanters, and heels. The vital signs evidenced blood pressure of 110 × 75 mmHg, heart rate of 132 bpm, respiratory rate of 20 rpm, and temperature of 38.2 °C. Auscultation of the respiratory system revealed decreased breath sounds and diffuse rhonchi. Neurological examinations showed an absence of force, abolition of reflexes and sensation in the lower limbs, and no changes of the cranial nerves. The blood count showed anemia (hemoglobin, 6.5 g%) with an erythrocyte count of 2,420,000/mm³, hematocrit of 20.5%, total leukocyte count of 9,200/mm³, and platelet count of 312,000/mm³. He underwent blood cultures, urine culture, and serology for the human immunodeficiency virus, all of which yielded negative results; furthermore, purified protein derivative (PPD) tuberculin was not reactive.

A computed tomography (CT) scan (**Figure 1**) and magnetic resonance imaging (MRI) scan of the chest (**Figure 2**) revealed the presence of a nodular lesion in the right pulmonary apex and an infiltrative mass affecting the vertebral bodies, elements in the upper thoracic and lower cervical posterior arches, ribs, and paravertebral soft tissue, with involvement of the spinal canal. A third biopsy was performed in the right upper lung; pathology showed inflammation, suggestive of actinomycosis (**Figure 3**). Antibiotic therapy involving penicillin (5.0 × 10⁶ IU, every 4h for 2 months) and clindamycin (600mg, every 8h for 14 days) was initiated. The pressure ulcers were treated with papain and silver alginate. After 23 days of hospitalization in our hospital, the patient was transferred to another institution for surgical decompression of the spinal canal.

1. Curso de Medicina, Universidade Estadual de Montes Claros, Montes Claros, MG. 2. Programa de Pós-Graduação *Strictu Sensu* em Ciências da Saúde, Universidade Estadual de Montes Claros, Montes Claros, MG. 3. Hospital Universitário Clemente de Faria, Universidade Estadual de Montes Claros, Montes Claros, MG. 4. Departamento de Clínica Médica, Universidade Estadual de Montes Claros, Montes Claros, MG. **Address to:** Dr. Fabiano de Oliveira Poswar. Av Cula Mangabeira 562, Bairro Santo Expedito, 39401-001 Montes Claros, MG, Brasil.

Phone: 55 38 3224-8327

e-mail: faliwar@gmail.com

Received in 25/07/2011

Accepted in 14/12/2011

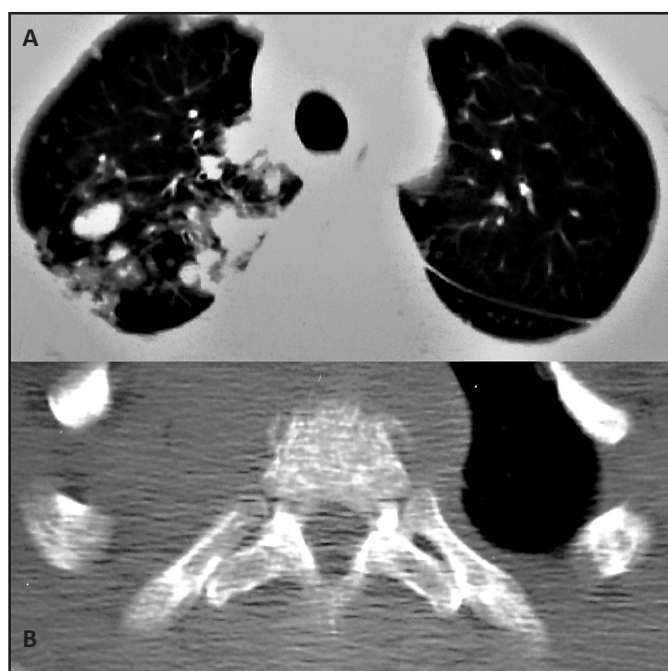


FIGURE 1 - Computed tomography scan. In the lung window (A), there is an evident infiltrative mass on the right lung apex. In the mediastinal window (B), the mass can be seen infiltrating the vertebral body of a thoracic vertebra.

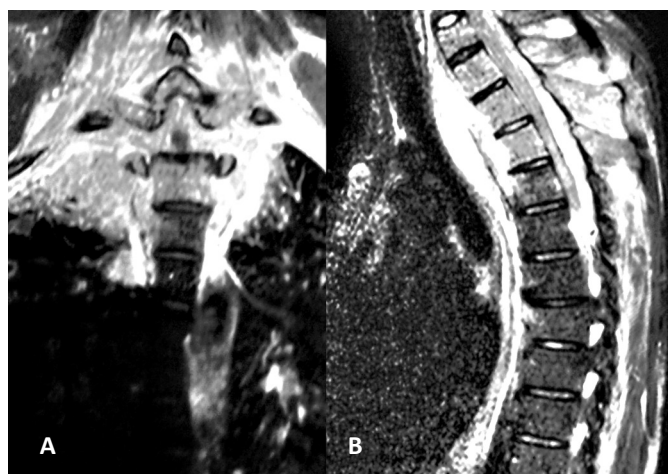


FIGURE 2 - Magnetic resonance imaging with coronal (A) and sagittal (B) reconstructions. The image shows an infiltrative mass that affected the vertebral bodies, elements of the upper thoracic and lower cervical posterior arches, ribs, and paravertebral soft tissue, with involvement of the spinal canal.

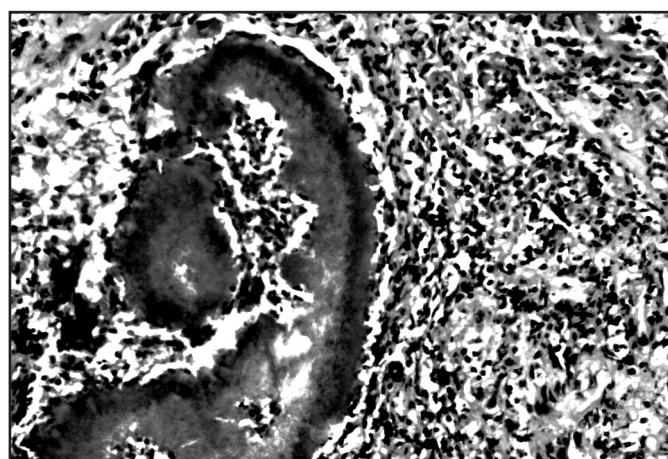


FIGURE 3 - Colony of *Actinomyces* sp.

DISCUSSION

Actinomycosis is a non-transmissible infection caused by human commensal microbes, which may be complicated by the action of other pathogens. Because of the rarity of actinomycosis, diagnosis and appropriate treatment may be postponed, leading to significant morbidity⁷. A reduction in the incidence of this disease may be related to improved oral hygiene and the proper use of antibiotics in infections by other agents⁸. Actinomycosis can affect individuals of all ages.

The patient under study was 29 years old and belonged to the age group most commonly affected by the disease, since the majority of cases involve adults aged between 20 and 50 years⁹. Actinomycetes are prevalent in the normal flora of the oral cavity but are less prominent in the lower gastrointestinal, respiratory, and urogenital tracts. These microorganisms are not virulent and require a break in mucosal integrity or the presence of devitalized tissue to invade other structures of the body and cause disease^{7,9}. Typically, the infection spreads contiguously, ignores anatomical planes, and invades surrounding tissues or adjacent organs. Hematogenous dissemination to distant organs can occur at any stage of infection, while lymphatic spread is uncommon.

Aspiration of oropharyngeal secretions containing actinomycetes is the usual mechanism of infection that leads to pulmonary actinomycosis. However, the disease can result from the introduction of microorganisms through the perforation of the esophagus by direct propagation of an infectious process in the neck or abdomen, and by hematogenous spread from a distant lesion. It presents as a pulmonary infiltrate or mass, which, if untreated, may involve the pleura, pericardium, and chest wall⁷.

Symptoms related to pulmonary disease are as follows: hemoptysis (42%), persistent cough (37%), and chest pain. The nonspecific symptoms are as follows: fever (28%), loss of appetite, weight loss, and anemia^{1,4}. Pulmonary actinomycosis is a difficult clinical diagnosis. Less than 10% of cases are diagnosed at initial presentation, finding themselves in situations such as differential diagnosis of lung abscess, tuberculosis, or lung neoplasm. This can lead to delays and even therapeutic and diagnostic errors, including conducting unnecessary surgery².

It is noted that in addition to paresis and plegia of the lower limbs for ~5 months, this patient expressed virtually every major nonspecific symptom of the disease and some of the symptoms related to pulmonary involvement, indicating rapid progression and aggressive disease with central nervous system involvement. Probably, the disease first affected the apex of the right lung and spread contiguously, involving the chest wall and then the paravertebral soft tissues, vertebral bodies, and spinal canal. A computed tomography (CT) scan is the best diagnostic test because it shows the degree of damage and related complications^{4,5}, while MRI is helpful in differentiating lesions infiltrating the chest wall⁴. These tests were helpful in the management of this case since they revealed the presence of a nodular lesion in the right pulmonary apex, an infiltrative mass affecting the vertebral bodies and elements of the upper thoracic and lower cervical posterior arches, ribs, and paravertebral soft tissue, with involvement of the spinal canal.

The definitive diagnosis of actinomycosis is obtained by biopsy (bronchoscopic, thoracoscopic, or open), pulmonary resection, or

drainage of an abscessed material that is gelatinous, dark with sulfur granules, similar to sand or yellowish, odorless, and interspersed with a winy content^{4,5}. The histological material obtained from a biopsy of the pulmonary right upper third of the patient showed an inflammatory process, suggestive of actinomycosis. This analysis enabled precise diagnosis of the case and choice of appropriate therapy. Treatment of pulmonary actinomycosis with chest wall involvement and cord compression consists of a combination of long-term antibiotic therapy and, if necessary, surgical resection of the lung and/or decompression of the spinal canal.

The antibiotic of choice is penicillin. In most cases, the antibiotic should be administered orally at the maximum tolerated dose. In severe or rapidly progressive cases, penicillin should be started intravenously at high doses ($10-20 \times 10^6$ IU/d). Other antibiotics can be used orally, namely, ampicillin, tetracycline, and clindamycin, with good therapeutic results¹⁰. Several authors suggest the use of intravenous penicillin G for 1 month, and then replaced by oral penicillin for 6-12 months, or by amoxicillin⁵. In patients allergic to penicillin, sulfonamides, clindamycin, erythromycin, and chloramphenicol can be used^{4,5}. The use of tetracycline and trimethoprim-sulfamethoxazole has also been described in the treatment of actinomycosis⁵. Actinomycosis has a high tendency to relapse, which is why the treatment should be extended for 6-12 months. The prognosis is excellent, with a cure rate of ~90% when the disease is diagnosed early and the antibiotics are effectively administered⁸.

The involvement of the spinal cord is extremely rare. We performed a search of the PubMed and Scopus databases with the keywords *actinomycosis* and *spinal cord*, and retrieved 25 published cases of actinomycosis with involvement of the spinal cord. Most patients share the same demographical characteristics of patients without cord compression, being mostly males (84.2%) and between 20 and 50 years of age (78.9%). In the majority of cases, the thoracic (47.6%) or cervical levels of the spine (28.6%) were affected. The entire spinal cord was affected in 1 case¹¹. For clinical history, fever (84.6%), pain (78.6%), and weight loss (60%) were frequently described. Neurological findings were variable, reflecting the extension of the cord compression. Actinomycosis of the central nervous system can be responsible for significant neurological sequelae. Nevertheless, complete resolution was described in 50% of the cases. The best results are probably associated with early treatment¹².

Actinomycosis provides a diagnostic challenge because it is a rare disease that presents with nonspecific symptoms, an insidious course, and a variety of clinical manifestations. Therefore, its diagnosis and appropriate treatment can be postponed, leading to significant morbidity. Pulmonary actinomycosis with chest wall involvement and cord compression, as evidenced in this study, shows rapid progression and can be considered an aggressive disease because the central nervous system is compromised.

REFERENCES

1. Fatureto MC, Oliveira PF, Almeida COR, Fernandes LHG. Actinomicose pulmonar com envolvimento da parede torácica. Rev Soc Bras Med Trop 2007; 40:82-85.
2. Marques AS, Lopes N, Guimarães M, Vera J, Monteiro M, Serrano I. Actinomicose pulmonar - A propósito de um caso clínico. Rev Port Pneumol 2007; 13:275-280.
3. Mabeza G, Macfarlane J. Pulmonary actinomycosis. Eur Respir J 2003; 21:545-551.
4. Zarca-Diaz de la Espina MAZ, Lopez-Menendez C, Ruiz-Martinez R, Molino-Trinidad C. Pulmonary actinomycosis with thoracic soft tissue mass: a rare onset form. Eur J Radiol 2001; 37:195-199.
5. Chouabe S, Perdu D, Deslée G, Milosevic D, Marque E, Lebagry F. Endobronchial actinomycosis associated with foreign body. Chest 2002; 121:2069-2072.
6. Espina MA, Lopez-Menendez C, Ruiz-Martinez R, Molino-Trinidad C. Pulmonary actinomycosis with thoracic soft tissue mass: a rare onset form. Eur J Radiol 2001; 37:195-199.
7. Moniruddin ABM, Begum H, Nahar K. Actinomycosis: An Update. Review Article. Med Today 2010; 22:43-47.
8. Gomes MJM, Sotto-Mayor R. Infecções respiratórias não tuberculosas. In: Gomes MJM, Sotto-Mayor R, editors. Tratado de Pneumologia da Sociedade, Vol. 1. Lisboa: SPP-Permanyer Portugal; 2003. p. 488-490.
9. Weese WC, Smith IM. A study of 57 cases of actinomycosis over a 36-year period. A diagnostic "failure" with good prognosis after treatment. Arch Intern Med 1975; 135:1562-1568.
10. Cheon JE, Im J, Lee J, Choi G, Yeon K. Thoracic actinomycosis: CT findings. Radiology 1998; 209:229-233.
11. Gaïni S, Røge BT, Pedersen C, Pedersen SS, Brenøe AS. Severe Actinomyces israelii infection involving the entire spinal cord. Scand. J Infect Dis 2006; 38:211-213.
12. Xu G-P, Xu ZD, Gao BL, Chen Q, Li QQ, Xu JD, et al. Cervical actinomycosis with spinal cord compression. Case report and literature review. Chemotherapy 2008; 54:63-66.