

Bilateral posterior circulation stroke secondary to a crotalid envenomation: case report

Thiago Cardoso Vale^[1], Alysson Ferreira Leite^[2], Priscila Ribeiro da Hora^[2],
Marayra Inês França Coury^[2], Ricardo Cipriano da Silva^[2]
and Antônio Lúcio Teixeira^[3]

[1]. Serviço de Neurologia, Hospital das Clínicas, Universidade Federal de Minas Gerais, Belo Horizonte, MG. [2]. Departamento de Clínica Médica, Hospital Júlia Kubitschek, Belo Horizonte, MG. [3]. Departamento de Clínica Médica, Faculdade de Medicina, Universidade Federal de Minas Gerais, Belo Horizonte, MG.

ABSTRACT

Snake bite envenoming is a disease with potential serious neurological complications. We report a case of an adolescent who was bitten by a rattlesnake and developed bilateral posterior circulation stroke. The rattlesnake was later identified as being *Crotalus durissus terrificus*. Stroke was probably due to toxic vasculitis or toxin-induced vascular spasm and endothelial damage.

Keywords: Stroke. Snake bite. Venom. *Crotalus durissus terrificus*.

INTRODUCTION

Snake bite envenoming is a neglected disease affecting millions of people living in the developing world¹. Serious neurological complications, including stroke and muscle paralysis, are related to the toxic effects of the venom². In a study of 309 patients bitten by *Bothrops* spp., Mosquera et al.³ reported cerebrovascular complications in 8 (2.6%) patients, being 7 hemorrhagic strokes and 1 ischemic stroke. Afibrinogenemia has been linked to rattlesnake bites and might explain the higher incidence of hemorrhagic strokes^{4,5}. This paper aims to report a patient who developed stroke secondary to a rattlesnake bite. Medical chart review was performed in a tertiary-care hospital in Belo Horizonte, Minas Gerais, Brazil.

CASE REPORT

A 16-year-old previously healthy Brazilian adolescent was victimized by a snake bite on his left foot while farming. Shortly after, he complained of mild localized erythema and pain, and was admitted to a community outpatient unit. He received antithrotophic serum six hours after the bite which was initially attributed to a Viperidae snake, more commonly seen in the region. He was discharged without any laboratory tests or observational period. On the following day, he was admitted to hospital due to somnolence, bilateral palpebral weakness and darkened urine as a result of myoglobinuria

with creatine phosphokinase levels at 390,000U/dL. Creatinine and potassium levels were high (2.3mg/dL and 6.0mg/dL, respectively) and progressively increased despite hydration and urine alcalinization. He was then submitted to hemodialysis and oro-intubation after having received 200ml (20 ampoules) of an intravenous crotalid antivenom after further description of the snake by the patient's relatives. After a week of intensive care and initial clinical and laboratory improvement, he developed diplopia, bilateral visual impairment and headache. Blood coagulation screens and ecocardiography were normal. Cranial computed tomography scan showed bilateral occipital ischemia with diffuse edema and intracranial hypertension. Brain magnetic resonance imaging confirmed a predominantly left temporo-occipital infarct with areas of ischemia in the pons and cerebellum, without any abnormalities in the magnetic resonance angiography (**Figure 1** and **2**). He was diagnosed as having a stroke (top-of-the-basilar syndrome) secondary to a rattlesnake bite later identified as being *Crotalus durissus terrificus*, identified by a physician expert on toxicology (Dr. A.F.L). The patient remained with a severe behavioral and cognitive impairment, with mini-mental state examination of 12/30 and prominent apathy. He also had gait difficulty due to spastic tetraparesis and tetrahyperreflexia, and an important visual compromise.

DISCUSSION

Ischemic stroke following a rattlesnake bite is very rarely reported in the literature. In a Brazilian study with 249 cases of rattlesnake bites, 99 out of 100 snakes classified as subspecies were *Crotalus durissus terrificus*. Most of the patients were male (80.7%), the superior limbs were bitten in 66.4% of the cases and the most frequent clinical manifestations were pain (61%), local edema (55%), palpebral ptosis (75.9%), myoglobinuria (38.6%) and myalgia (36.1%). Only one patient presented with ischemic stroke⁶.

Address to: Dr. Thiago Cardoso Vale. Serviço de Neurologia/HC/UFMG. Av. Professor Alfredo Balena 110, Bairro Santa Efigênia, 30130-100 Belo Horizonte, MG, Brasil.

Phone: 55 31 3409-9417

e-mail: thiagocardosovale@hotmail.com

Received 12 June 2012

Accepted 16 July 2012

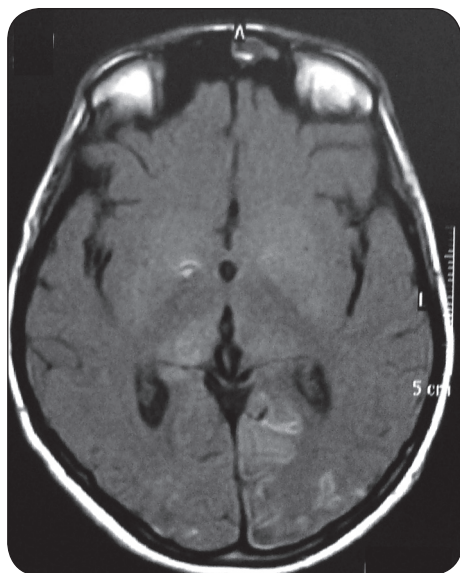


FIGURE 1 - Axial T1-weighted-sequenced, contrast enhanced, brain magnetic resonance imaging showing bilateral hyperintense lesions in the occipital lobes, with evident left predominance, and bilaterally in pulvinar nuclei of the thalamus.

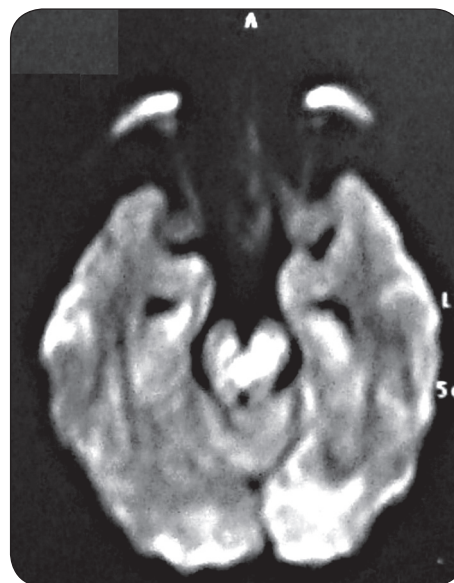


FIGURE 2 - Axial diffusion-weighted brain magnetic resonance imaging showing a bilateral occipital infarct and a central pontine hyperintense lesion.

There are several putative mechanisms by which cerebral infarction may occur in envenomation by snakes in general: a) hypotension due to hypovolemia from multiple causes, including sweating, vomiting, decreased fluid intake, increased vascular permeability due to systemic inflammatory response and bleeding, which leads to low flow state and watershed infarction; b) hypercoagulability due to procoagulants in the venoms or consumption coagulopathy phase of disseminated intravascular coagulopathy; c) adverse venom serum reaction, leading to vasculitis and thrombosis; d) endothelial injury due to toxic vasculitis⁷. Central nervous system edema and hemorrhage was reported in a few cases of crotalid envenomation^{2,4,5,8}, but the most common cause was progressive shock leading to multiorgan failure and death hours to a few days later. Edema is a result of the direct effect of the toxin on the integrity of the circulation and the microcirculation in particular⁸.

Our patient was young and without any vascular risk factors. He developed stroke symptoms delay of one week after the bite, but not explained by any hospital-associated complication. Magnetic resonance angiography and blood coagulation routine screen were normal. Together, these facts suggest that the cerebral infarction was the result of toxic vasculitis or toxin-induced vascular spasm and endothelial damage^{1,2,9,10}. A 24h delay in treatment might have contributed to worsen prognosis in our patient. Following snake bite, emphasis should be given

in the prompt treatment because the most important factor in determining survival following a severe envenomation is the amount of time elapsed between the bite and specific treatment.

REFERENCES

1. Warrell DA. Snake bite. *Lancet* 2010; 375:77-88.
2. Del Brutto OH, Del Brutto VJ. Neurological complications of venomous snake bites: a review. *Acta Neurol Scand* 2012; 125:363-372.
3. Mosquera A, Idrovo LA, Tafur A, Del Brutto OH. Stroke following *Bothrops* spp. snakebite. *Neurology* 2003; 60:1577-1580.
4. Amaral CF, Rezende NA, Pedrosa TM, Silva OA, Pedroso ER. Afibrinogenemia secondary to crotalid snake bite (*Crotalus durissus terrificus*). *Rev Inst Med Trop Sao Paulo* 1988; 30:288-292.
5. Amaral CF, Silva OA, López M, Pedroso ER. Afibrinogenemia following snake bite (*Crotalus durissus terrificus*). *Am J Trop Med Hyg* 1980; 29:1453-1455.
6. Jorge MT, Ribeiro LA. The epidemiology and clinical picture of an accidental bite by the South American rattlesnake (*Crotalus durissus*). *Rev Inst Med Trop Sao Paulo* 1992; 34:347-354.
7. Panicker JN, Madhusudhanan S. Cerebral infarction in a young male following viper envenomation. *J Assoc Physicians India* 2000; 48:744-745.
8. Kitchens C, Eskin T. Fatality in a case of envenomation by *Crotalus adamanteus* initially successfully treated with polyvalent ovine antivenom followed by recurrence of defibrinogenation syndrome. *J Med Toxicol* 2008; 4:180-183.
9. Bashir R, Jinkins J. Cerebral infarction in a young female following snake bite. *Stroke* 1985; 16:328-330.
10. Lee BC, Hwang SH, Bae JC, Kwon SB. Brainstem infarction following Korean viper bite. *Neurology* 2001; 56:1244-1245.