

# Clinical and serological outcomes with different surgical approaches for human hepatic hydatidosis

**Amr Abdelraouf<sup>[1]</sup>, Amany Ahmed Abd El-Aal<sup>[2]</sup>, Eman Yassin Shoeib<sup>[2]</sup>, Samar Sayed Attia<sup>[2]</sup>, Nihal Ahmed Hanafy<sup>[2]</sup>, Mohamed Hassani<sup>[3]</sup> and Soheir Shoman<sup>[3]</sup>**

[1]. Department of Surgery, National Hepatology and Tropical Medicine Research Institute, Cairo, Egypt. [2]. Department of Medical Parasitology, Faculty of Medicine, Cairo University, Egypt. [3]. Department of Tropical Medicine, National Hepatology and Tropical Medicine Research institute, Cairo, Egypt.

## ABSTRACT

**Introduction:** Hydatidosis is the result of infection with the larval stages of some species of the genus *Echinococcus*. Treatment approaches for hydatid cysts include the use of albendazole, surgery, and/or medico-surgical procedures. The choice of the therapeutic surgical approach depends on the cyst number and localization, surgeon expertise, and presence of complications. The present study aimed to compare the outcomes of the following therapeutic approaches for the treatment of hepatic hydatid cysts: pericystectomy; the puncture, aspiration, injection, and reaspiration (PAIR) technique; and the PAIR technique followed by deroofing, evacuation of cysts, and omentoplasty. **Methods:** The 54 patients were divided into 3 groups: Group I (14 patients) who underwent pericystectomy, Group II (23 patients) who underwent the PAIR technique, and Group III (17 patients) who underwent the PAIR technique followed by deroofing and omentoplasty. The diagnosis of hydatid cysts was based on serological testing using enzyme-linked immunosorbent assay, abdominal ultrasound, and parasitological examination of the cyst contents. Morbidity, mortality, length of hospital stay, recurrence, and postoperative complications were evaluated. **Results:** Postoperative bleeding, infection, and recurrence were reported in Groups I and II; Group III did not experience postoperative infection and had shorter hospital stays. Recurrence and postoperative complications did not occur in Group III. **Conclusions:** The partial surgical procedure with deroofing, evacuation of the cysts, and omentoplasty, as performed in the present study, is recommended as a safe and effective method for elimination of the entire parasite with minimal possibility for intra-peritoneal spillage.

**Keywords:** Hydatid cyst. Partial pericystectomy. PAIR technique. Deroofing.

## INTRODUCTION

Hydatidosis, or cystic echinococcosis, is one of the major global zoonotic infections<sup>(1)</sup>. Larval stages of *Echinococcus granulosus* develop in the internal organs of humans and various intermediate hosts as unilocular fluid-filled cystic lesions<sup>(2)</sup>. Hydatid cysts consist of an internal germinal layer and an outer laminated layer. The parasite cysts gradually expand and cause a granulomatous host reaction, followed by the development of a fibrous tissue layer<sup>(3)</sup>. Most primary infections consist of a single cyst and are usually asymptomatic for a long period of time because of the typically slow cyst growth. The cysts are usually localized in the liver (75% of cases), although other organs may be affected. The signs and symptoms of liver hydatidosis include hepatomegaly, right/epigastric pain, nausea and vomiting<sup>(4)</sup>.

Abdominal ultrasonography is considered the gold standard for defining the number, site, dimensions, and vitality of cysts as well as evaluating treatment options<sup>(5)</sup>. A definitive diagnosis of a hydatid cyst is confirmed by identification of protoscolices, refractile hooks, or fragments of a laminated membrane after surgery<sup>(6)</sup>.

Even in asymptomatic patients, probable complications can be avoided through treatment of the hydatid disease. There are three therapeutic modalities for hepatic hydatid cysts: chemotherapy; surgery (either open traditional or laparoscopic methods); and the puncture, aspiration, injection, and reaspiration (PAIR) technique<sup>(7)</sup>. A radical cystectomy and hepatectomy approach is the traditional mode of treatment; however, it results in prolonged hospitalization, a morbidity rate of 14-60%, and an overall mortality of up to 7.8%<sup>(8)</sup>. Operative procedures varying from complete resection to minimal invasive techniques have been developed, but the ideal treatment is still a matter of controversy<sup>(9) (10) (11)</sup>.

Instead of surgical removal, one recommended therapeutic procedure for hepatic hydatid cysts is the PAIR technique, which involves needle aspiration and concurrent chemotherapy<sup>(12)</sup> and satisfies all of the surgical goals for hydatid disease by sclerosing the germinal membrane and separating the laminated membrane with scolices<sup>(13)</sup>. However, the mainstay of therapy

**Corresponding author:** Dr. Samar Sayed Attia. Medical Parasitology Department/Faculty of Medicine. Cairo University, 12345, Cairo, Egypt.

**Phone:** 20 11 177-11839

**e-mail:** ssattia@kasralainy.edu.eg

**Received** 6 July 2015

**Accepted** 27 August 2015

currently consists of well-planned surgical techniques and appropriate procedures based on the correct evaluation of disease complications and performed by an experienced team, with adequate postoperative support<sup>(14)</sup>.

The present study aimed to investigate the clinical and serological outcomes of three treatment options for hepatic hydatid cysts: surgical removal of the cyst (pericystectomy), the PAIR technique, and the PAIR technique, followed by de-roofing, evacuation of the cysts, and omentoplasty.

## METHODS

The cohort consisted of 54 patients who presented with isolated hepatic hydatid cysts; were admitted to the Department of Surgery, National Hepatology and Tropical Medicine Research institute between 2007 and 2014; underwent one of the three different therapeutic interventions; and were followed for up to 7 years. The patients were divided into three groups according to the therapeutic approach: retrospective cohort of 14 patients who underwent radical surgical removal of the hepatic hydatid cysts (pericystectomy; data were collected from medical records); prospective cohort of 23 patients who underwent the PAIR technique; and prospective cohort of 17 patients who underwent the PAIR technique followed by de-roofing and evacuation of the cyst contents (used for large cysts  $\geq 5$ cm in diameter or a failed PAIR procedure). All of the patients were administered albendazole tablets at a dose of 400mg twice daily for two weeks to one month before the therapeutic procedure and for 6 months after therapy.

After collection of a detailed history and clinical examination, the preoperative diagnosis was based on ultrasonography and triphasic computed tomography, serological results in positive cases, and postoperative parasitological examination of cyst contents. During the abdominal ultrasound examination, the condition of the cysts (cyst size, site, number, contents, and wall as well as the surrounding liver parenchyma) and involvement of other organs were recorded. Although patients with hydatid cysts in other organs were excluded from this study, they were managed according to the institutional protocol in the corresponding department.

The following data were recorded for each admission: age; sex; clinical evaluation; imaging evaluation; number, size, and location of the cysts; previous surgery for liver hydatidosis; length of hospital stay; postoperative morbidity; postoperative mortality; and recurrence rates. Pre- and postoperative investigations included complete blood count, blood group typing, and liver function tests. During the follow-up, the residual cavity, possible infection, and recurrence were investigated.

### Follow-up

The prospective follow-up for Groups II and III was conducted twice a month for 3 months, followed by once a month for 1 year and every 3-6 months for the rest of the follow-up period.

## Surgical procedures

*Pericystectomy:* during the pericystectomy, the cyst was dissected along its boundary with healthy liver tissue. Blood vessels and small biliary structures passing through the plane between the normal liver tissue and cyst were clamped and divided.

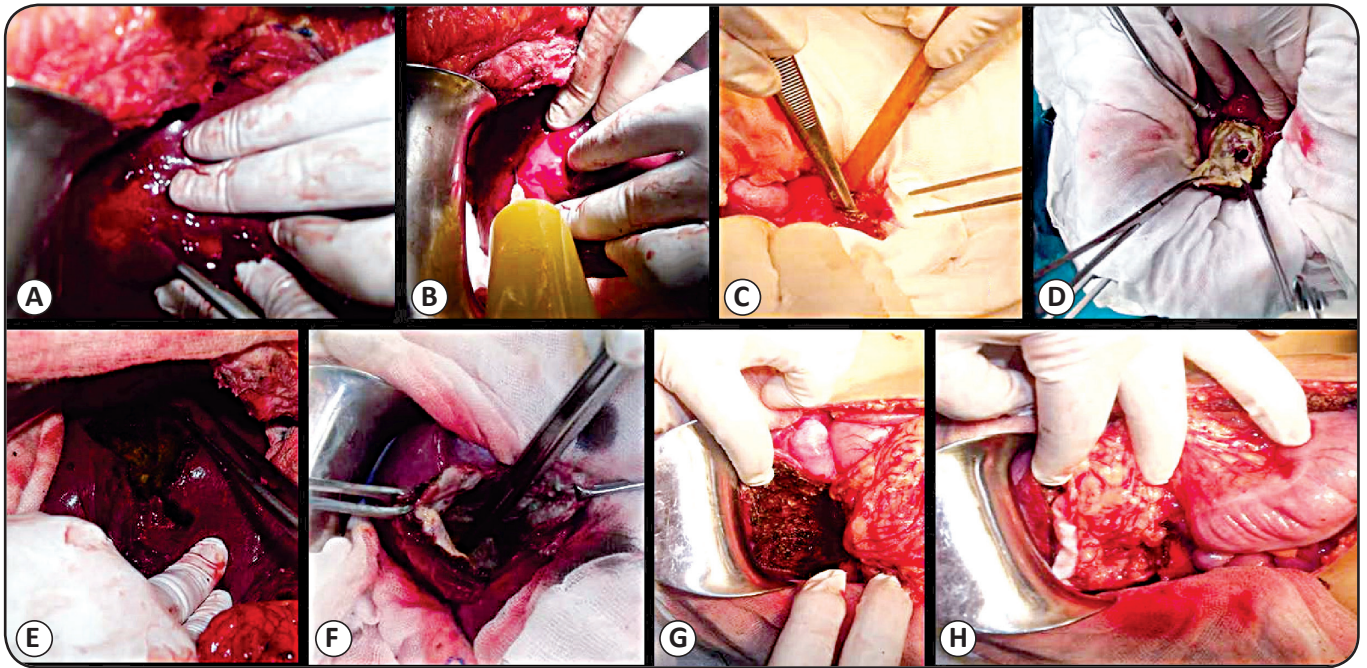
*PAIR technique:* the PAIR technique was conducted under local anesthesia, guided by ultrasound visualization, and involved puncture, aspiration of the cyst contents, injection of hypertonic saline solution  $\pm 100\%$  alcohol, and re-aspiration of all fluid (PAIR) for small cysts ( $< 5$ cm) or catheterization for large cysts ( $\geq 5$ cm). The initial puncture was performed using the free hand technique and an 18G needle using a trans-hepatic approach. All of the fluid in the cyst was aspirated, except for enough fluid to allow visibility of the needle tip, and tested using a dipstick test (Multistix SG; Bayer Diagnostics) for the presence of bile salts and pigments to rule out biliary communication<sup>(15)</sup>.

*Combined surgical procedure:* the PAIR technique was performed followed by de-roofing and evacuation of the cysts, as indicated in **Figure 1**, with modification<sup>(16)</sup>. With the patient in the supine position and under general anesthesia, an incision was made on the abdomen at the right sub-costal; this incision was either simple or extended to the double sub-costal or upper midline. The liver was assessed using routine intra-operative ultrasonography. The hepatic cystic lesion was identified and gradually isolated from both the surrounding abdominal wall incision and intra-abdominal visceral contents using dry towels first, followed by wet towels with normal saline, wet towels with 3% hypertonic saline, and wet towels with 16-20% hypertonic saline (**Figure 1A**). The affected segment was also isolated as described. Using a 10-mL syringe, the cyst was aspirated from the roof for parasitological examination (**Figure 1B**). A small, 2-3-mm incision allowed for introduction of the aspirator into the cyst (**Figure 1C**), and 16-20% hypertonic saline was injected after complete aspiration of the cyst contents. The opening was closed, and the hypertonic saline was aspirated after 5-7 minutes (**Figure 1D**). The process was repeated until the cyst contents were completely evacuated. The roof of the cyst was removed at the junction with the liver tissue using mono-polar diathermy, bi-polar diathermy, and a harmonic scalpel (**Figure 1E**).

The internal wall of the cyst was explored for biliary radical connections (**Figure 1F**). Minor biliary radical connections were ligated using Proline 3/0 or 4/0, depending on the size of the duct, and connections with major bile ducts were managed using intra-operative cholangiography. The internal wall of the cyst was then swabbed with hypertonic saline and Betadine; to completely destroy the floor and inside layer of the cyst, it was cauterized (**Figure 1G**) using mono-polar diathermy in both coagulation mode and spray mode. After completely destroying the entire cyst and reaching good homeostasis, the residual cavity of the cyst was packed with part of the omentum, and the cyst was closed with a nearby drain (**Figure 1H**).

### Parasitological examination

For direct parasitological examination, hepatic cysts removed surgically were macroscopically examined for size and shape; then, the cysts were dissected, and the layers were properly examined for the characteristic shape of the germinal layer.



**FIGURE 1:** A: Identification and fully separation of the cyst from the surrounding liver tissue, intra-abdominal structures and the abdominal wound. B: Aspiration of the cyst from the roof. C-D: Opening a small incision about 2-3mm to introduce the aspirator into the cyst under complete separation of the surrounding to start repeated aspirate & evacuations process for the cyst contents. E: After complete evacuation of the cyst's contents, removal of the roof of the cyst at the junction with the liver tissue, using both Mono-polar and Bi-polar diathermy. F: Identification of the floor and close perfect examination to identify any biliary radical connection. G: Cauterization of the floor to completely destroy the inside layer of the cyst. H: The residual cavity of the cyst was packed with the greater omentum (omentoplasty).

Aspirated fluids from operated or aspirated cysts were microscopically examined as wet unstained mounts and resuspended pellets after centrifugation at  $500\times g$  for 10 minutes to detect scolices or hooks (3-5 smears were examined for each sample).

#### Serological investigation

Serum samples were obtained before the therapeutic intervention and during the follow-up visits and tested for anti-hydatid antibodies using the anti-*Echinococcus* immunoglobulin G (IgG) human enzyme-linked immunosorbent assay (ELISA) Kit (Abcam, USA) according to the manufacturer instructions. Samples were diluted (1:100), added with controls to wells, and incubated at  $37^{\circ}\text{C}$  for 1 hour. Wells were washed, conjugate was added, and wells were incubated at room temperature for 30 minutes. After washing, 3,3',5,5'-tetramethylbenzidine (TMB) substrate was added to the wells and incubated at room temperature for 15 minutes. After incubation, stop solution was added, and absorbance values were measured at 450nm. Positive samples had absorbance values  $>1.3$ .

#### Statistical analysis

All data were statistically analyzed using Statistical Package for the Social Sciences (SPSS) version 16 for Windows (SPSS Inc., Chicago, IL, USA). Data are reported as mean values for quantitative variables and percentages for qualitative variables. Analysis of variance (ANOVA) and student's *t*-tests were used

to detect differences, and *p* values  $\leq 0.05$  were considered statistically significant.

#### Ethical considerations

Informed written consent was provided by each patient before inclusion, and the study was conducted according to the institutional ethical and professional guidelines for the management and follow-up of patients.

## RESULTS

The 54 patients with hepatic hydatid cysts (19 women, 35 men) were aged 22-54 years (mean, 34 years). As shown in **Table 1**, the predominant clinical presentation was abdominal pain [ $n = 45$  (83.3%);  $p < 0.05$ ].

**Table 1** shows that the pre-therapy ELISA was positive in 39 (72.2%) patients. Liver function was normal in all of the patients. After the therapeutic intervention, 5 (35.7%) patients in Group I had abnormal liver enzymes; none of the patients in Group II or III had changes in liver enzymes (**Table 2**).

The patients in Group I had significantly longer hospital stays (10-21 days) than the patients in Group II (1-2 days) or Group III (2-4 days;  $p < 0.001$ ). No biliary communication was observed in any of the patients.

**TABLE 1 - Clinical manifestations and investigations prior to surgical intervention for hepatic hydatid cysts.**

Main clinical manifestations and investigations	Cases	
	n	%
Abdominal pain	45	83.3
Allergic manifestations	9	16.7
Accidental discovery of a cyst	6	11.1
Eosinophilia	17	31.5
positive antibodies detected using by ELISA	39	72.2

ELISA: enzyme-linked immunosorbent assay.

**TABLE 2 - Pre- and postoperative data in patients who underwent treatment for hepatic hydatid cysts.**

	Group I (n = 14)	Group II (n = 23)	Group III (n = 17)
Preoperative data			
positive antibodies, per ELISA	10 (71.4%)	16 (69.6%)	13 (76.5%)
abnormal liver enzymes	none	none	none
Postoperative data			
positive antibodies, per ELISA (3 months after surgery)	14 (100%)	23 (100.0%)	17 (100.0%)
abnormal liver enzymes	5 (35.7%)	none	none
length of hospital stay (days)	10–21	1–2	2–4
postoperative bleeding	2 (14.3%)	none	none
postoperative wound infection	4 (28.6%)	3 (13.0%)	1 (5.9%)
number of drains	1 (3 patients)	0	2 (3 patients) 1 (14 patients)
recurrence	2 (14.3%)	8 (34.8%)	none
Mortality	3 (21.4%)	none	none

ELISA: enzyme-linked immunosorbent assay; PAIR: puncture, aspiration, injection, and reaspiration; **Group I:** pericystectomy; **Group II:** PAIR technique; **Group III:** PAIR technique followed by deroofting and evacuation of the cyst contents.

In Group I, postoperative bleeding occurred in 2 (14.3%) patients, and postoperative infection occurred in 4 (28.6%) patients. Recurrence occurred in 2 (14.3%) patients, and 3 (21.4%) patients died shortly after the operation due to anaphylactic shock resulting from ruptured cysts. In Group II, recurrence occurred in 8 (34.8%) patients; in Group III, no recurrence occurred.

In Group III, two drains were placed in the wounds of 3 (17.6%) patients, and one drain was maintained in the wounds of the remaining 14 (82.4%) patients. The average duration of draining was 3 days (range, 2–4 days). No serious complications or life-threatening conditions were reported in any of these 17 patients. Postoperative wound infection was recorded in one (5.8%) patient in Group III, 4 (28.6%) patients in Group I, and 3 (13%) patients in Group II.

The parasitological examination revealed spherical cysts ranging from 5.3 × 6.8 to 11.2 × 13.4 cm in diameter; the differences in cysts sizes between the groups were not significant. The characteristic shape of the germinal layer was observed, and aspiration of the cyst contents revealed colorless, clear, and gelatinous fluid. Protoscolices of *E. granulosus* were observed on microscopic examination of the aspirated cyst contents.

## DISCUSSION

In the present study, the partial procedure (Group III) was superior to the radical surgical procedures, with less morbidity and mortality and shorter hospital stays. Rupture of hydatid cysts can lead to anaphylaxis or dissemination<sup>(17) (18)</sup>. Secondary infection and pressure to nearby organs after reaching remarkable sizes were observed as well. Avoidance of probable complications can be achieved by early diagnosis and treatment of hydatid disease even in asymptomatic cases<sup>(19)</sup>.

In general, the diagnosis of a hydatid infection requires a variety of laboratory investigations and imaging techniques to confirm the clinical suspicion. The results of serological examinations for specific antibodies need to be constantly linked to different diagnostic parameters, and negative serological tests do not exclude an infection with a hydatid cyst<sup>(20)</sup>. This is supported by the present findings, as only 39 (72.2%) of the 54 patients had positive ELISA results. Because the results of immunological diagnostic methods vary, they are insufficient as a single test for definitive diagnosis<sup>(21)</sup>. In the present study,

a definitive diagnosis of hydatid cyst was confirmed by direct parasitological examination and identification of protoscolices and refractile hooks.

Therapeutic options for cystic echinococcosis are surgery, chemotherapy, and interventional procedures<sup>(22)</sup>. The majority of investigators recommend the use of albendazole prior to any surgical intervention<sup>(11)</sup> to facilitate safe surgical manipulation because albendazole inactivates protoscolices, changes the integrity of cystic membranes, reduces intra-cystic pressure, and reduces the turgidity of the cysts. A good response was achieved with medical treatment in only 30% of 1,000 patients with a hydatid cyst, the cyst decreased in size in 30-50% of the patients, and no changes were reported in 20-40% of the patients<sup>(22)</sup>. However, albendazole has been found ineffective in many patients<sup>(23)</sup>.

The recommended regimen of albendazole administration was followed in the present study: 400mg twice daily for at least two weeks before the procedure and for 6 months after surgery<sup>(24)</sup>. Administration of albendazole can minimize the risk of the intra-operative spread of scolices and reduce the risk of possible recurrence<sup>(25) (26)</sup>.

Surgical techniques for the treatment of hepatic hydatid cysts range from hepatic resection to simple cyst evacuation and partial pericystectomy. These procedures eventually eradicate the entire parasite, resulting in a complete cure without recurrence. However, the technical procedures remain controversial<sup>(27)</sup>.

Although simple to perform, conservative operations have been criticized for a high frequency of postoperative bile leaks and disease recurrence<sup>(28)</sup>. Similarly, recurrence was recorded in 8 patients who underwent the PAIR technique in the present study. Although some authors state that the PAIR technique is contraindicated due to potential anaphylaxis and spillage of scolices<sup>(12)</sup>, other investigators have reported neither anaphylaxis nor dissemination with the PAIR technique<sup>(29)</sup>.

In the present study, mortality and morbidity occurred in 21.4% and 28.6%, respectively, of patients in Group I, who underwent radical pericystectomy. Similarly, overall morbidity of 20% in patients who underwent total pericystectomy and hepatic resection was reported previously<sup>(30)</sup>. As in the present study, most of the reported deaths in previous studies resulted from postoperative septic complications and anaphylaxis<sup>(31)</sup>.

No mortality and significantly lower rates of morbidity were reported for Group III. Therefore, mortality and morbidity were remarkably higher with the radical procedures than with the conservative surgical option. A previous meta-analysis reported rates for mortality of 2%, morbidity of 23%, and recurrence of 10.4% with radical operations<sup>(27)</sup>, and the authors suggested that procedures that remove the parasite and retain the pericyst are easier to conduct than radical methods. Moreover, many surgeons consider that the radical methods are too radical for a benign disease<sup>(11)</sup>.

Compared with radical procedures, conservative procedures have a higher possibility of recurrence, occurring in 10-30% of patients, which remains one of the most significant problems

with surgery for hydatid cysts<sup>(32) (33) (34)</sup>. When recurrent disease occurs, additional surgeries are likely associated with increased rates of operative morbidity and mortality<sup>(35)</sup>. Recurrence occurs due to inadequate cyst removal or previously undetected cysts<sup>(36)</sup>.

In the current study, no recurrence of cysts was reported during the 7-year follow-up period for the 17 patients in Group III, who underwent a partial cystectomy and omentoplasty. During this procedure, the diagnosis was confirmed differently, to avoid leakage and sterilize the cyst contents before opening the cystic lesion. In addition to the preoperative medical treatment, PAIR technique, and parasitological diagnostic procedure, the surgeons performed intra-operative aspiration and injection of a scolicial agent following strict isolation of the abdominal wall and viscera using operative packs soaked with the scolicial agent.

The application of the dry operative packs, followed by the gradual increase in the concentration of the scolicial agent within the packs in the present study might explain the absence of the systemic or local toxicity that has been reported previously with the use of formalin<sup>(17)</sup> or formalin, ethanol, hypertonic saline, and silver nitrate, which resulted in adhesions using cetrimide and sclerosing cholangitis<sup>(37)</sup>. Furthermore, the partial cystectomy and omentoplasty helped to avoid biliary fistula.

The length of hospital stay was significantly longer with the radical procedure than with the other techniques. The length of hospital stay generally differs based on the technique; the stay is reportedly 1-4 days with a percutaneous approach<sup>(11)</sup> and 6-15 days with surgical treatment<sup>(15) (37) (38)</sup>.

To monitor remaining or relapsing hydatid cysts, ELISA or other serological techniques are considered useful not only for diagnosis but also for the post-surgical follow-up period<sup>(39)</sup>. In the present study, assessment of serum anti-hydatid antibodies using ELISA resulted in positive readings during the postoperative follow-up period, limiting its usefulness for postsurgical monitoring. Similarly, different immunoglobulin isotypes were detected 3 years after surgical removal of cysts in patients showing no evidence of remaining cysts<sup>(40) (41)</sup>.

In conclusion, although hydatid disease remains a significant public health problem, it is neglected in endemic areas such as Egypt. The diagnostic approach to hepatic hydatid disease should involve a combination of imaging and laboratory techniques and serological analysis. Chemotherapy alone is not sufficient for the treatment of hydatidosis; instead, it should be combined with the preferred surgical option because it helps to reduce recurrence related with spillage of the cyst contents during interventions. The main goal of the treatment should be parasite elimination, without recurrence and with minimal morbidity and mortality. Although surgical procedures are considered the gold standard therapeutic option for hydatidosis, controversy remains regarding the optimal surgical approach. In the present study, the partial surgical procedure was the most efficient technique and appears to be a safe, simple, and effective technique that meets all of the criteria for surgical treatment of hydatid disease, including elimination of the entire parasite without destruction of healthy tissue and precautions that prevent intraoperative spillage.

**CONFLICT OF INTEREST**

The authors declare that there is no conflict of interest.

**REFERENCES**

- Lawn SD, Bligh J, Craig PS, Chiodini PL. Human cystic echinococcosis: evaluation of post-treatment serologic follow-up by IgG subclass antibody detection. *Am J Trop Med Hyg* 2004; 70:329-335.
- Zhang W, Li J, McManus DP. Concepts in Immunology and Diagnosis of Hydatid Disease. *Clin Microbiol Rev* 2003; 16:18-36.
- Thompson RC, McManus DP. Aetiology: parasites and life cycles. *In: Eckert J, Gemmell M, Meslin FX, Pawlowski Z, editors. WHO/OIE manual on echinococcosis in humans and animals: a public health problem of global concern. Paris: World Organisation for Animal Health; 2001. p. 1-19.*
- Nunnari G, Pinzone MR, Gruttadauria S, Celesia BM, Madeddu G, Malaguarnera G, et al. Hepatic echinococcosis: Clinical and therapeutic aspects. *World J Gastroenterol* 2012; 18:1448-1458.
- Pawlowski Z, Eckert J, Vuitton DA, Ammann RW, Kern P, Craig PS. Echinococcosis in humans: clinical aspects, diagnosis and treatment. *In: Eckert J, Gemmell MA, Meslin FX, Pawlowski Z, editors. WHO/OIE Manual on Echinococcosis in humans and animals. Paris: Office International des Epizooties; 2001. p. 20-71.*
- Fraiji EK, Connor DH. Echinococcosis. *In: Connor DH, Chandler FW, Schwartz DA, Manz HJ, Lack EE, editors. Pathology of infectious disease. Stamford: Appleton & Lange; 1997. p. 1405-1413.*
- Brunetti E, Kern P, Vuitton DA. Expert consensus for the diagnosis and treatment of cystic and alveolar echinococcosis in humans. *Acta Trop* 2010; 114:1-16.
- Ekrami Y. Surgical treatment of hydatid disease of the liver. *Arch Surg* 1976; 111:1350-1352.
- Khuroo MS, Wani NA, Javid G, Khan BA, Yattoo GN, Shah AH, et al. Percutaneous drainage compared with surgery for hepatic hydatid cysts. *N Engl J Med* 1997; 337:881-887.
- Alferi S, Doglietto GB, Pacelli F, Costamagna G, Carriero C, Mutignani M, et al. Radical surgery for liver hydatid disease: a study of 89 consecutive patients. *Hepatogastroenterol* 1997; 44:496-500.
- Akkucuk S, Aydogan A, Ugur M, Yetim I, Davran R, Oruc C, et al. Comparison of surgical procedures and percutaneous drainage in the treatment of liver hydatid cysts: a retrospective study in an endemic area. *Int J Clin Exp Med* 2014; 7:2280-2285.
- Smego Jr RA, Sebango P. Treatment options for hepatic cystic echinococcosis. *Int J Infect Dis* 2005; 9:69-76.
- Bastid C, Azar C, Doyer M, Sahel J. Percutaneous treatment of hydatid cysts under sonographic guidance. *Diag Dis Sci* 1994; 39:1576-1580.
- Prousalidis J, Kosmidis C, Anthimidis C, Fachantidis E, Harlaftis N, Aletras H. Forty-four years' experience (1963-2006) in the management of primarily infected hydatid cyst of the liver. *HPB* 2008; 10: 18-24.
- Rajesh R, Dalip DS, Anupam J, Jaisiram A. Effectiveness of puncture-aspiration-injection-reaspiration in the treatment of hepatic hydatid cysts. *Iran J Radiol* 2013; 10:68-73.
- Sayek I, Yalin R, Sanaç Y. Surgical treatment of hydatid disease of the liver. *Arch Surg* 1980; 115:847-850.
- Kouraklis G, Dosios T, Glinavou A, Kouvaraki M, Karatzas G. An alternative approach for the surgical management of hydatid disease of the liver. *Langenbecks Arch Surg* 2001; 386:62-64.
- Polat FR. Hydatid cyst: open or laparoscopic approach? A retrospective analysis. *Surg Laparosc Endosc Percutan Tech* 2012; 22: 264-266.
- Giorgio A, Di Sarno A, de Stefano G, Liorre G, Farella N, Scognamiglio U, et al. Sonography and clinical outcome of viable hydatid liver cysts treated with double percutaneous aspiration and ethanol injection as first-line therapy: efficacy and long-term follow-up. *AJR Am J Roentgenol* 2009; 193:W186-W192.
- Ciobanca PT, Junie ML. Diagnosis confirmation of human cystic echinococcosis by imagistic methods and immunoserological determinations. *Sci Parasitol* 2001; 12:151-161.
- Ignatov V, Shterev S, Tonev A, Kolev N, Encheva E, Zlatarov A, et al. Diagnostics of liver hydatid disease. *Scripta Scientifica Medica* 2014; 46:37-40.
- Kapan S, Turhan AN, Kalayci MU, Alis H, Aygun E. Albendazole is not effective for primary treatment of hepatic hydatid cysts. *J Gastrointest Surg* 2008; 12:867-871.
- Tappe D, Stich A, Frosch M. Emergence of polycystic neotropical echinococcosis. *Emerging Infect Dis* 2008; 14:292-297.
- Center for Disease Control and Prevention. (CDC). Echinococcosis Treatment Information. November 29, 2013. Retrieved 20 March 2014. *The Medical Letter (Drugs for Parasitic Infections)*. CDC; 2013.
- Wen H, New RRC. Diagnosis and treatment of human hydatidosis. *Br J Clin Pharmacol* 1993; 35:565-574.
- Smego Jr RA, Bhatti S, Khaliq AA, Beg MA. Percutaneous aspiration-injection-reaspiration drainage plus albendazole or mebendazole for hepatic cystic echinococcosis: a meta-analysis. *Clin Infect Dis* 2003; 37:1073-1083.
- Buttenschoen K, Buttenschoen C. Echinococcus granulosus infection: the challenge of surgical treatment. *Langenbecks Arch Surg* 2003; 388:218-230.
- Agarwal S, Sikora SS, Kumar A, Saxena R, Kapoor VK. Bile leaks following surgery for hepatic hydatid disease. *Indian J Gastroenterol* 2005; 24:55-58.
- Yasawy MI, Mohammed AE, Bassam S, Karawi MA, Shariq S. Percutaneous aspiration and drainage with adjuvant medical therapy for treatment of hepatic hydatid cysts. *World J Gastroenterol* 2011; 17:646-650.
- Birnbaum DJ, Hardwigsen J, Barbier L, Bouchiba N, Le Treut YP. Is hepatic resection the best treatment for hydatid cyst? *J Gastrointest Surg* 2012; 16:2086-2093.
- Alonso Casado O, Moreno González E, Loínaz Seguro C, Gimeno Calvo A, González Pinto I, Pérez Saborido B, et al. Results of 22 years of experience in radical surgical treatment of hepatic hydatid cysts. *Hepatogastroenterol* 2001; 48: 235-243.
- Yagci G, Ustunsoz B, Kaymakcioglu N, Bozlar U, Gorgulu S, Simsek A, et al. Results of surgical, laparoscopic, and percutaneous treatment for hydatid disease of the liver: 10 years experience with 355 patients. *World J Surg* 2005; 29:1670-1679.
- Safioleas MC, Misiakos EP, Kouvaraki M, Stamatakos MK, Manti CP, Felekouras ES. Hydatid disease of the liver: a continuing surgical problem. *Arch Surg* 2006; 141:1101-1108.
- El Malki HO, El Mejdoubi Y, Souadka A, Zakri B, Mohsine R, Ifrine L, et al. Does primary surgical management of liver hydatid cyst influence recurrence? *J Gastrointest Surg* 2010; 14:1121-1127.
- Symeonidis N, Pavlidis T, Baltatzis M, Ballas K, Psarras K, Marakis G, et al. Complicated liver echinococcosis: 30 years of experience from an endemic area. *Scand J Surg* 2013; 102:171-177.

36. Ammann RW, Eckert J. Cestodes. Echinococcus. Gastroenterol Clin North Am 1996; 25:655-689.
37. Mastrandrea S, Stegel G, Piseddu T, Ledda S, Masala G. A retrospective study on burden of human echinococcosis based on Hospital Discharge Records from 2001 to 2009 in Sardinia, Italy. Acta Tropica 2012; 123:184-189.
38. Rozanes I, Guven K, Acunas B, Emre A. Cystic echinococcal liver disease: new insights into an old disease and an algorithm for therapy planning. Cardiovasc Intervent Radiol 2007; 30:1112-1116.
39. Dessaint JP, Bout D, Wattré P, Capron A. Quantitative determination of specific IgE antibodies to *Echinococcus granulosus* and IgE levels in sera from patients with hydatid disease. Immunology 1975; 29:813-823.
40. Bulut V, Ilhan F, Yucel AY, Onal S, Ilhan Y, Godekmerdan A. Immunological Follow-up of Hydatid Cyst Cases. Mem Inst Oswaldo Cruz 2001; 96:669-671.
41. Doiz O, Benito R, Gil J, Rojas A, Rubio MC, Osuna A. Pre- and post-surgical detection of IgG, IgM, and IgA specific to hydatidosis by ELISA with purified antigen enriched with the 5/B antigen complex. J Clin Lab Anal 2002; 16:295-298.