

## Case Report

# Schistosomal Myeloradiculopathy - A case report

**Maria Aparecida da Silva<sup>[1]</sup>, Gisele Alborghetti Nai<sup>[2]</sup>, Nair Toshiko Tashima<sup>[1]</sup>,  
Flávia Noris Chagas<sup>[1]</sup>, Suellen Marmoutelo Basso<sup>[3]</sup>, Ana Cláudia Ferreira Geraldini<sup>[3]</sup>,  
Renata Janeiro Marques<sup>[3]</sup> and Thaís Dante Correia Rocha<sup>[3]</sup>**

[1]. Departamento de Parasitologia, Universidade do Oeste Paulista, Presidente Prudente, SP, Brasil.

[2]. Departamento de Patologia, Universidade do Oeste Paulista, Presidente Prudente, SP, Brasil.

[3]. Faculdade de Medicina, Universidade do Oeste Paulista, Presidente Prudente, SP, Brasil.

### Abstract

The most common neurological impairments related to schistosomiasis involve the lower portions of the medulla and the cauda equina. A 22-year-old woman, with no history, signs, or symptoms of hepatointestinal schistosomiasis, presented with lumbar pain associated with acute paresthesia and paresis of the right lower limb. Spinal schistosomiasis was suspected based on the disease progression and radiological findings, and the diagnosis was confirmed after cerebrospinal fluid analysis. The authors emphasize this pathology as important as a differential diagnosis in similar clinical scenarios, especially in endemic areas, because both early diagnosis and treatment are essential to avoid permanent sequelae.

**Keywords:** Schistosomiasis. Nervous system diseases. Parasitic diseases.

### INTRODUCTION

Schistosomiasis is a parasitic disease caused by helminths that belong to the genus *Schistosoma*<sup>1</sup>.

The central nervous system (CNS) becomes involved when the eggs or adult worms reach the cerebral or spinal parenchyma or the subarachnoid space<sup>2</sup>.

Early recognition and treatment of this disease is fundamental in the prevention of serious and irreversible injuries, and for patient recovery<sup>3,4</sup>.

The purpose of this report is to bring the attention of the physicians to investigate the possibility of spinal schistosomiasis in patients with lumbar pain associated with acute onset of paresis and/or paresthesia of the lower limbs.

### CASE REPORT

A 22-year-old woman presented with severe pain in the lumbar region that radiated to the right lower limb associated

with acute paresthesia, which was observed mainly in the path of the L5-S1 spinal nerves.

Magnetic resonance imaging (MRI) of the lumbar spine did not reveal any remarkable alterations.

Due to worsening of the condition, laboratory tests, electromyography, and additional MRI of the lumbosacral spine were performed. A complete blood count (CBC) showed 8% eosinophils and an erythrocyte sedimentation rate of 28 mm in the 1<sup>st</sup> hour. Other tests showed negative results, and no changes were observed from the electromyography or MRI.

The patient progressed to hyporeflexia of the calcaneal and patellar tendons as well as decreased motor function; right knee pain; “burning” pain in the right foot; pain in the lateral region of the calf; calcaneal and pelvic pain when moving; plantar rigidity; hypoesthesia in the dorsal and lateral regions of the right foot; and increase in intensity of paresthesia. The patient was prescribed an opioid, a muscle relaxant, pyrimidine ribonucleotides, and a GABA analog, which provided partial pain relief.

However, a recent lower limb electroneuromyography showed discrete signs of recent denervation in the paravertebral musculature, usually suppressed by L5-S1, and a prolonged and dispersed H reflex, which implied a nerve root involvement in this segment.

**Corresponding author:** Maria Aparecida da Silva.

**e-mail:** masilva7@gmail.com

**Orcid:** 0000-0002-9598-3796

**Received** 22 August 2018

**Accepted** 19 March 2019

A new MRI of the spine was performed a month later, which revealed signs of alteration in the medullary cone with contrast enhancement, as well as in some roots of the cauda equina (**Figure 1**).

A cerebrospinal fluid (CSF) examination showed: red blood cells, 106/ $\mu$ L; leukocytes 20/ $\mu$ L; glucose, 51 mg/dL; and protein, 104 mg/dL. Immunological examination for schistosomiasis in the liquid was positive, and the serum test was negative. Parasite eggs were not observed in the feces and a total abdominal ultrasonography revealed abdominal organs without changes.

A theoretical diagnosis of medullary schistosomiasis was assumed, and treatment was started with dexamethasone and a single dose of praziquantel. Therapy with dexamethasone, opioids, and the muscle relaxant was continued.

A lumbosacral MRI performed after a month of treatment showed no signal alteration, additionally, the contrast enhancement was reduced in the medullary cone, with only slight contrast enhancement remaining in some roots of the cauda equina (**Figure 2**).

However, the symptoms persisted, and a new CSF screening showed a CBC of 16 cells/ $\text{mm}^3$  and predominance of lymphocytes, a moderate protein increase and 6.5 IU adenosine deaminase (ADA). IgG antibodies to *S. mansoni* were detected by enzyme-linked immunoassay, immunofluorescence, and hemagglutination serological methods.

After improvement in the CSF parameters mentioned and after several months of treatment with oral corticosteroid, the corticosteroid dose was tapered down due to exacerbated side effects, including osteonecrosis in both the knees; therefore, treatment with gabapentin and opioids remained.

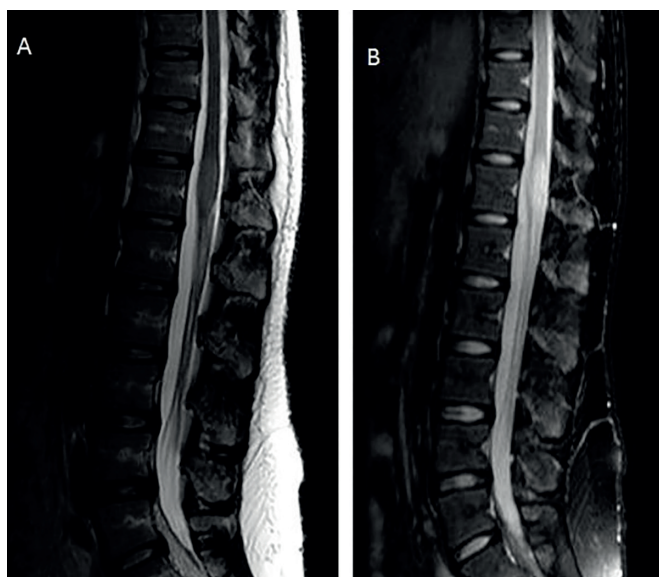The patient symptoms improved such as intermittent low-intensity pain, normalization of the patellar reflex, and progressive improvement of hypoesthesia in the thigh and calf, however, hypoesthesia and hyporeflexia remained in the right foot as well as decreased motor function in the calcaneal tendon. Six months after the end of the treatment, a lumbosacral MRI was performed, showing complete disappearance of the contrast enhancement in the roots of the cauda equina (**Figure 3**).

The patient had signed the Informed Consent Term, authorizing the disclosure of her clinical case. This report was approved by the Research Ethics Committee of *Universidade do Oeste Paulista - CEP UNOESTE* (CAAE nº 87647518.3.0000.5515).

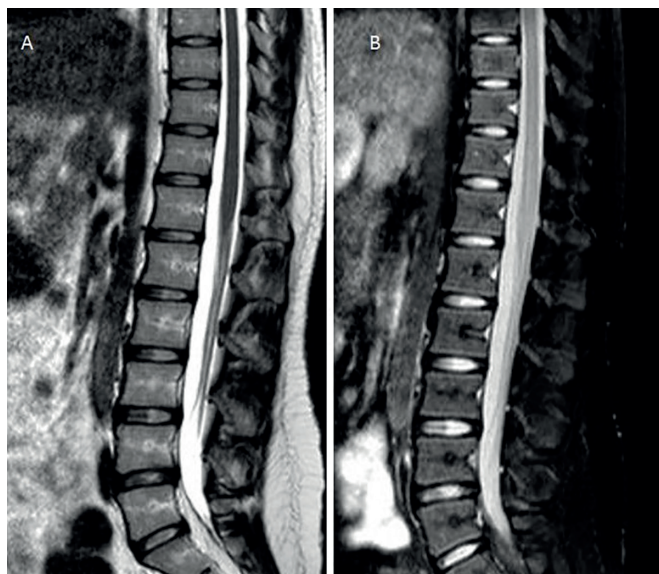
## DISCUSSION

The diagnosis of schistosomiasis myeloradiculopathy (EMR) is based on the presence of neurological symptoms, by parasitological or serological techniques and on the exclusion of other causes of myelopathy. Myeloradiculopathy occurs most frequently in the acute and chronic intestinal verminoses, where eggs and/or worms can travel through the Batson plexus, reaching the CNS through local oviposition or embolization<sup>4,5</sup>.

Neurological symptoms are not exclusively due to mechanical depositing of the eggs and the secondary formation of granulomas in the nervous tissue, because both immunoallergic response of

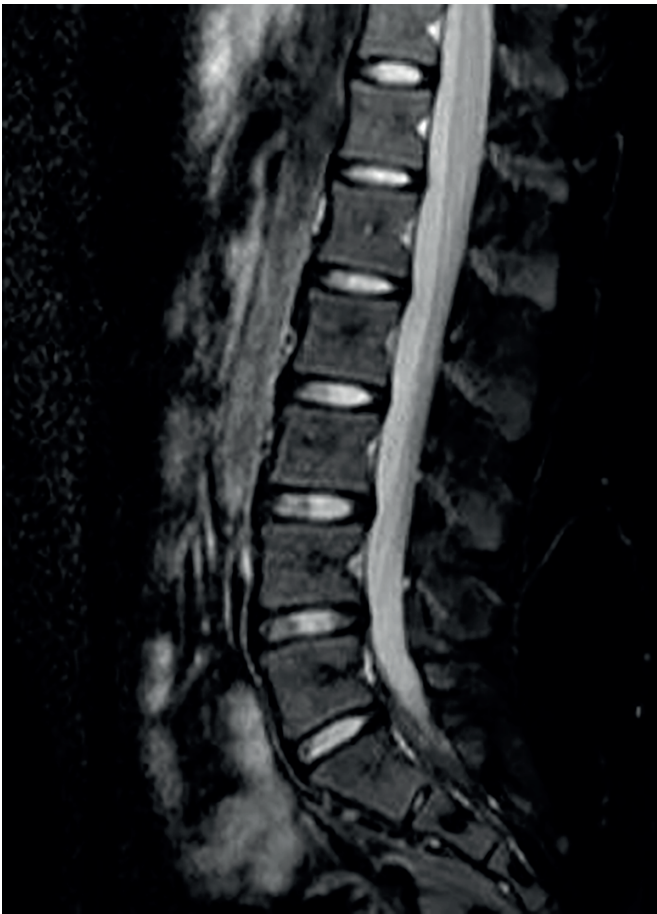

**FIGURE 1:** (A) Lumbosacral spine MRI without contrast. (B) Resonance showing sign alteration in the medullary cone with contrast enhancement, as well as in some roots of the cauda equina.



**FIGURE 2:** (A) Resonance without contrast. (B) MRI in which signal alteration was absent and in which the contrast enhancement was reduced in the medullary cone, with only slight contrast enhancement remaining in the cauda equina.

the host and the intensity and frequency of the schistosomiasis infestation are also implicative. Therefore, an individual not sensitized to the disease can develop an immediate hypersensitivity reaction, which can result in severe cases of necrotizing myelitis. However, individuals who reside in an endemic area with previously stimulated immunity tend to develop late hypersensitivity reactions, with the formation of granulomas<sup>4</sup>. The patient described here resides in Cornélio Procópio, a city located in northern Paraná, Brazil, an endemic area for schistosomiasis.



**FIGURE 3:** Lumbosacral MRI for evolutionary control after treatment, evidencing the complete disappearance of the contrast enhancement in the roots of the cauda equina.

Usually, the disease presents with lower back pain, with varying intensity, and/or lower limb tenderness, with hypoesthesia of the sacral region (S1 to S5), with bladder and rectal sphincter alterations and, sometimes, with paraplegia<sup>1,3</sup>. In this case, the patient presented with lumbar pain and altered sensitivity in the right lower limb but without sphincteric involvement and hypoesthesia of the sacral region.

The most important clinical feature of EMR is the low localization of the lesions. In majority of the cases reported in literature, the medullary level is equal or below T6, particularly at T11-L1<sup>6</sup>. The patient presented lesions at L5-S1, a much lower location than expected.

Ferrari et al<sup>6</sup> proposed a clinical classification of EMR comprising three clinical forms: medullary (M), myeloradicular (MR) and conus-cauda equine syndrome (CCS). The EMR of the patient can be classified as CCS, the less frequent form.

In the CCS form, the signs and symptoms arise slower, muscle weakness is less intense, and the distribution of the sensorimotor alterations and muscle weakness are predominantly asymmetric<sup>6</sup>. Our patient presented severe pain in the lumbar region that radiated to the right lower limb associated with acute paresthesia.

The intestinal stage of the infection precedes the medullary stage; however, the patient had never presented with any classical signs and symptoms of the disease. EMR can manifest without a clinical history or diagnosis of schistosomiasis, even many years after the intestinal manifestations of the parasitic infection have disappeared. The diagnosis is confirmed by the parasite's eggs in the stool, complemented by MRI and changes found in the cerebrospinal fluid.

In the MRI, the main findings are granulomatous masses that are visualized as medullary swelling, root involvement of the medullary cone and the cauda equina with contrast uptake, and diffuse granulomatosis with necrosis, atrophy, transverse myelitis, and asymptomatic egg deposition<sup>6-8</sup>.

Between 1988 and 2002, a CSF study including a total of 377 patients with suspected neuroschistosomiasis and tested positive for *S. mansoni* in the CSF, concluded that the presence of *S. mansoni* antibodies in the CSF associated with cellularity >4 cells/mm<sup>3</sup>, protein >40 mg/dL, and the presence of eosinophils, suggest a high possibility of ERM<sup>9</sup>.

In this case, the diagnosis was assumed after the MRI results. Total abdominal ultrasonography, stool parasitology, and CSF puncture were performed. Of these tests, only the CSF presented as changed, and the diagnosis was confirmed from the positivity of the immunological reaction to *Schistosoma*.

Antibodies against schistosome antigens may be searched in the serum or CSF. A positive reaction in serum is only evidence of previous exposure to schistosome, but the determination of schistosomal antibodies in the CSF has shown higher specificity. This is due to the anatomical and physiological peculiarities of the CNS, which is able to synthesize immunoglobulins locally in response to an injury, and is separated from the rest of the body by the blood-brain barrier<sup>6</sup>, which can explain the patient's positivity in the CSF and not serum.

The differential diagnosis of ERM includes the following: bacterial or viral myelitis, lumbar disc herniation, multiple sclerosis, spinal cord trauma, intrathecal injection, radiation, tumors, vitamin B12 deficiency, antiphospholipid syndrome, diabetic or autoimmune vasculitis, syringomyelia, and neurocysticercosis<sup>3</sup>. The patient was subjected to tests for differential diagnosis with other etiologies that showed negative results for all.

The action of corticosteroid is essential and irreplaceable for improvement of clinical symptoms and prevention of necrotizing vasculitis and irreversible lesions, and it should be implemented as early as possible. In this case, treatment with dexamethasone was initiated to ensure greater protection of the nervous tissue; 2 days after, praziquantel was given in a single dose to achieve destruction of the parasites. After this phase, oral and systemic corticosteroids were given for 5 months until considerable improvement was observed in the laboratory and imaging tests.

Early diagnosis and rapid use of anti-inflammatory therapy are fundamental in determining the disease prognosis and for the prevention of irreversible neurological sequelae. Thus, it is important to consider this pathology as a differential diagnosis relating to spinal expansive lesions, especially in areas endemic for schistosomiasis.

**Conflict of Interests:** The authors declare that they have no conflict of interests.

---

## REFERENCES

1. Matas SLA. Neuroesquistossomose. Rev Neurociências. 2001;9(1):27-31.
2. Carod-Artal FJ. Neurological complications of *Schistosoma* infection. Trans R Soc Trop Med Hyg. 2008;102(2):107-16.
3. Ministério da Saúde (MS). Secretaria de Vigilância em Saúde. Departamento de Vigilância Epidemiológica. Guia de Vigilância Epidemiológica e Controle da Mieloradiculopatia Esquistossomótica. Brasília: MS; 2006. 27p. Acessado em: 21/01/2019. Disponível em: [http://bvsmms.saude.gov.br/bvs/publicacoes/07\\_0061\\_M.pdf](http://bvsmms.saude.gov.br/bvs/publicacoes/07_0061_M.pdf)
4. Lo DS, Rodrigues JC, Grisi SJFE, Bellizia Neto L, Cavinatto JN. Neuroesquistossomose medular. Relato de um caso com sequelas graves. Pediatría. 1997;19 (2):139-42.
5. Freitas ARR, Oliveira ACP, Silva LJ. Schistosomal myeloradiculopathy in low-prevalence area: 27 cases (14 autochthonous) in Campinas, São Paulo, Brazil. Mem Inst Oswaldo Cruz. 2010;105(4):398-408.
6. Ferrari TCA, Moreira PRR, Cunha AS. Clinical characterization of neuroschistosomiasis due to *Schistosoma mansoni* and its treatment. Acta Trop. 2008;108(2-3):89-97.
7. Silva LCS, Maciel PE, Ribas JGR, Pereira SRS, Serufo JC, Andrade LM, et al. Mieloradiculopatia esquistossomótica. Rev Soc Bras Med Trop. 2004;37(3):261-72.
8. Faria AV, Cerqueira EMFP, Reis F, Pirani C, Damasceno BP, Menezes Neto JR, et al. Apresentações da esquistossomose no sistema nervoso central: correlação clínica e radiológica. Radiol Bras. 2002;35(1):47-50.
9. Moreno-Carvalho OA, Nascimento-Carvalho CM, Bacelar ALS, Andrade-Filho AS, Costa G, Fontes JB, et al. Clinical and cerebrospinal fluid (CSF) profile and CSF criteria for the diagnosis of spinal cord schistosomiasis. Arq. Neuro-Psiquiatr. 2003;61(2B):353-8.