

ORIGINAL ARTICLE

PERSISTENT ASTHMA IN ADULTS: COMPARISON OF HIGH RESOLUTION COMPUTED TOMOGRAPHY OF THE LUNGS AFTER ONE YEAR OF FOLLOW-UP

Alberto Cukier, Rafael Stelmach, Jorge Issamu Kavakama, Mário Terra Filho and Francisco Vargas

RHCFAP/3038

CUKIER A et al. - Persistent asthma in adults: comparison of high resolution computed tomography of the lungs after one year of follow-up. *Rev. Hosp. Clín. Fac. Med. S. Paulo* 56(3):63-68, 2001.

Objective: The aims of this study were to evaluate the role of high resolution computed tomography of the thorax in detecting abnormalities in chronic asthmatic patients and to determine the behavior of these lesions after at least one year.

Method: Fourteen persistent asthmatic patients with a mean forced expiratory volume in 1-second that was 63% of predicted and a mean forced expiratory volume in 1-second /forced vital capacity of 60% had two high resolution computed tomographies separated by an interval of at least one year.

Results: All 14 patients had abnormalities on both scans. The most common abnormality was bronchial wall thickening, which was present in all patients on both computed tomographies. Bronchiectasis was suggested on the first computed tomography in 5 of the 14 (36%) patients, but on follow-up, the bronchial dilatation had disappeared in 2 and diminished in a third. Only one patient had any emphysematous changes; a minimal persistent area of paraseptal emphysema was present on both scans. In 3 patients, a "mosaic" appearance was observed on the first scan, and this persisted on the follow-up computed tomography. Two patients had persistent areas of mucoid impaction. In a third patient, mucus plugging was detected only on the second computed tomography.

Conclusions: We conclude that there are many abnormalities on the high resolution computed tomography of patients with persistent asthma. Changes suggestive of bronchiectasis, namely bronchial dilatation, frequently resolve spontaneously. Therefore, the diagnosis of bronchiectasis by high resolution computed tomography in asthmatic patients must be made with caution, since bronchial dilatation can be reversible or can represent false dilatation. Nonsmoking chronic asthmatic subjects in this study had no evidence of centrilobular or panacinar emphysema.

DESCRIPTORS: X-ray tomography, computed. Asthma. Function test, lung. Lung diseases. Obstructive. Bronchial diseases.

High resolution computed tomography (HRCT) has become an invaluable tool in the detailed evaluation of the lung structure *in vivo*.

Recently, several authors have reported the appearances of the lungs on CT in asthmatic patients¹⁻⁶. In addition to the expected abnormalities, such as hyperinflation, mucoid impaction, acinar pattern, lobar collapse and bronchial wall thickening, some unexpected

results emerged from these studies. Particularly surprising were the incidence of bronchiectasis (37 to 65%)^{2,3,5} and emphysema (18%)³ described in the chronic asthmatic patients in these series.

From the Division of Respiratory Diseases of the Heart Institute (InCor), Hospital das Clínicas, Faculty of Medicine, University of Sao Paulo.

Paganin et al. were the only authors who reevaluated the patients after treatment³. Their purpose was to delineate the lesions on HRCT that were most likely to be reversible in acute asthma.

They obtained 2 CT scan examinations with a 2-week interval, and defined as irreversible those lesions that did not disappear in the second CT. Considering these criteria, they concluded that mucoid impaction, acinar

pattern, and lobar collapse are reversible lesions, and bronchiectasis, bronchial wall thickening, and emphysema are irreversible abnormalities³.

More recently, the criteria for diagnosing HRCT disturbances in asthmatic patients, particularly bronchial wall thickening and bronchial dilatation, have been criticized^{2,7}, since images suggestive of these abnormalities have been detected in healthy subjects.

The aims of this study were to further evaluate the role of HRCT in detecting abnormalities in chronic asthmatic patients and to determine the behavior of these lesions after at least one year.

SUBJECTS AND METHODS

Subjects

Fourteen patients with persistent asthma were studied. Three patients had moderate and 11 had severe asthma⁸. Patients were chosen for the study if they had undergone a high-resolution CT scan of the thorax and lung function tests at least 12 months before the reevaluation (mean 512.2 ± 141.3 days), and kept attending the outpatient clinic of our institution regularly. All patients had either reversible airway obstruction, i.e., 15% improvement in forced expiratory volume in 1-second (FEV_1) after bronchodilation or a positive histamine challenge test. None of the subjects had a history of bronchiectasis or allergic bronchopulmonary aspergillosis (as defined by means of positive *Aspergillus* precipitins). The study population had a mean age of 36.5 ± 11.8 years. The mean duration of the asthma was 23.6 ± 14.4 years. None of the patients tested were current or previous smokers. All the subjects were studied during remission on adequate therapy.

All patients underwent physiologic evaluation that included measurement

of the forced expiratory volume in 1-second (FEV_1), forced vital capacity (FVC), single-breath diffusing capacity of the lung for carbon monoxide corrected for lung volumes (DLCO/VA), residual volume (RV), and total lung capacity (TLC). The pulmonary function testing was done on the same day as the CT scanning.

The study was carried out after informed consent of the patients, and approval by the Ethics Committee of our Institution was obtained.

Computed tomography

The CT scans were performed on a Philips - LX (Netherlands) scanner using high resolution technique. All scans were obtained at full inspiration. Thin CT sections of 1.5 mm were obtained through the lungs at 10 mm intervals using a scan time of 1.2 seconds. The high-resolution CT scans were reconstructed by using a high-resolution algorithm and a matrix size of 512x512. The images were obtained and viewed at window levels of 800 HU and window width of 1200 HU.

The 2 scans of each patient were evaluated independently by 3 observers, and final interpretation was obtained by consensus. The scans were evaluated for evidence of emphysema^{9,10}, bronchial wall thickening¹¹, bronchiectasis^{2,11}, mucoid impaction¹¹, and "mosaic" appearance¹².

Three high-resolution CT sections were chosen for detailed analysis. The initial section evaluated was at the level of the hila, at or close to the upper lobe bronchi. Subsequent sections evaluated were 6 cm above and 6 cm below the initial section.

Statistical analysis

The difference in the level of pulmonary function tests between the two moments of the study was assessed using a two-sample *t* test.

RESULTS

The pulmonary function data in the two moments of the study are summarized in table 1. There was no statistically significant difference in the level of pulmonary function between the two moments.

The HRCT findings in the first and second evaluations are shown in table 2. We observed bronchial wall thickening in all patients in both CT. In the first CT, 65 (57.5%) of the 113 bronchi evaluated fulfilled the criteria for bronchial wall thickening, compared with 57 (72.1%) of 79 bronchi in the second CT.

On the first CT, 5 (36%) of the 14 asthmatic subjects had at least one dilated bronchus consistent with bronchiectasis. One patient had cystic bronchiectasis that was not seen on the second CT. A second patient had cylindrical bronchiectasis that persisted. A third patient had on the first CT a dilated bronchus in the middle lobe that failed to taper normally, which was consistent with cylindrical bronchiectasis. In the follow-up CT, this dilated bronchus became normal. In the other 2 patients, the diameters of dilated bronchi were slightly greater than that of the accompanying artery in the first CT. In one of these patients, the bronchial diameter was considered normal in the second CT, and in the other, the dilated bronchi were less prevalent than in the previous CT.

Emphysema was not observed in any of the patients, with the exception of one patient where a minimal persistent area of paraseptal emphysema was detected in the right apex.

In 3 patients, a "mosaic" appearance was observed on the first scan and this persisted on the follow-up CT (Fig. 1). Two patients had persistent areas of mucoid impaction. In a third patient, mucus plugging was detected only on the second CT.

The detailed analysis of the three

sections of the HRCT from each patient revealed that bronchial wall thickening was present in 65/113 bronchi (57.5%) on the first CT and in 57/79 (72.1%) on the second CT.

DISCUSSION

In this study, we found that moderate to severe persistent asthmatic patients have abnormalities in HRCT, such as bronchial wall thickening, bronchial dilatation, mucoid impaction, and a “mosaic” appearance. However,

the bronchial lesions must be cautiously interpreted, since bronchial dilatation frequently was not persistent on the second scan obtained after at least a one-year interval.

Bronchial wall thickening is commonly seen on chest radiographs and CT scans in subjects with airway disease, presumably because of a combination of bronchial and peribronchial inflammation, muscular wall thickening, and peribronchial fibrosis¹³. However, the finding of mild bronchial thickening is subjective, and it may also be found in healthy subjects^{2,14}.

The prevalence of bronchial wall thickening in the asthmatic subjects studied by Paganin et al.³ was 16% at HRCT. In contrast, the prevalence was 92% in the study reported by Lynch et al.². In our study, bronchial wall thickening was detected in all patients on both evaluations. When individual bronchi were examined, there was bronchial thickening in 65/113 bronchi (57.5%) at the first CT and in 57/79 (72.1%) bronchi in the second evaluation. These discrepancies confirm the subjectivity of the finding of bronchial wall thickening and indicate that this finding cannot be considered diagnostic of airway disease or asthma.

The use of CT to diagnose bronchiectasis has been validated by several studies of subjects with suspected bronchiectasis who underwent both CT and bronchography¹⁵⁻¹⁷. The accuracy of these different studies varied depending on the technique and the type of bronchiectasis. The most commonly missed dilatations were those due to mild to moderate cylindrical bronchiectasis. Asthmatic subjects were excluded from most of the studies.

Autopsy studies have shown that 15 to 20% of patients dying with status asthmaticus have bronchiectasis, most commonly in the upper lobe^{18, 19}. Surprisingly, the reported prevalence of bronchiectasis in studies done on asth-

Table 1 - Pulmonary function tests of the asthmatic patients.

	1th CT	2nd CT
FEV ₁ (% of predicted)	63.2 ± 18.5	55.0 ± 15.3
FEV ₁ /FVC (%)	59.7 ± 14.7	51.0 ± 10.3
RV (% of predicted)	143.9 ± 34.5	124.5 ± 50.3
TLC (% of predicted)	93.6 ± 16.3	91.6 ± 14.1
DLCO/VA (% of predicted)	132.2 ± 28.4	113.8 ± 31.5

Data are reported as means ± SD

FEV₁ - forced expiratory volume in the first second; FVC - forced vital capacity; RV-residual volume; TLC - total lung capacity; DLCO/VA - single breath diffusing capacity.

Table 2 - HRCT findings in the 14 asthmatic patients at the first and second evaluation.

	1st CT	2nd CT
Bronchial wall thickening	14 (100%)	14 (100%)
Bronchial dilatation and/or bronchiectasis	5 (36%)	3 (21%)
Mucoid impaction	2 (14%)	3 (21%)
Emphysema (paraseptal)	1 (7%)	1 (7%)
“Mosaic” pattern	3 (21%)	3 (21%)

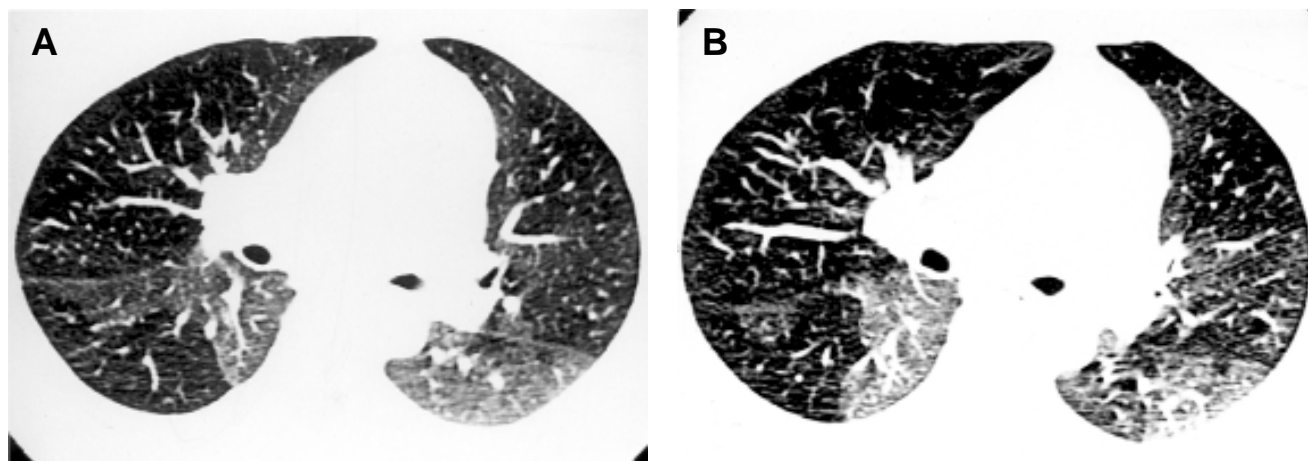


Figure 1 - A - High-resolution CT scan shows “mosaic” appearance with patchy decrease in lung density. B - High-resolution CT scan of the same patient after 443 days, showing persistence of areas with decrease in lung density.

matics using CT is higher than that in the autopsy studies. Neeld et al.⁵ found cylindrical bronchiectasis in 3 of 8 patients (37%) in their series without proven evidence of allergic bronchopulmonary aspergillosis (ABPA). Paganin et al.³ observed bronchiectasis, mostly cylindrical, in 65% of 57 asthmatic patients. Lynch et al.² found that 36% of bronchi in asthmatic subjects without ABPA were larger than the accompanying pulmonary artery, and 77% of asthmatic subjects had one or more such bronchi. However, 19% of bronchi in control subjects also met the criteria for bronchial dilatation, and 59% of control subjects had one or more such bronchi. It is suggested that this prevalence of bronchial dilatation in subjects with asthma is due to bronchial destruction^{3, 18, 19}. Also, it is possible that some asthmatic subjects without serologic evidence of ABPA might have subclinical ABPA, perhaps partially suppressed by steroids⁵.

In the present study, 5 (36%) of our 14 asthmatic subjects had at least one dilated bronchus on the first HRCT. In only 2 of these patients did the abnormal bronchi remain unchanged on the follow-up CT. In the other patients, the images consistent with the diagnosis of bronchial dilatation disappeared or became less prevalent on the second CT.

In general, a bronchus appears dilated if its diameter is greater than that of the associated artery. The explanations proposed to explain why a bronchus may be larger than its adjacent pulmonary artery, without indicating true bronchiectasis include the following: different branch points for the artery and bronchus, and local hypoxia

leading to a decrease in the size of the artery^{20, 21}. These considerations may explain the differences observed between the first and second CT in 2 of our patients. In the remaining patient, the disappearance of the localized dilatation of the middle lobe bronchus might be related to the normalization of a reversible bronchial dilatation in a patient who had a documented pneumonia 8 months before the first CT.

Mucous-filled airways result from inflammation and decreased clearance of secretions. This is an expected abnormality in asthmatic patients, who have thick and tenacious mucus, and it represents a reversible abnormality^{3, 6}. This abnormality was found on both scans in 2 of our patients and only on the second scan in a third patient.

Although one pathologic study suggested that the occurrence of emphysema in asthma was common²², the majority of the authors believe it to be rare^{18, 19, 23}. Several reports have correlated the CT findings with pathologic assessment of emphysema and have concluded that the CT scan is useful in both the quantitative and qualitative assessment of emphysema^{10, 24-26}.

Studies using CT in the evaluation of emphysema in nonsmoking asthmatic subjects have demonstrated emphysema in 0 – 20% of patients^{1, 2, 4, 27}. A higher prevalence of emphysema has been reported in asthmatic patients who smoke^{1, 2}. It has been suggested that emphysema in the nonsmoking asthmatic may not be due to a parenchymal destructive disease per se, but rather to an extensive peribronchial fibrosis that might relate to cicatricial

emphysema³. The results of the present study are in accordance with the results reported by others.

Areas of decreased lung attenuation can sometimes be recognized on HRCT in patients who have diseases that produce air trapping, poor ventilation, or poor perfusion of the lung parenchyma²⁸. This is particularly common in subjects with bronchiolitis obliterans²⁹, leading to marked heterogeneity of lung density, with lobules of increased and decreased lung density that create a striking “mosaic” appearance¹². The areas of decreased lung density are presumed to be due to air trapping, with associated reflex pulmonary oligemia. The areas of increased lung density are more difficult to explain. They may be due to redistribution of blood flow to more normal lung, with relative over-perfusion of the more normal areas^{11, 30}. We observed a “mosaic” appearance in 3 of our patients. In all of them, this finding was unchanged in the follow-up CT, suggesting it to be an irreversible abnormality.

We conclude that chronic asthmatic patients have many abnormalities detected by HRCT. This study has demonstrated that those abnormalities that are thought to be suggestive of bronchiectasis are sometimes reversible. Therefore, the diagnosis of bronchiectasis by HRCT in asthmatic patients must be made with caution, since the bronchial dilatation can be reversible. Nonsmoking chronic asthmatic subjects in this study had no evidence of centrilobular or panacinar emphysema.

RESUMO

RHCFA/3038

CUKIER A e col. – Asma persistente em adultos: comparação da tomografia computadorizada de tórax de alta resolução após um ano de seguimento. **Rev. Hosp. Clín. Fac. Med. S. Paulo** 56(3):63-68, 2001.

Objetivo: Avaliar o papel da tomografia computadorizada de tórax de alta resolução em detectar alterações estruturais pulmonares em pacientes asmáticos persistentes e determinar o comportamento destas lesões após pelo menos um ano de seguimento.

Método: Foram avaliados 14 pacientes asmáticos persistentes em que eram disponíveis duas tomografias computadorizadas de tórax de alta resolução realizadas com um intervalo de pelo menos um ano. O valor médio do volume expiratório forçado no primeiro segundo foi de 63% do predito e o

da relação volume expiratório forçado no primeiro segundo/capacidade vital forçada foi de 60%.

Resultados: Alterações estruturais foram detectadas em todos os pacientes em ambas tomografias. A anormalidade mais comumente observada foi espessamento brônquico, presente em todos os pacientes nos dois exames. Bronquectasias foram sugeridas na primeira tomografia em cinco dos 14 (36%) pacientes, mas no segundo exame a dilatação brônquica tinha desaparecido em dois e reduzido em um. Enfisema paraseptal foi detectado em um paciente. Em três, havia padrão “em mosaico” no primeiro exame, que persistiu no segundo exame. Em dois pacientes foram detectadas áreas persistentes de impactação mucóide. Em um terceiro, a impactação foi observada somente na segunda tomografia.

Conclusões: Pacientes com asma persistente apresentam múltiplas anormalidades na tomografia computadorizada de tórax de alta resolução. Imagens sugestivas de bronquectasias freqüentemente têm resolução espontânea. Desta forma, é necessária precaução ao fazer o diagnóstico de bronquectasias através de tomografia computadorizada de tórax de alta resolução em pacientes asmáticos, uma vez que a dilatação brônquica pode ser reversível ou representar uma falsa dilatação. Enfisema centrilobular ou panacinar não foi detectado em nenhum paciente deste estudo.

DESCRITORES: Raio-X, tomografia computadorizada. Asma. Testes funcionais, pulmão. Doenças pulmonares, obstrutivas. Bronquectasias.

REFERENCES

1. KONDOH Y, HIROYUKI T, YOKOYAMA S et al. - Emphysematous change in chronic asthma in relation to cigarette smoking. Assessment by computed tomography. **Chest** 1990; **97**: 845-49.
2. LYNCH DA, NEWELL JD, TSCHOMPER BA et al. - Uncomplicated asthma in adults: comparison of CT appearance of the lungs in asthmatic and healthy subjects. **Radiology** 1993; **188**: 829-833.
3. PAGANIN F, TRUSSARD V, SENETERRE E et al. - Chest radiography and high resolution computed tomography of the lungs in asthma. **Am Rev Resp Dis** 1992; **146**:1084-1087.
4. KINSELLA M, MÜLLER NL, STAPLES C et al. - Hyperinflation in asthma and emphysema. Assessment by pulmonary function testing and computed tomography. **Chest** 1998; **94**: 286-289.
5. NEELD DA, GOODMAN LR, GURNEY JW et al. - (1990). Computerized tomography in the evaluation of allergic bronchopulmonary aspergillosis. **Am Rev Resp Dis** 1990; **142**: 1200-1205.
6. GRENIER P, MOUREY-GEROSA I, BENALI K et al. - Abnormalities of the airways and lung parenchyma in asthmatics: CT observations in 50 patients and inter- and intraobserver variability. **Eur Radiol** 1996; **6**: 199-206.
7. KING GG, MÜLLER NL & PARÉ PD - Evaluation of airways in obstructive pulmonary disease using high-resolution computed tomography. **Am J Resp Crit Care Med** 1999; **159**: 992-1004.
8. GLOBAL Strategy for Asthma Management and Prevention - (1995). NHLBI/WHO Workshop. National Institutes of Health, National Heart, Lung, and Blood Institute, Publication Number 95-3659.
9. MILLER RR, MÜLLER NL, VEDAL S et al. - Limitations of computed tomography in the assessment of emphysema. **Am Rev Resp Dis** 1989; **139**: 980-983.
10. STERN EJ & FRANK MS - CT of the lung in patients with pulmonary emphysema: diagnosis, quantification, and correlation with pathologic and physiologic findings. **Am J Roentgenol** 1994; **162**: 791-798.
11. WEBB RW, MÜLLER NL & NAIDICH DP - **High-resolution CT of the lung**. New York, Raven Press, 1992.
12. MARTIN KW, SAGEL SS & SIEGEL BA - Mosaic oligemia simulating pulmonary infiltrates on CT. **Am J Roentgenol** 1986; **147**: 670-673.

13. CARROLL, ELLIOT J, MORTON A et al. - The structure of large and small airways in nonfatal and fatal asthma. **Am Rev Resp Dis** 1992;**147**: 405-410.
14. REMY-JARDIN M, REMY J, BOULENGUEZ C et al. - Morphologic effects of cigarette smoking on airways and pulmonary parenchyma in healthy adult volunteers: CT evaluation and correlation with pulmonary function tests. **Radiology** 1993;**186**: 107-115.
15. JOHARJY IA, BASHI AS & ADBULLAH AK - Value of medium-thickness CT in the diagnosis of bronchiectasis. **Am J Roentgenol** 1987;**149**: 1133-1137.
16. GRENIER P, MAURICE F, MUSSET D et al. - Bronchiectasis: assessment by thin-section CT. **Radiology** 1986;**161**: 95-99.
17. SILVERMAN PM & GODWIN JD et al. - CT/bronchographic correlations in bronchiectasis. **J Computer Assist Tomogr** 1987;**11**:52-56.
18. THURLBECK WM - **Chronic airflow obstruction in lung disease.** Philadelphia, Saunders, 1976.
19. DUNNILL MS - The pathology of asthma, with special reference to changes in the bronchial mucosa. **J Clin Pathology** 1960;**13**:27-33.
20. HEROLD CJ, WETZEL RC, ROBOTHAM JL et al. - Acute effects of increased intravascular volume and hypoxia on the pulmonary circulation: assessment with high-resolution CT. **Radiology** 1992;**183**:655-662.
21. WETZEL R, HEROLD C, ZERHOUNI E et al. - Hypoxic bronchodilation. **J Appl Physiol** 1992;**73**:1202-1206.
22. MESSER JW, PETERS GA & BENNETT WA - Causes of death and pathological findings in 304 cases of bronchial asthma. **Diseases of the Chest** 1960;**38**:616-624.
23. WILLIAMS MH JR & LEVIN M - Sudden death from bronchial asthma. **Am Rev Resp Dis** 1966;**94**: 608-611.
24. BERGIN CJ, MÜLLER NL & MILLER RR - CT in the qualitative assessment of emphysema. **J Thorac Imaging** 1986;**1**:94-103.
25. FOSTER WL JR, PRATT PC, ROGGLI VL et al. - Centrilobular emphysema: CT-pathologic correlation. **Radiology** 1986;**156**:27-32.
26. WEBB WR, STEIN MG, FINKBEINER WE et al. - Normal and diseased isolated lungs: high-resolution CT. **Radiology** 1988;**166**:81-87.
27. AUERBACH O, HAMMOND EC, GARFINKEL L et al. - Relationship of smoking and age to emphysema: whole-lung section study. **N Engl J Med** 1972;**286**:853-857.
28. LYNCH DA, BRASCH RC, HARDY KA et al. - Pediatric pulmonary disease: assessment with high-resolution ultrafast CT. **Radiology** 1990;**176**:243-248.
29. SWEATMAN MC, MILLAR AB, STRICKLAND B et al. - Computed tomography in adult obliterative bronchiolitis. **Clin Radiol** 1990;**41**:116-119.
30. LYNCH DA - Imaging of small airways diseases. In: KING TE Jr. **Bronchiolitis.** Philadelphia, Saunders. 1993.

Received for publication on February 16, 2001.