

CASE REPORT

THE USE OF STENTS IN THE TREATMENT OF TRAUMATIC INTIMAL FLAPS: CASE REPORT

Nelson Wolosker, Kenji Nishinari, Livio Nakano, Alexandre Maieira Anacleto, and Pedro Puech-Leão

RHCFAP/3047

WOLOSKER N et al. - The use of stents in the treatment of traumatic intimal flaps: case report. *Rev. Hosp. Clín. Fac. Med. S. Paulo* 56(4):119-122, 2001.

Treatment of arterial traumatic intimal lesions is controversial due to its unknown natural history. Current therapeutical options include arterial reconstruction and clinical observation. The idea of using stents to correct intimal flaps is based on their use to correct dissections, flaps, and arterial irregularities after angioplasty.

We report the successful treatment of a traumatic intimal flap of the superficial femoral artery, caused by gunshot trauma, with a Palmaz stent in the acute period. One year after the operation, a duplex scan revealed normal flow in the artery and complete exclusion of the intimal flap; distal pulses were palpable, and the patient was completely asymptomatic.

DESCRIPTORS: Stents. Femoral artery injuries. Vascular trauma. Minimally invasive techniques. Palmaz stent.

The routine use of duplex scans in arterial trauma has improved the diagnosis of asymptomatic arterial lesions. Intimal flap is one of the most frequent types of occult arterial trauma. Treatment of traumatic intimal lesions is controversial due to its unknown natural history. Current therapeutical options include arterial reconstruction and clinical observation¹.

The development of angioplasty catheters and stents has opened a new venue for the treatment of intimal flaps². We report here the successful treatment with a Palmaz stent in the acute period of a traumatic intimal flap of the superficial femoral artery caused by gunshot trauma.

CASE REPORT

A 26-year-old male patient was admitted in the emergency room with a

4-hour history of gunshot wound to the left lower extremity. Clinical examination showed a small hematoma in the thigh and a bullet track close to the superficial femoral artery. All pulses were normal.

Duplex scan revealed an 8 mm intimal flap of the arterial wall without blood leakage, and the patient was brought to the vascular operating room. Anterograde puncture of the common femoral artery was performed. After injection of contrast media, the intimal flap was precisely confirmed and localized. No contrast extravasation was observed (Fig. 1).

A hydrophilic guide wire was introduced under fluoroscopy passing the intimal flap. A Palmaz stent P 294,

mounted in a 6/30-mm angioplasty balloon, was placed in the desired position. The balloon was inflated and the stent expanded, correcting the intimal flap (Fig. 2).

One year after the operation a duplex scan revealed normal flow in the artery and complete exclusion of the intimal flap, distal pulses were palpable, and the patient was completely asymptomatic.

DISCUSSION

Little is known about the natural history of intimal flaps due to ethical constraints of doing controlled studies in humans. Consequently, several animal studies have been carried out in order to evaluate the natural history of this disease³.

There is a consensus in the literature that large arterial flaps have to be

From the Division of Vascular Surgery, Hospital das Clínicas, Faculty of Medicine, University of São Paulo.

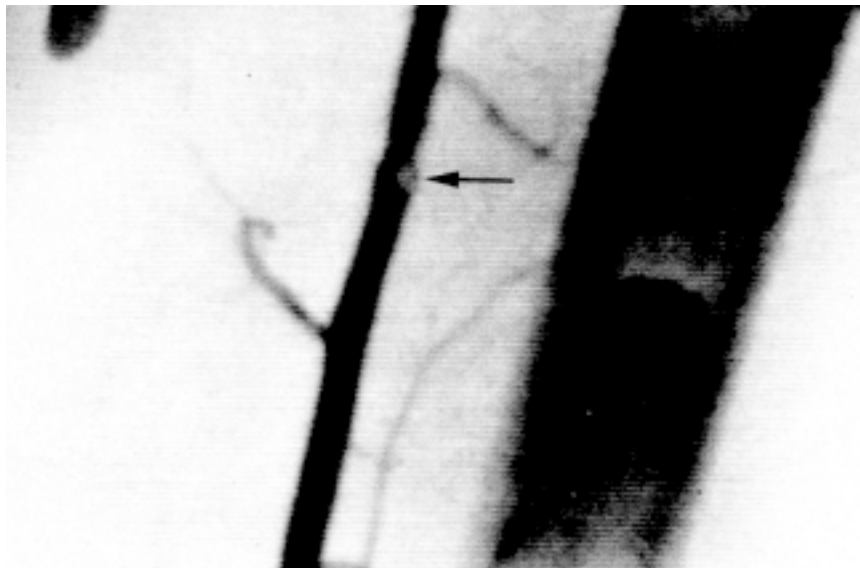


Figure 1 - Pre operative arteriography showing intimal flap.

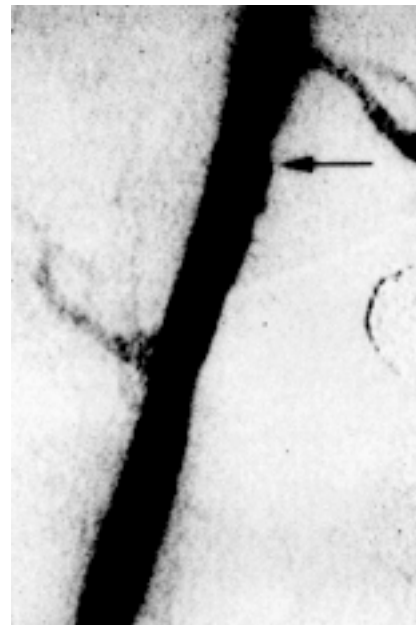

Figure 2 - Arteriography after stenting the intimal flap.

treated surgically because they are considered to predispose thrombosis or rupture^{4,5}. For this reason, we opted to correct this intimal flap.

The idea to use a stent to correct the intimal flap was based on the use of stents for correcting dissections, flaps, and arterial irregularities after angioplasty². The role of stents as internal arterial skeletons that fix arterial irregularities was suggestive of using them to fix intimal flaps against the arterial wall, solving the problem.

We tested this hypothesis in an experimental model in dogs, where the use of stents proved to be better than the natural course with intimal flaps, preventing arterial thrombosis⁶.

The potential advantages of the use of stents instead of invasive surgical intervention are the same as for

endovascular procedures instead of conventional surgery in the treatment of obstructive peripheral disease. In precise indications, the results of endovascular procedures are similar to those of open surgery, and they are percutaneous procedures with lower morbidity, cost, and time of hospital stay⁷.

Patients with intimal flaps are, in most cases, trauma victims; therefore, they are generally young people with previously normal arteries. Surgical procedures in these cases produce excellent results. However, in any type of invasive surgical procedure, a surgical incision is required, it is eventually necessary to use an arterial substitute or patch, and a long recovery time is usually required⁸.

We present a new therapeutic option, in this case, with an excellent re-

sult of arterial permeability after 1 year. The prompt treatment avoided acute arterial occlusions, which may be the natural course of these lesions, especially when large flaps are produced^{9,10}.

Henceforth, patients with intimal flaps might be brought to the vascular operating room that is equipped with digital fluoroscopy and a radiotransparent table, or to an interventional radiology room (with a stand-by operating room available). Under local anesthesia or radicular block, the patient would undergo angiography. Once the intimal flap is found, a stent could be introduced using the same access, and it could be placed where it would be expanded with the help of fluoroscopy, correcting the lesion.

RESUMO

RHCFAF/3047

WOLOSKER N. e col. – Uso de "stents" no tratamento de lesões arteriais íntimas de origem traumática: relato de caso. **Rev. Hosp. Clín. Fac. Med. S. Paulo** 56(4):119-122, 2001.

O tratamento de lesões arteriais íntimas de origem traumática é controversa pela sua evolução natural ser desconhecida. As opções terapêuticas atuais incluem reconstrução arterial e ob-

servação clínica. A idéia da utilização de "stents" para a correção de descolamentos íntimos é baseada no seu uso em dissecações, "flaps" e irregularidades da artéria após angioplastia com balão.

Descrevemos o tratamento bem sucedido de um descolamento de íntima da artéria femoral superficial causado por ferimento de arma de fogo com a utilização de um "stent" de Palmaz na fase aguda. Um ano após a implanta-

ção do "stent", o duplex scan mostrou fluxo normal pela artéria com a exclusão completa do descolamento de íntima, com pulsos distais palpáveis e com o paciente completamente assintomático.

DESCRITORES: "Stents". Trauma de artéria femoral. Trauma vascular. Técnicas minimamente invasivas. "Stent" de Palmaz.

REFERENCES

- PANETTA TF, SALES CM, MARIN ML et al. - Natural history duplex characteristics and histopathologic correlation of arterial injuries in a canine model. **J Vasc Surg** 1992;16:867-875.
- CRIADO FJ, QUERAL LA & PATTEN P - Endovascular surgery in daily practice: a re-appraisal. **J Endovasc Surg** 1994;1:92-99.
- NEVILLE RF, HOBSON RW, WATANABE B et al. - A prospective evaluation of arterial intimal injuries in an experimental model. **J Trauma** 1991;31:669-675.
- SAWCHUK AP, ELRUP-JORGENSEN J, TOBER MCCOY D et al. - The natural history of intimal flaps in a canine model. **Arch Surg** 1990;125:1614-1616.
- TUFARO A, ARNOLD T, RUMMEL M et al. - Adverse outcome of nonoperative management of intimal injuries caused by penetrating trauma. **J Vasc Surg** 1994;(4):656-659.
- WOLOSKER N, ROSOKY RMA, ANACLETO AM et al. - The use of stents in the treatment of intimal flaps: an experimental study. **Vasc Surg** 1999. (In press).
- FREIMAN DB, FREIMAN MP, SPENCE RK et al. - Economic impact of transluminal angioplasty. **Angiology** 1985;36:772-777.
- DILLARD BM, NELSON DL & NORMAN HG Jr - Review of 85 major traumatic arterial injuries. **Surgery** 1968;63:391-395.

9. FRYKBERG ER, VINES FS & ALEXANDER RH - The natural history of clinically occult arterial injuries: a prospective evaluation. **J Trauma** 1989;**29**:577-583.
10. ROSE SC & MOORE EE - Angiography in patients with arterial trauma: Correlation between angiographic abnormalities operative findings and clinical outcome. **Am J Roentgenol** 1987;**149**:613-619.

Received for publication on March 01, 2001.