

CASE REPORT

PULMONARY HEMORRHAGE AS A MANIFESTATION OF SYSTEMIC LUPUS ERYTHEMATOSUS

Bruno Hollanda Santos, Rodrigo Ribeiro Santos, Celeide Fátima Santos, Adriana Maria Kakehasi and Hermann Alexandre Vivacqua Von Tiesenhausen

SANTOS BH et al. - Pulmonary hemorrhage as a manifestation of systemic lupus erythematosus. *Rev. Hosp. Clín. Fac. Med. S. Paulo* 59(1):47-50, 2004.

The authors report a case of a 19-year-old woman admitted for the investigation of fever and hemolytic anemia for the previous 2 months. As an inpatient, she had convulsions and sudden loss of consciousness, developing hemoptysis, hypoxia, and respiratory insufficiency. Examination showed pericardial effusions on the echocardiogram and bilateral alveolar condensations on the thoracic radiograph. A hypothetical diagnosis of systemic lupus erythematosus was made, and measurement of the antinuclear factor was requested along with daily pulse therapy methylprednisolone, in spite of which the outcome was fatal. Afterwards, the result of the antinuclear factor test was positive, with a titer of 1:5120, showing a fine punctiform pattern, fulfilling the criteria for systemic lupus erythematosus according to the American College of Rheumatology. Secondary pulmonary hemorrhage in this connective tissue disease is an uncommon but serious complication that involves a high level of mortality in spite of intensive treatment, as is also reported in the literature.

DESCRIPTORS: **Alveolar hemorrhage. Systemic lupus erythematosus. Pulmonary capillaritis.**

A variety of noninfectious pulmonary manifestations are frequently associated with systemic lupus erythematosus (SLE), including pleurisy and pleural effusion, which occur in up to 60% of these patients¹ and normally result in low morbidity and mortality. Other pulmonary alterations associated with SLE include acute alveolitis, pneumonitis, pulmonary hypertension, pulmonary embolism, bronchiolitis, and diffuse alveolar hemorrhage (DAH). The first report of DAH associated with SLE was made by Osler in 1904, who reported the case of a young patient who presented with a cutaneous rash, glomerulonephritis, anemia, and pulmonary involvement with hemoptysis and bilateral alveolar infiltration². This is a rare clinical picture, with 73 cases reported in the sci-

entific literature, that presents a poor prognosis, with a mortality of up to 45% of cases, irrespective of the early initiation of immunosuppressant therapy. The authors describe a case of DAH in a patient with a diagnosis of SLE.

CASE REPORT

A black 19-year-old female patient was admitted to investigate continuous fever associated with anemia of 2 months duration. She reported muscle pain and lethargy and presented with

intensely pale mucosa. As an inpatient, she had generalized recurrent convulsions, continuous generalized headache with progressive intensity, and uncontrollable vomiting. After 24 hours, there was drowsiness, mental confusion, torpor, and coma, and the patient was transferred to intensive care. Computerized tomography was undertaken of the skull, which showed diffuse cerebral edema, blurring of the cerebral sulci, and partial collapse of the ventricles (Fig. 1). A cardiogram showed pericardial effusions. A hemogram revealed normocytic and normochromic anemia (Hb 7.8 mg/dL, ht 23.2 mg%), a low platelet count (130,000 c/mm³), and an elevated reticulocyte count (105,000 c/mm³), and the indirect Coombs test was positive. Renal function and urine sedimenta-

From the Medical Clinic Ward, Santa Casa of Belo Horizonte - Belo Horizonte/MG, Brazil.

Received for publication on
August 28, 2003.

tion were normal. A blood sample was taken to determine whether antinuclear factor was present, and pulse therapy with methylprednisolone (1 g/day for 3 days) was initiated, considering the diagnosis to be SLE. On the second day of treatment, there was dyspnea, cough, and voluminous hemoptysis with hemodynamic repercussions. A radiograph of the thorax was undertaken that showed bilateral alveolar

condensations (Fig. 2). The patient developed acute respiratory insufficiency requiring endotracheal intubation when a large quantity of blood was found inundating the airways. In spite of these therapeutic measures, the patient died the same day. Later, the result of the antinuclear factor test was shown to be positive at a dilution of 1:5120, with a fine punctiform pattern, fulfilling the criteria by the American

College of Rheumatology to be classified as SLE³.

DISCUSSION

Although DAH is rare, it is a recognized complication of pulmonary involvement in SLE. In 1904, Osler described the clinical findings of a female patient, aged 24, who presented with a cutaneous rash, anemia, nephritis, hemoptysis, and bilateral alveolar consolidations². This was the first description associating pulmonary hemorrhage with SLE. Since then, 72 cases have been well documented in the literature. The incidence of this complication is low, affecting less than 2% of patients with SLE⁴. Pulmonary hemorrhage is associated with a high mortality that can vary between 45% and 60%⁵. The involvement of other organs and systems, particularly the kidneys, adversely affects the prognosis⁶. Young female patients with an average age of 29 are most commonly affected, at a ratio of 4:1⁴.

In the majority of cases, the diagnosis of SLE is already established an average of 36 months before the occurrence of pulmonary bleeding. However, in 20% of cases where this is the first manifestation of the disease, diagnosis is more complicated⁶. Recurrence of bleeding can occur in patients who survive their first episode of DAH⁷.

Clinical presentation includes dyspnea, hypoxemia, and severe mucocutaneous paleness, with or without signs of external bleeding. Sudden onset of rhonchi and crackles on auscultation are frequent findings. Hemoptysis is a common manifestation but can be absent even in cases of massive hemorrhage⁸.

A radiograph of the thorax showed bilateral alveolar infiltration of rapid development, and tomography of the thorax showed lesions with greater definition that revealed the most ap-

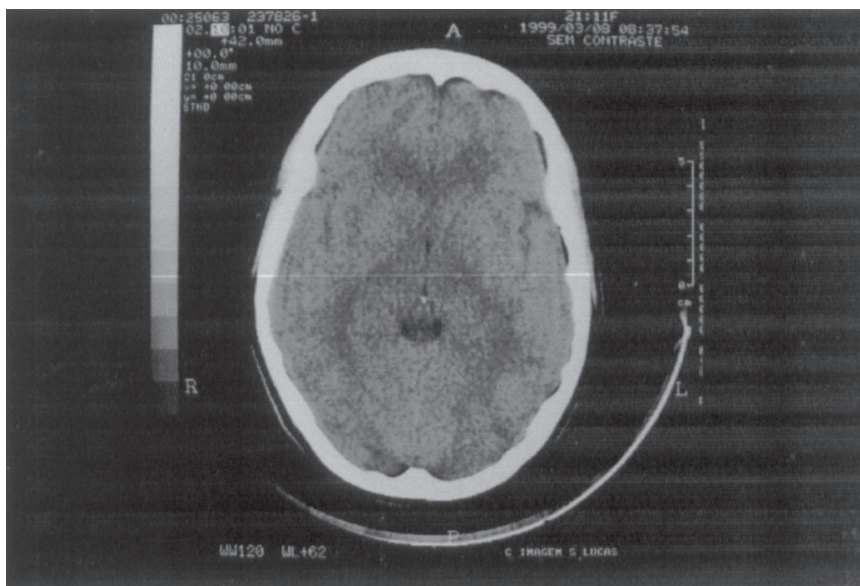


Figure 1 - Computerized tomograph of the brain showing diffuse cerebral edema, partial collapse of the ventricles, and blurring of the cerebral sulci.

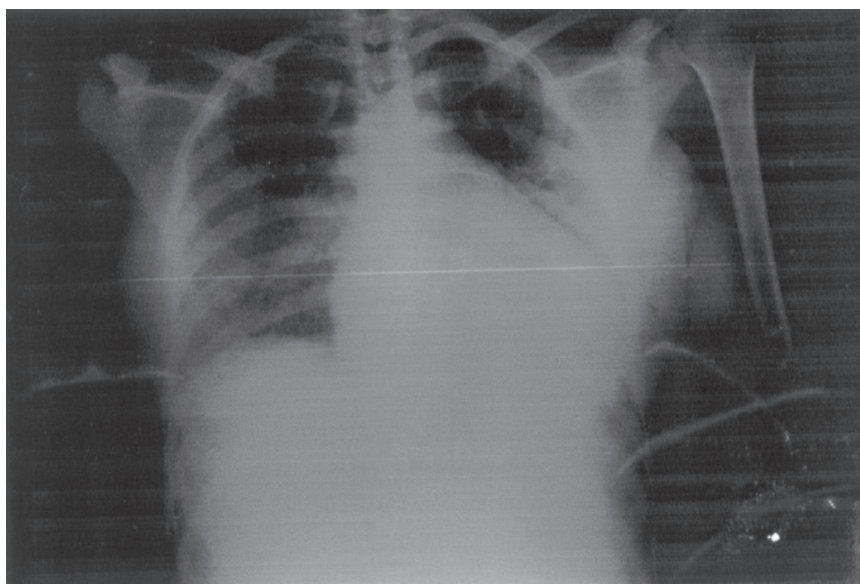


Figure 2 - Thoracic radiograph showing diffuse alveolar condensations and increase of cardiac area.

appropriate location for pulmonary biopsy⁹. Some studies show that magnetic resonance can be more sensitive and specific for DAH than other diagnostic methods, making pulmonary biopsy unnecessary to confirm the diagnosis.

The pulmonary biopsy showed extensive intra-alveolar hemorrhage, which is the most common finding, with red blood cells and cellular debris filling the alveoli as a result of recent bleeding⁴. In addition, the finding of macrophages containing hemosiderin suggests previous bleeding. The presence of necrotizing capillaritis or necrotizing microangiitis according to Liebow, is characterized by foci of infiltration by pyknotic neutrophils in small arterioles, and necrotic capillaries are marked in DAH induced by SLE¹¹. Although nonspecific, this

anatomical-pathological alteration associated with the clinical presentation and the laboratory findings is of great value establishing the etiology of bleeding^{7,11}.

The pathogenesis is not fully understood. The majority of studies relate DAH to the deposit of immunocomplexes in the lungs⁷. Direct immunofluorescence shows deposits of IgG and C3 in the basal membrane of the pulmonary capillaries. However, the absence of these findings in some studies raises the possibility of other mechanisms¹².

Early treatment with corticosteroids is the most common form of treatment. The variations in dosage, duration of treatment, the route of administration, and treatment monitoring restrict conclusions about efficiency. Cyclophosphamide has been used, in

some cases associated with steroids, with contrasting results, and until now with no proven scientific value^{4,5}. Plasmapheresis has been used in a small number of cases but has not been shown to improve the prognosis of these patients¹³. The prognosis is associated with mortality in about 50% of the cases.

CONCLUSION

Diffuse alveolar hemorrhage (DAH) is a rare complication of SLE; it may be the first manifestation of disease and has a devastating evolution irrespective of the therapy initiated. Great attention must be paid to possible diagnosis of DAH, since any delay in therapy can directly influence the evolution of the disease.

RESUMO

SANTOS BH e col. - Hemorragia pulmonar como manifestação do lúpus eritematoso sistêmico. **Rev. Hosp. Clín. Fac. Med. S. Paulo** 59(1):47-50, 2004.

Os autores relatam o caso de uma paciente de 19 anos admitida para investigação de febre e anemia hemolítica, com dois meses de evolução. Durante a internação apresentou crises convulsivas tônico-clônicas e queda súbita no nível de consciência, evoluindo com hemoptise, hipoxemia e in-

suficiência respiratória. Os exames evidenciaram derrame pericárdico ao ecocardiograma e condensações alveolares bilaterais à radiografia de tórax. Foi levantada a hipótese diagnóstica de lúpus eritematoso sistêmico sendo solicitada a pesquisa do fator antinuclear e iniciada terapia com pulsos diários de metilprednisolona, a despeito da qual a paciente evoluiu para o óbito. Posteriormente o resultado do fator antinuclear mostrou-se positivo, em título de 1:5120, padrão puntiforme fino, preenchendo critéri-

os para lúpus eritematoso sistêmico segundo o Colégio Americano de Reumatologia. A hemorragia pulmonar secundária a esta doença do tecido conjuntivo é uma forma incomum e grave de manifestação da doença que evolui com alta mortalidade, apesar do tratamento intensivo, conforme descrito na literatura.

DESCRITORES: Hemorragia alveolar. Lúpus eritematoso sistêmico. Capilarite pulmonar.

REFERENCES

1. Orens JB, Martinez FJ, Lynch III JP. Pleuropulmonary manifestations of systemic lupus erythematosus. *Rheum Dis Clin North Am.* 1994;20:159-93.
2. Osler W. On the visceral manifestations of the erythema group of skin disease. *Am J Med Sci* 1904; 127:1-23.
3. Tan EM, Cohen AS, Fries JF. The 1982 revised criteria for the classification of systemic lupus erythematosus. *Arthritis Rheum* 1982; 25:1271-1277.
4. Zamora MR, Warner ML, Tuder R et al. Diffuse alveolar hemorrhage and systemic lupus erythematosus. *Medicine* 1997; 76:192-202.

5. Schwab EJ, Schumacker HR, Freundlich B *et al.* Pulmonary alveolar hemorrhage in systemic lupus erythematosus. *Semin Arthritis Rheum* 1993; 23:8-15.
6. Eagen JW, Memoli VA, Roberts JL *et al.* Pulmonary hemorrhage in systemic lupus erythematosus. *Medicine* 1978; 57:545-560.
7. Churg A, Franklin W, Chan KL *et al.* Pulmonary hemorrhage and immune-complex deposition in the lung. *Arch Pathol Lab Med* 1980; 104:388-391.
8. Abud-Mendoza C, Diaz-Jouanen E, Alarcon-Segovia D. Fatal pulmonary hemorrhage in systemic lupus erythematosus. Occurrence without hemoptysis. *J Rheumatol* 1985; 12:558-561.
9. Makino Y, Ogawa M, Ueda S *et al.* CT appearance of diffuse alveolar hemorrhage in a patient with systemic lupus erythematosus. *Acta Radiologica* 1993; 6:634-635.
10. Hsu BY, Edwards III DK, Trambert MA. Pulmonary hemorrhage complicating systemic lupus erythematosus: Role of MR imaging in diagnosis. *AJR* 1992; 158:519-520.
11. Myers JL, Katzenstein ALA. Microangiitis in lupus induced pulmonary hemorrhage. *Am J Clin Pathol* 1986; 85:552-556.
12. Desnoyers MR, Bernstein S, Cooper AG *et al.* Pulmonary hemorrhage in lupus erythematosus without evidence of an immunologic cause. *Arch Inter Med* 1984; 144:1398-1400.
13. Lewis EJ, Hunsiker LG, Lan SP *et al.* A controlled trial of plasmapheresis therapy in severe lupus nephritis. *N Engl J Med* 1992; 326:1373-1379.