

# Heart Transplant in a Patient with Complete Absence of the Pericardium

Francisco Gregori Jr, Celso Otaviano Cordeiro, Ulisses Alexandre Croti,  
Thelma Eliza Ferreira Gregori, Osney Moure

Londrina, PR - Brazil

*We report the case of a heart transplant in which the recipient patient had a total congenital absence of the pericardium. Associated with this, we found a major disproportion between the size of the recipient's mediastinal cavity and the size of the donor's heart. To prevent twisting of the great arteries, we placed the graft on the left diaphragm muscle and beneath the left lung, which resulted in an uneventful early and late postoperative course.*

## Case Report

In November of 1995 a 42-year-old male patient, with a body weight of 75kg, underwent heart transplantation. During surgery, we discovered the heart to be a very enlarged heart with significant hypocontractility. We also observed total absence of the pericardium.

The donor patient, kept in the adjoining room, was a young man, at the limit of the receptor's weight compatibility (65kg), with a small heart. We withdrew the cardiac graft with the entire ascending aorta including the aortic arch, reaching the left subclavian artery. In addition, we resected the pulmonary artery at the level of its two branches next to the lungs. As a result, we obtained a graft with long conduits, which we set on the left diaphragm muscle, in the proximity of the chest wall beneath the left lung, to prevent twisting of the great arteries because the absent pericardium would not keep the graft stable. To enable such a lateral positioning of the graft, we left the left and right atria of the donor in their entirety, furthermore, requiring enlargement of the right atria anastomoses by means of a bovine pericardium patch treated with glutaraldehyde. Surgery proceeded normally and the patient was forwarded to

postoperative care in excellent hemodynamic condition. For twenty days, we maintained the patient in a slight left lateral decubitus position until all adhesences were established, thus keeping the graft stable without an eventual twisting of the great arteries. The patient underwent cardiac catheterization, which exhibited normal hemodynamic parameters.

Four years after the surgery, the patient was asymptomatic, obese, and with a mild hypertension, leading a normal life. The thoracic X-ray showed a normal heart positioned to the left over an upper raised diaphragm muscle. A right deviation of the trachea and enlarged left hemi-thorax intercostal spaces existed. Left cineventriculogram in the anteroposterior position showed a heart with normal contractility positioned laterally near to the left chest wall over a paralyzed diaphragm muscle and beneath the lung (fig. 1).

## Discussion

Congenital total absence of the pericardium is an uncommon defect. In general it goes unrecognized and, frequently patients are asymptomatic. This anomaly was first discovered in a live human being by Ladd<sup>1</sup> in 1936 during surgical treatment of a diaphragm hernia. It is seldom diagnosed preoperatively<sup>2</sup>. VanSon et al<sup>3</sup> presented the Mayo Clinic experience on congenital absence of the pericardium (15 cases in 34,000 surgeries). In all, the diagnosis was made in the operating room. Hammoudeh et al<sup>4</sup> reported total absence of the pericardium in a 72-year-old patient who underwent myocardial revascularization and a concomitant aortic valve replacement.

In cases with partial absence of the pericardium, surgical treatment is simple and consists of closure of the orifice with patches of prosthetic material (Dacron, PTFE) or glutaraldehyde-treated bovine pericardium. In total absence of the pericardium, repair becomes extremely difficult, if not impossible.

---

Universidade Estadual de Londrina  
Mailing address: Francisco Gregori Jr - Rua Paes Leme, 1264 - S/701 - 86010-520  
Londrina, PR

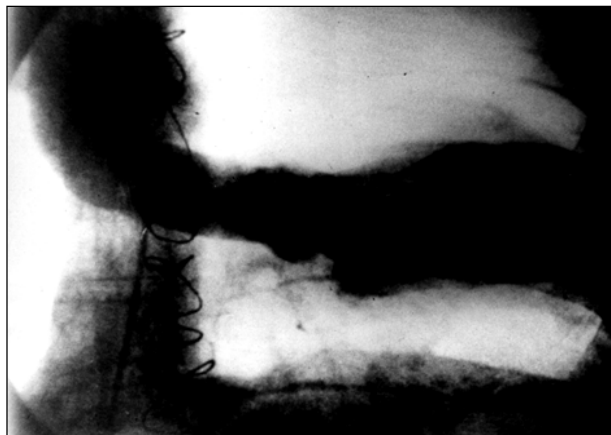


Fig. 1 - Postoperative left cineventriculogram in anteroposterior position. The donor heart is on the left above the diaphragm muscle and beneath the left lung.

No reports exist in the literature about heart transplants in recipients receptors with total absence of the pericardium.

We chose to place the graft in such a lateral position because of the impossibility of attaching the patches of bovine pericardium treated with glutaraldehyde as a replacement for the original pericardium. Attachment would be easy at the diaphragm, pleural and chest wall level, however, extremely difficult and not efficient in the posterior part of the mediastinal cavity, especially next to the pulmonary hila.

The excellent late evolution of the patient leads us to believe that this is a safe alternative technique for cases of heart transplant in recipient patients with congenital total absence of the pericardium.

## References

1. Ladd W. Congenital absence of the pericardium. *N Engl J Med* 1936; 214: 183.
2. Samuels LE, Sharma S, Kaufman MS, Morris RJ, Brockman SK. Absent pericardium during coronary by-pass. *Arch Surg.* 1997; 132: 318-9.
3. vanSon JAM, Danielson GK, Schaff HV, Mullany CI, Julsrud PR, Breen J  
Congenital partial and complete absence of the pericardium. *May Clin Proc* 1993; 68: 743-7
4. Hammoudeh AJ, Kelly ME, Mekhjian H. Congenital total absence of the pericardium: Case report of a 72 – year – old man and review of the literature. *J Thorac Cardiovasc Surg* 1995; 109: 805-7.