

# Incidence of Intracardiac Thrombus and Thromboembolism in the First Three Months After Bioprosthetic Valve Implantation

Auristela Isabel de Oliveira Ramos, Helio Maximiano de Magalhães, Mercedes Maldonado, Dorival Júlio Della Togna, Zilda Machado Meneghelo, Antoninho Sanfins Arnoni, Lucia Machado, Nisia Lyra Gomes, Paulo Paredes Paulista  
São Paulo, SP - Brazil

## Objective

To assess the incidence of intracardiac thrombus and thromboembolism in the first 3 months after bioprosthetic valve replacement and to identify the risk factors for thrombus formation.

## Methods

The study comprised 184 patients, aged between 15 and 75 years, who underwent bioprosthetic valve implantation. Trans-thoracic and transesophageal (TEE) echocardiographies were performed in the in-hospital phase (mean,  $8.4 \pm 3$  days) and after 3 months (mean,  $97.4 \pm 21.7$  days).

## Results

The incidence of thrombus was significantly greater in patients with a prosthesis in the mitral or mitroaortic position (21.0%) than in those with a prosthesis in the aortic position (2.8%),  $P < 0.001$ . The multiple logistic regression identified the prosthesis in the mitral or mitroaortic position as the only independent variable for thrombus formation. On the 3-month follow-up, TEE showed a thrombus in 35 (20.7%) of the 169 patients on echocardiographic assessment, 31.7% in mitral patients and 3.1% in aortic patients,  $P < 0.001$ . In the third month, the multiple logistic regression also identified the prosthesis in the mitral or mitroaortic position as the only independent variable for thrombus formation. During the 3-month follow-up, 3 (1.6%) patients died and 8 (4.3%) experienced embolic phenomena, all in the cerebral territory.

## Conclusion

The incidence of thrombi in the first 3 months after bioprosthetic valve implantation was 14.1% in the first 10 days and 20.7% in 3 months. A prosthesis in the mitral or mitroaortic position was identified as a risk factor for thrombus formation. The incidence of embolic phenomena clinically diagnosed was lower than the proportion of atrial thrombi documented on echocardiography.

## Keywords

bioprosthetic valve, thromboembolism, valvular thrombosis

Instituto Dante Pazzanese de Cardiologia  
Mailing address - Auristela Isabel de Oliveira Ramos - Av. Miruna,  
327/44 - Cep 04084-001 - São Paulo, SP, Brazil  
E-mail: aisabel@cardiol.br  
Received for publication: 01/19/2004  
Accepted for publication: 07/21/2004  
English version Stela Maris Costalonga

Although bioprostheses are less thrombogenic than mechanical prostheses, several reports of thromboembolism related to their use exist, mainly in the first 3 months after their implantation<sup>1-5</sup>. Three basic mechanisms for the formation of intracardiac thrombi after prosthetic implantation may be identified as follows: 1) the first involves a molecular interaction between blood components, plasma, and the artificial surface of the prostheses; 2) the second depends on the influence of transprosthetic blood flow and residual stenosis; and 3) the third refers to states of hypercoagulability, loss of atrial contraction, imperfections on the prosthetic surfaces, and incomplete endothelialization of the prosthetic ring<sup>2</sup>. In addition, the glutaraldehyde used for valve preservation, even in low concentrations, is also deleterious to the endothelium<sup>6</sup>.

Although their independent role in thrombus formation has not been confirmed, dilation of the cardiac chambers and left ventricular dysfunction are associated with a greater incidence of thrombotic events<sup>7</sup>. Another risk factor for thrombus formation is the spontaneous contrast<sup>8</sup> found in conditions of low blood-flow velocity. Some arrhythmias, particularly atrial fibrillation, have been associated with thrombus formation<sup>9-11</sup>. With the appearance of transesophageal echocardiography, the diameters and function of the atrial appendage could be directly assessed<sup>12</sup>, and, regardless of the cardiac rhythm, the disappearance of or decrease in blood flow velocity in the exit of the left atrial appendage has been associated with the presence of spontaneous contrast and thrombus formation<sup>13,14</sup>.

The impact of bioprosthesis implantation on the formation of intracardiac thrombus and on embolic complications, especially in patients with sinus rhythm, has been studied little in a prospective form, especially in our country. Therefore, the incidence of thrombus in the first 3 months after bioprosthetic implantation needs to be known, as do the risk factors that may influence thrombus formation, to justify the prescription of oral anticoagulants in that population of patients, as recommended by the guidelines of the American Heart Association and American College of Cardiology<sup>15</sup>.

This study aimed at assessing the incidence of intracardiac thrombus and thromboembolism in the first 3 months after porcine bioprosthetic valve implantation and at identifying the clinical, laboratory, and echocardiographic risk factors for thrombus formation after bioprosthesis implantation.

## Methods

This study comprised 184 patients, 107 (58.0%) women and 77 (42.0%) men, with ages ranging from 15 to 75 years (mean,

51.9 ± 15.9 years), 73.4% of whom were below the age of 65 years. One hundred twenty-three (66.8%) patients were operated on for correction of native valvular heart disease and 61 (33.2%) for correction of prosthetic dysfunction. Sinus rhythm was present in 131 (71.0%) patients, atrial fibrillation in 52 (28.5%), and one (0.5%) patient had a definitive pacemaker. The bioprosthesis was implanted in the mitral position in isolation or in association with another in the aortic position in 114 (62%) patients, and in the aortic position in isolation in 70 (38%) patients.

The inclusion criteria were as follows: patients aged between 15 and 75 years, with mitral or aortic valve disease, or both, of any etiology or prosthetic dysfunction, who were hospitalized for bioprosthesis implantation. The patients who had transoperative stroke as a complication were excluded from the study.

Transthoracic Doppler echocardiography was performed on the following 3 occasions: before patient's admission for surgical correction; in the in-hospital phase of prosthetic implantation; and 3 months after hospital discharge. The diameters of the left atrium and ventricle were measured by using M mode, based on the images acquired on the transthoracic study. The left atrial telesystolic anteroposterior diameter was obtained through the left parasternal route, with the image of left ventricular long axis. For measuring the left ventricular end-diastolic and systolic diameters, a cross-sectional cut of that cavity was obtained at the level of the papillary muscles. The left ventricular systolic function was conventionally assessed through calculation of the ejection and shortening fractions<sup>16</sup>. The blood flow velocities of left atrial appendage emptying were obtained with pulsed Doppler, by placing the volume sample in the outflow tract of the left atrial appendage<sup>12</sup>. The area of the mitral prosthesis and the pressure gradients were obtained by using Doppler echocardiography, pressure half-time calculation, and the Bernoulli equation<sup>17</sup>.

Transesophageal echocardiography was performed after bioprosthesis implantation on 2 occasions: in the in-hospital phase of implantation and 3 months after hospital discharge. For performing the biplanar and multiplanar transesophageal studies, the guidelines and technical recommendations for image acquisition examinations were followed<sup>18,19</sup>.

Echocardiographic spontaneous contrast was defined as an image resembling smoke, which moved slowly and circularly in the left atrium. The contrast was graded from zero to 4 crosses as follows: zero, absence of spontaneous contrast; 1+, small amount of spontaneous contrast; 2+, moderate amount; 3+, large amount; and 4+, intense degree of spontaneous contrast<sup>20</sup>.

Intracardiac thrombus was defined as the presence of a circumscribed mass with echogenicity different from that of the atrial wall. It was classified as mural when it had a laminar aspect and a wide base occupying one of the walls of the atrial cavity. It was classified as nodular or pedunculated when presenting as a mobile nodule fixed to the atrial wall by a point<sup>21</sup>.

The following were defined as embolic events: any embolic event in the absence of endocarditis, including any permanent or transient neurologic alteration, and the presence of clinical findings compatible with peripheral arterial ischemia, independent of laboratory confirmation.

On the first day after prosthetic implantation, subcutaneous heparin was initiated at the dosage of 10,000 U, every 12 hours. On the second postoperative day, oral anticoagulation was initiated

in patients with socioeconomic and geographic conditions favoring an adequate control of anticoagulation, and who had no medical contraindication for that therapy. The patients who lacked conditions for anticoagulation therapy received from the second postoperative day onward 200 mg of acetylsalicylic acid, which was maintained until the third month in patients with no risk factors for thromboembolism, and for undetermined time in patients with risk factors.

The calculation of the sample was performed based on a study, in which the incidence of thrombus in the immediate postoperative period after bioprosthetic implantation was 12.5%<sup>3</sup>. Considering an absolute precision of 5.0% and a significance level of 5.0%, the minimum size of the sample was estimated in 162 patients.

The quantitative variables were described as mean and standard deviation. The comparison of the means was performed with the Student *t* test for independent populations or for correlate populations, according to the case. The qualitative and categorical variables were presented as percentages, and their comparisons were performed with the chi-square test or Fisher exact test, when indicated. To assess the possible relation between the dependent variable "thrombus" and some independent variables, multiple logistic regression was performed with the forward stepwise selection test. The variables included in the multivariate analysis were those identified in the univariate analysis and those considered of clinical relevance. The statistical analyses were performed by using the SPSS for Windows program, version 8.0. The statistical significance level adopted was  $P = 0.05$ <sup>22</sup>. For comparing patients with and without thrombi, and considering the site of prosthetic implantation, the patients were divided into the following 2 groups: patients with prosthesis in the mitral or mitroaortic positions, and patients with prosthesis in the aortic position.

## Results

The time interval between bioprosthesis implantation and performance of the echocardiography in the in-hospital phase ranged from 5 to 25 days (mean =  $8.4 \pm 3$  days). Intracardiac thrombus was documented in 26 (14.1%) of 184 patients or 1.7/100 patients/day. The incidence of thrombus was significantly higher in patients with bioprosthesis in the mitral or mitroaortic position (21.0%) than in those with aortic bioprosthesis (2.8%) (fig. 1). A thrombus was evidenced in the left atrial cavity in 16 (61.5%) patients, in the mitral prosthesis in 6 (23.1%), and in the atrial appendage in 4 (15.4%). In the 2 aortic patients with thrombi, they were located in the left atrium. A thrombus was evidenced in 18 (16.8%) of the 107 women and in 8 (10.4%) of the 77 men ( $P=0.21$ ). The lower incidence of thrombus occurred in the age group from 15 to 29 years (4.5%). The plasma fibrinogen level was more elevated in patients with thrombus,  $409 \pm 126$  mg/dL versus  $361 \pm 116$  mg/dL ( $P=0.05$ ). Of the 184 patients, 159 (86.4%) were discharged from the hospital and prescribed acetylsalicylic acid, and 25 (13.6%) were prescribed oral anticoagulation (fig. 2).

From the viewpoint of the valvular lesion, or the type of prosthetic dysfunction before prosthetic implantation, 58 patients had been diagnosed with stenosis, 43 with regurgitation, and 13 with mitral double lesion. On the occasion of surgery, a thrombus was observed in 9 (7.9%) of those patients, all with valvular stenosis.

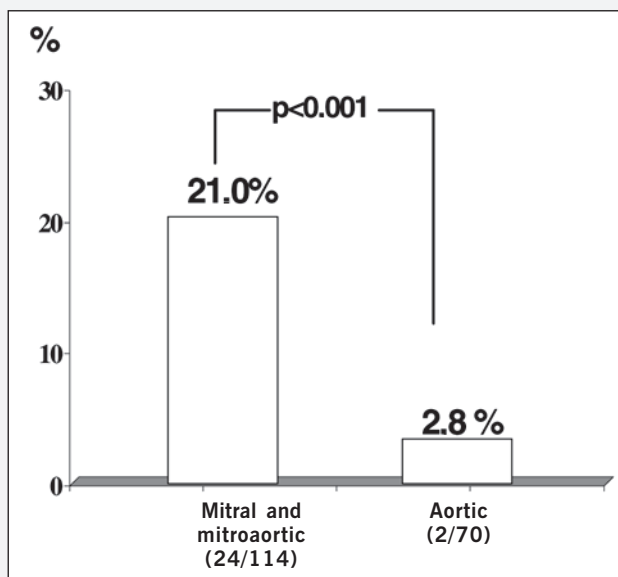


Fig. 1 – Incidence of atrial thrombus in the immediate postoperative period in patients with a prosthesis in the mitral and mitroaortic position and in the aortic position. The absolute number of patients is written in parentheses.

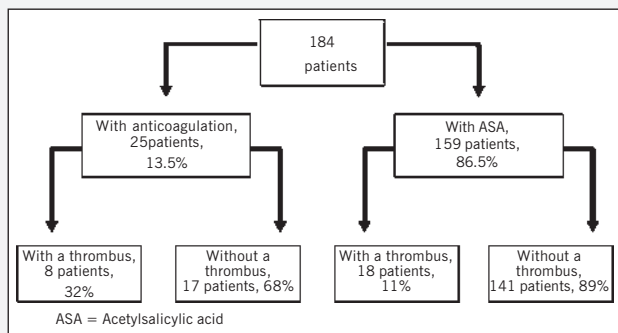


Fig 2 – Flowchart showing the distribution of patients with and without a thrombus in the immediate postoperative period and of patients who received or did not receive oral anticoagulation therapy.

The incidence of thrombus was similar in the patients operated on due to native valvular heart disease or due to prosthetic dysfunction (13.8% versus 14.8%,  $P=0.86$ ). The postoperative transesophageal echocardiography revealed thrombus in 3 (33.3%) of 9 patients undergoing thrombus resection. The incidence of thrombus was significantly more elevated in patients who evolved with paroxysmal atrial fibrillation and heart failure in the immediate postoperative period (26.7% versus 10.1%,  $P=0.005$ ). After prosthetic implantation, 126 (68.5%) patients had sinus rhythm, 53 (28.8%) had atrial fibrillation, and 5 (2.7%) had complete atrioventricular block. A thrombus was evidenced in 12 of 53 (22.6%) patients with atrial fibrillation and in 14 of 126 (11.1%) patients with sinus rhythm (fig. 3). When compared with patients in sinus rhythm, patients with atrial fibrillation had a higher mean age ( $55.9 \pm 13.7$  versus  $50.3 \pm 16.5$  years,  $P=0.03$ ), greater left atrial diameters ( $62.8 \pm 15.7$  mm versus  $48.8 \pm 9.2$  mm,  $P<0.0001$ ), lower blood flow velocities in the left atrial appendage ( $0.25 \pm 0.11$  m/s versus  $0.44 \pm 0.16$  m/s,  $P<0.0001$ ), a greater incidence of degree 3+ or 4+ spontaneous contrast (82.9% versus 17.1%,  $P<0.0001$ ), and a greater number of prostheses implanted in the mitral and mitroaortic position (42.1% versus 5.8%,  $P<0.0001$ ). The analysis of the subgroup of 126 patients with sinus rhythm revealed no difference between patients with and without thrombus in regard to mean age ( $50.5 \pm 14$  versus 50.3

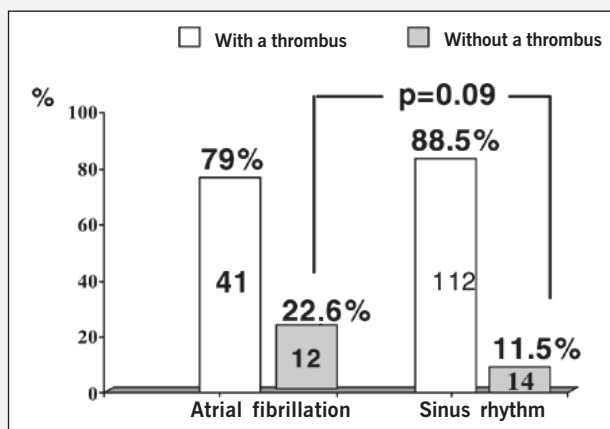


Fig. 3 – Incidence of atrial thrombus in patients with atrial fibrillation and sinus rhythm in the immediate postoperative period. The values shown within the bars correspond to the absolute number of patients with and without a thrombus

$\pm 16.9$  years), the left atrial diameters ( $48.2 \pm 5.4$  cm versus  $45.7 \pm 6.5$  cm), and the ejection fraction ( $55 \pm 17.4\%$  versus  $52.3 \pm 12.5\%$ ). No thrombus was evidenced in any of the 21 patients with no spontaneous contrast; on the contrary, a thrombus was found in 11.5% of the patients with degree 1+ or 2+ spontaneous contrast, and in 50.0% of the patients with degree 3+ or 4+ spontaneous contrast ( $P=0.003$ ).

The transthoracic echocardiographic data obtained before valvular replacement are shown in table I. The analysis of results showed no statistically significant difference between patients with and without a thrombus, in regard to the mean diameters of the left atrial and ventricular cavities, and ejection fraction. The analysis of the echocardiographic data obtained in the immediate postoperative period showed that the patients with a thrombus had greater left atrial diameters, lower blood flow velocities in the left atrial appendage, and continued with similar mean ventricular diameters and mean left ventricular ejection fractions (tab. II). The mean of the mitral prosthetic areas was lower in patients with thrombi than that in patients who did not have a thrombus ( $2.2 \pm 0.5$  cm<sup>2</sup> versus  $2.5 \pm 0.4$  cm<sup>2</sup>,  $P=0.02$ ). Spontaneous contrast was evidenced in 163 (88.5%) of the 184 patients studied. The incidence of thrombus in patients with degree 1+ or 2+ spontaneous contrast was 10.0%, and, in patients with degree 3+ or 4+, it was 37.0%. No thrombus was diagnosed in the 21 patients without spontaneous contrast. All patients without spontaneous contrast had sinus rhythm, while 83.0% of those with

Table I – Echocardiographic data obtained in the preoperative period in patients with and without a thrombus			
Variable	With a thrombus 26 Patients	Without a thrombus 158 Patients	P
Left atrial diameter (mm)	$56.8 \pm 12.4$	$52.1 \pm 13.0$	NS
Left ventricular end-diastolic diameter (mm)	$54.8 \pm 7.8$	$59 \pm 12$	NS
Left ventricular end-systolic diameter (mm)	$36.9 \pm 10.3$	$46.5 \pm 10.4$	NS
Ejection fraction (%)	$61.9 \pm 11.7$	$53.8 \pm 11.8$	NS
NS = no statistical significance.			

**Table II – Echocardiographic data obtained in the immediate postoperative period in patients with and without a thrombus**

Variable	With a thrombus 26 Patients	Without a thrombus 158 Patients	P
Left atrial diameter (mm)	52.0 ± 7.2	48.4 ± 8.6	0.05
Left atrial appendage blood flow velocity (m/s)	0.32 ± 0.17	0.41 ± 0.17	0.03
Left ventricular end-diastolic diameter (mm)	53.9 ± 8.8	54.7 ± 9.9	NS
Left ventricular end-systolic diameter (mm)	39.6 ± 11	41.1 ± 11.4	NS
Ejection fraction (%)	54.1 ± 12.8	52.5 ± 12.8	NS
NS = no statistical significance.			

spontaneous contrast, degree 3+ or 4+, were in atrial fibrillation. The mean blood flow velocity in the left atrial appendage was  $0.51 \pm 0.16$  m/s in patients with no spontaneous contrast,  $0.42 \pm 0.16$  in patients with degree 1+ or 2+ spontaneous contrast, and  $0.22 \pm 0.12$  m/s in patients with degree 3+ or 4+ spontaneous contrast ( $P=0.004$ ).

In the logistic regression analysis, the following variables were part of the model: cardiac rhythm, postoperative left atrial diameter, blood flow velocity in the atrial appendage, degree of spontaneous contrast in the left atrium, site of prosthetic implantation, association with other surgical procedures, postoperative complications, and preoperative fibrinogen levels. The bioprosthesis in the mitral position was the only variable identified as an independent marker of thrombus formation. When the multivariate analysis of logistic regression was performed in the subgroup of 114 mitral and mitroaortic patients, the prosthetic area and transprosthetic gradient were added to the already cited variables. The valvular area of the prosthesis was the only independent marker of thrombus identified through that analysis.

After hospital discharge, 3 (1.6%) of the 184 patients died, and 12 (6.5%) refused to repeat the transesophageal echocardiography, but went to medical consultation or were interviewed by telephone. Therefore, the 3-month echocardiographic follow-up was possible in 169 (91.8%) patients. The time interval between bioprosthesis implantation and performance of transesophageal echocardiography ranged from 49 to 193 days (mean =  $97.4 \pm 21.7$  days). A thrombus was documented in 35 (20.7% or 0.21/100 patients/day) of the 169 patients who repeated transesophageal echocardiography 3 months after prosthetic implantation; 33 of the 104 (31.7%) patients with mitral and mitroaortic prosthesis, and 2 of the 65 (3.1%) patients with aortic prosthesis,  $P<0.001$ . The thrombus was located in the mitral prosthesis in 18 (51.4%) patients, in the left atrium in 9 (25.7%), in the atrial appendage in 3 (8.6%), and in the left atrium and in the prosthesis in 5 (14.3%). Of the 26 patients who were discharged from the hospital with the diagnosis of a thrombus, 25 (96.0%) underwent echocardiography after 3 months. Eight patients were discharged from the hospital and prescribed oral anticoagulants, and 18 were prescribed acetylsalicylic acid. A thrombus was evidenced in 2 patients using anticoagulants and in 11 patients using acetylsalicylic acid. Of the 158 patients with no thrombus in the in-hospital period, 17 were discharged using oral anticoagulants and 141

patients were discharged using acetylsalicylic acid. Echocardiography was performed in all 17 patients on anticoagulation therapy and evidenced a thrombus in one (5.8%). No echocardiography was performed in 14 of the 141 patients using acetylsalicylic acid because 3 died and 11 did not show up for consultation. Of the 127 patients who underwent echocardiography, a thrombus was evidenced in 21 (16.5%).

A thrombus was evidenced in 17.8% of the patients with sinus rhythm and in 31.8% of those with atrial fibrillation ( $P=0.08$ ). When analyzing the 120 patients with sinus rhythm, those with and without thrombi did not differ in regard to the mean ejection fraction ( $55.7 \pm 15.3\%$  versus  $56.7 \pm 15\%$ ,  $P=0.76$ ), blood flow velocity in the left atrial appendage ( $0.39 \pm 0.15$  m/s versus  $0.44 \pm 0.15$  m/s,  $P=0.21$ ), and left atrial diameter ( $48 \pm 6.9$  mm versus  $44 \pm 6.5$  mm,  $P=0.17$ ). However, a thrombus was evidenced in 17.8% of the patients with degree 1+ or 2+ spontaneous contrast, in 50.0% of the patients with degree 3+ or 4+ spontaneous contrast, and in no patient without spontaneous contrast ( $P=0.04$ ). In the 19 patients undergoing exclusion of the atrial appendage, blood flow in its interior was observed in 3 (15.7%) patients. The echocardiographic data obtained showed a greater incidence of thrombus in patients with greater left atrial diameters and with lower blood flow velocities in the atrial appendage, according to data in table III. Of the 169 patients undergoing transesophageal echocardiography, 155 (91.7%) had spontaneous contrast. Thrombus was documented in 22 (17.5%) of the 126 patients with degree 1+ or 2+ spontaneous contrast, and in 13 (44.8%) of the 29 patients with degree 3+ or 4+ spontaneous contrast,  $P=0.001$ . No thrombus was evidenced in 14 patients without spontaneous contrast (fig. 4). In multivariate analysis of logistic regression, the variables included were selected based on the results obtained in univariate analysis. The variables analyzed were as follows: position of the prosthesis, cardiac rhythm, pre- and postoperative left atrial diameters, blood flow velocity in the left atrial appendage, and presence of spontaneous contrast. The results indicated only the prosthesis in the mitral position as an independent marker of thrombosis. However, when the subgroup of patients with a prosthesis in the mitral or mitroaortic position was selected, the multivariate analysis identified no risk factor for thrombus formation in 3 months.

**Table III – Echocardiographic data obtained 3 months after prosthetic implantation in patients with and without a thrombus**

Variable	With a thrombus 35 Patients	Without a thrombus 135 Patients	P
Left atrial diameter (mm)	51.8 ± 11.9	46.6 ± 8.2	0.003
Left atrial appendage blood flow velocity (m/s)	0.33 ± 0.16	0.42 ± 0.16	0.01
Left ventricular end-diastolic diameter (mm)	55.1 ± 14.8	53.3 ± 9.5	NS
Left ventricular end-systolic diameter (mm)	38.1 ± 11	37.8 ± 10.3	NS
Ejection fraction (%)	55.9 ± 14.7	55.5 ± 14.5	NS
NS = no statistical significance.			

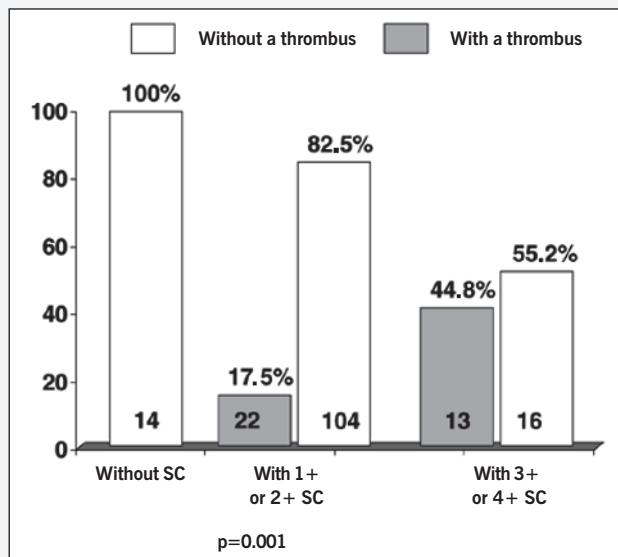


Fig. 4 - Distribution of the patients with and without a thrombus, without spontaneous contrast (SC) and degrees 1+ or 2+ and 3+ or 4+ spontaneous contrast, 3 months after bioprosthesis implantation. The values shown within the bars correspond to the absolute number of patients.

Emboic phenomena occurred in 8 (4.3%) patients as follows: 3 in the in-hospital period and 5 during late follow-up. All emboli were to the cerebral territory. The linear incidence was 0.05/100 patients/day. Six (75%) patients had a prosthesis in the mitral position, 5 (62.5%) had atrial fibrillation, and 3 (37.5%) had a thrombus on echocardiography performed 3 months after valve replacement.

## Discussion

In the first 3 months after bioprosthesis implantation, the incidence of embolic phenomena has been reported as ranging from 0.2 to 10.0%/year<sup>1-5</sup>. These variations shown in the studies in patients with the same type of prosthesis suggest that the embolic phenomena are not directly related to the prosthesis, but to the characteristics of the population studied, to the design of the study, to the incorrect definitions of the complications or to the method of data collection and analysis. Most studies analyzing the thrombotic complications of the prostheses refer to embolic complications and not to the presence of an intracardiac thrombus. Our study was the first to assess the presence of intracardiac thrombus after bioprosthetic implantation by using transesophageal echocardiography in the immediate postoperative period and 3 months after bioprosthetic implantation. In economically developed countries, valvular heart disease predominates in men, with a mean age greater than 60 years, affecting mainly the aortic valve<sup>4</sup>. In our study, however, women predominated (58.0%); the mean age was  $51.9 \pm 15.9$  years, 73.0% of the patients being younger than 64 years; and the mitral valve was affected in 62.0% of the cases. The incidence of intracardiac thrombus was elevated in the first 3 months following bioprosthetic implantation in mitral and mitroaortic patients. In the in-hospital period, a thrombus was more frequently found on the left atrial wall (61.5%), suggesting that thrombus formation may be linked not only to hemodynamic alterations secondary to mitral valvular disease, but also to local changes in the atrial wall due to atriotomy and surgical manipulation. These observations are in accordance with those reported in autopsy studies performed within the

first 60 days after bioprosthetic implantation<sup>3,23</sup>. On the other hand, in the third month, the thrombus was most frequently found on the mitral prosthesis, followed by the left atrium, suggesting that, in addition to the above-cited factors, the prosthesis is the most important substrate in the pathogenesis of thrombus in a later period. Before valvular replacement, the echocardiographic data obtained were similar in patients with and without a thrombus. In the immediate postoperative period, however, a reduction in the left atrial diameters was observed in both groups, but in a lower proportion in patients with a thrombus. The dysfunction in the left atrial appendage was more marked in patients with a thrombus. These results were similar to those reported by Li et al<sup>9</sup>, when they identified the peak velocity of left atrial appendage emptying as the only independent variable for arterial embolism. The presence and intensity of spontaneous contrast were clearly related to thrombus formation. No patient without spontaneous contrast developed a thrombus, while 37.0% of the individuals with degree 3+ or 4+ spontaneous contrast developed a thrombus. The role played by spontaneous contrast in intracardiac thrombus formation and in the association with embolic phenomena has been well demonstrated, because, most of the time, it relates to heart diseases, mainly mitral, to the presence of atrial fibrillation, to greater left atrial diameters, and to the low blood flow velocity in the left atrial appendage<sup>7-10</sup>. In our study, the patients with degree 3+ or 4+ spontaneous contrast had the lowest blood-flow velocities in the left atrial appendage, the greatest left atrial diameters and the greatest percentage of atrial fibrillation compared with the patients without spontaneous contrast or with degree 1+ or 2+ spontaneous contrast. When the subgroup of mitral and mitroaortic patients was analyzed aiming at identifying independent variables for thrombus formation, only the prosthetic area was selected on multivariate analysis. Although the difference between the means of the valvular areas in patients with and without thrombus was small ( $2.2 \pm 0.5$  versus  $2.5 \pm 0.4$  cm<sup>2</sup>), their medians were different, and 75.0% of the patients without a thrombus had a prosthetic area greater than 2.2 cm<sup>2</sup>, while 50.0% of the patients with a thrombus had a prosthetic area lower than 2.2 cm<sup>2</sup>.

The atrial fibrillation rhythm has been reported as an independent marker of thrombus formation, mainly in patients with mitral stenosis<sup>10,11</sup>. Our study showed that the incidence of thrombosis in patients with atrial fibrillation was twice that in patients with sinus rhythm (21.2% x 11.5%), but it did not reach statistical significance. However, when only the mitral and mitroaortic patients were analyzed, 42.1% of the patients were observed to have atrial fibrillation, and, even so, the cardiac rhythm did not relate to thrombus formation. When analyzing only the patients with sinus rhythm, the only echocardiographic variable related to thrombus formation in the immediate and late postoperative periods was the presence of degree 3+ or 4+ spontaneous contrast. These observations allow inferring that the sinus rhythm did not offer protection against thrombus formation in patients with recent bioprosthetic implantation. On the other hand, the degree of spontaneous contrast and postoperative complications, such as congestive heart failure and paroxysmal atrial fibrillation, facilitated thrombus formation. Exclusion of the atrial appendage has been performed to prevent thrombus formation in patients with atrial fibrillation. By using transesophageal echocardiography, however, signs of residual communication between the atrial appendage and left atrial body have been reported and related to thrombus formation<sup>24</sup>.

In our study, of the 114 mitral and mitroaortic patients, 50.8% had a preoperative diagnosis of mitral stenosis, 37.7% had a diagnosis of mitral regurgitation, and 11.4% had a diagnosis of double mitral lesion. The incidence of thrombus detected during surgery was 7.8% in patients with mitral stenosis, and no thrombus was evidenced in patients with mitral regurgitation or double lesion. In the postoperative period, transesophageal echocardiography detected a thrombus in 20.9% of the patients with mitral regurgitation, in 38.5% of patients with mitral double lesion, and in 17.2% of patients with mitral stenosis. This shows that the incidence of thrombus after prosthetic implantation was lower in patients with a stenotic-type lesion.

Although fibrinogen measurement does not assess blood coagulation, it has been used in studies about prosthetic thrombus. Several mechanisms may contribute to the increase in plasma fibrinogen in native valvular disease, such as the following: the increase in the hepatic synthesis of fibrinogen; the presence of hemoconcentration secondary to the use of diuretics; the non-physiological turbulence due to hemodynamic disorders that lead to alteration in the coagulation factors; the formation of products of fibrin degradation; the increase in blood viscosity; and the aggregation of red blood cells<sup>25,26</sup>.

Although the relation between left atrial thrombosis and systemic embolism has not been totally clarified, patients with atrial fibrillation and left atrial thrombus are known to have more embolic phenomena than those without a thrombus<sup>27,28</sup>.

The prescription of oral anticoagulants for preventing thromboembolism in the first 3 months after bioprosthetic implantation has been widely recommended<sup>15,29-31</sup>. Anticoagulants, however, are drugs that increase the cost of the treatment, because they in-

crease the length of hospital stay and require frequent laboratory control, in addition to increasing the risk of bleeding. Randomized studies of warfarin versus placebo carried out in the United States of America reported that only 10.0% of the patients could be randomized and that 38.0%/patients/year discontinued treatment<sup>32</sup>. In this study, only 10.0% of the patients could undergo anticoagulation. Although our study was not designed to assess effectiveness of oral anticoagulation therapy for thrombus prevention after bioprosthetic implantation, and 90.0% of the patients did not receive oral anticoagulation, one may suggest that that medication is not necessary for patients with implantation of an isolated aortic prosthesis, due to the low incidence of thrombosis and absence of embolic complications in that group of patients. These suggestions are in accordance with those of other authors, who assessed patients with aortic bioprosthesis using or not using oral anticoagulants and found no benefit in prescribing that medication<sup>33</sup>. On the other hand, in mitral and mitroaortic patients, the incidence of intracardiac thrombus was high, even in the presence of sinus rhythm, with a 3.8-fold greater risk than that in the aortic patients, in association with embolic phenomena, which required the prescription of oral anticoagulants in patients with a prosthesis in the mitral position.

Among the limitations of the study, the following stands out: the nonrandomization of patients with sinus rhythm and prosthesis in the mitral position for the use of oral anticoagulants, platelet antiaggregation, or placebo. From the practical point of view, the major obstacle for performing that type of study in our country was the difficulty in randomizing patients who could adequately control oral anticoagulation, because the option of bioprosthetic implantation in young patients, who had already undergone previous surgeries, was due to some type of contraindication to anticoagulation.

## References

- Cohn LH, Allred EN, Disesa VJ, et al. Early and late risk of mitral valve replacement: a 12-year concomitant comparison of the porcine bioprosthetic and prosthetic disc mitral valves. *J Thorac Cardiovasc Surg* 1984; 88: 695-705.
- Piper C, Hering D, Horstkotte D. Prosthetic valve thrombosis: predisposition and diagnosis. *Eur Heart J* 2001; 3(suppl Q): 16-21.
- Thiene G, Bortolotti U, Panizzon G, Milano A, Gallucci V. Pathological substrates of thrombus formation after heart valve replacement with the Hancock bioprosthesis. *J Thorac Cardiovasc Surg* 1980; 80: 414-23.
- Heras M, Chesebro JH, Fuster V, et al. High risk of thromboemboli early after bioprosthetic cardiac valve replacement. *J Am Coll Cardiol* 1995; 25: 1111-19.
- Gonzalez-Lavin L, Tandon AP, Chi S, et al. The risk of thromboembolism and hemorrhage following mitral valve replacement. *J Thorac Cardiovasc Surg* 1984; 87: 340-51.
- Levy RJ. Editorial: Glutaraldehyde and the calcification mechanism of bioprosthetic heart valves. *J Heart Valve Dis* 1994; 3: 101-4.
- Burchfiel CM, Hammermeister KE, Krause-Steinrauf H, et al. Left atrial dimension and risk of systemic embolism in patients with a prosthetic heart valve. *J Am Coll Cardiol* 1990; 15: 32-41.
- Fatkin D, Kelly RP, Feneley MP. Relations between left atrial appendage blood flow velocity, spontaneous echocardiographic contrast and thromboembolic risk in vivo. *J Am Coll Cardiol* 1994; 23: 961-9.
- Li Y, Hwang J, Lin J, Tseng Y, Lien W. Importance of left atrial appendage function as a risk factor for systemic thromboembolism in patients with rheumatic mitral valve disease. *Am J Cardiol* 1996; 78: 844-47.
- Lip GYH. The prothrombotic state in atrial fibrillation: New insights, more questions, and clear answers needed. *Am Heart J* 2000; 140: 348-50.
- Al-Saady NM, Sopher M. Prothrombotic markers in atrial fibrillation: what is new? *Eur Heart J* 2001; 22: 1635-39.
- Pollick C, Taylor D. Assessment of left atrial appendage function by transesophageal echocardiography. Implications for the development of thrombus. *Circulation* 1991; 84: 223-31.
- García-Fernández MA, Torrecilla EG, Román DS, et al. Left atrial appendage Doppler flow patterns: implications on thrombus formation. *Am Heart J* 1992; 124: 955-60.
- Kamp O, Verhorst PMJ, Welling RC, Visser CA. Importance of left atrial appendage flow as a predictor of thromboembolic events in patients with atrial fibrillation. *Eur Heart J* 1999; 20: 979-85.
- American College of Cardiology/American Heart Associations. Guidelines for the management of patients with valvular heart disease. *J Am Coll Cardiol* 1998; 32: 1486-588.
- Sahn DJ, Demaria A, Kisslo J, Weyman A. Recommendations regarding quantitation in M-mode echocardiography measurements: results of a survey of echocardiographic measurements. *Circulation* 1978; 58: 1077-83.
- Thomas JD, Weyman AE. Doppler mitral pressure half-time: a clinical tool in search of theoretical justification. *J Am Coll Cardiol* 1987; 10: 923-9.
- Frazin L, Talano JV, Stephanides L, Loeb HS, Kopel L, Gunnar Rm. Esophageal Echocardiography. *Circulation* 1976; 54: 102-8.
- Seward JB, Khandheria BK, Oh JK, et al. Transesophageal echocardiography: technique, anatomic correlations, implementations and clinical applications. *Mayo Clin Proc* 1988; 63: 649-80.
- Feigenbaum H. Echocardiography. 3rd ed. Coronary Artery Diseases. In: Echocardiography. 2nd ed. Philadelphia: Lea and Febinger. 1975; 341-80.
- Hwang J, Chen J, Lin S, et al. Diagnostic accuracy of transesophageal echocardiography for detecting left atrial thrombi in patients with rheumatic heart disease having undergone mitral valve operations. *Am J Cardiol* 1993; 72: 677-81.
- Fletcher RM, Fletcher SW, Wagner EM. Diagnostic. In: Fletcher RM, Wagner EM, ed. Epidemiologia clínica: Elementos essenciais. 1996; 3rd ed. Porto Alegre: Artes Médicas.
- Ben-Shachar G, Vlodayer Z, Joyce LD, Edwards JE. Mural thrombosis of the left atrium following replacement of the mitral valve. *J Thorac Cardiovasc Surg* 1981; 82: 595-600.
- Katz ES, Tsiamsiouris T, Applebaum RM, Schwartzbard A, Tunick PA, Kronzon I. Surgical left atrial appendage ligation is frequently incomplete: a transesophageal echocardiographic study. *J Am Coll Cardiol* 2000; 36: 468-71.
- Kannel WB, Wolf PA, Castelli WP, D'agostino RB. Fibrinogen and risk of cardiovascular disease. The Framingham Study. *JAMA* 1987; 258: 1183-6.
- Black IW, Chesterman CN, Hopkins AP, Lee LCL, Chong BH, Walsh WF. Hematolo-



- gic correlates of left atrial spontaneous echo contrast and thromboembolism in nonvalvular atrial fibrillation. *J Am Coll Cardiol* 1993; 21: 451-7.
27. Stoddard MF, Singh P, Dawn B, Longaker RA. Left atrial thrombus predicts transient ischemic attack in patients with atrial fibrillation. *Am Heart J* 2003; 145: 676-82.
  28. Sheahan RG. Left atrial thrombus, transient ischemic attack, and atrial fibrillation: does left atrial thrombus predict? Does absence protect? *Am Heart J* 2003; 145: 582-5.
  29. Blair KL, Hatton AC, White WD, et al. Comparison of anticoagulation regimens after carpentier-edwards aortic or mitral valve replacement. *Circulation* 1994; 90(suppl II): 214-219.
  30. Hirsh J, Fuster V, Ansell J, Halperin JL. American Heart Association/American College of Cardiology Foundation guide to warfarin therapy. *Circulation* 2003; 107: 1692-1711.
  31. Turpie AGG, Gunstensen J, Hirsh J, Nelson H, Gent M. Randomised comparison of two intensities of oral anticoagulant therapy after tissue heart valve replacement. *Lancet* 1988; 4: 1242-5.
  32. Petersen P, Boysen G, Godtfredsen J, Andersen ED, Andersen B. Placebo-controlled, randomised trial of warfarin and aspirin for prevention of thromboembolic complications of atrial fibrillation. The Copenhagen AFASAK Study. *Lancet* 1989; 1: 175-9.
  33. Babin-Ebell J, Schmidt W, Eigel P, Elert O. Aortic bioprosthesis without early anticoagulation - risk of thromboembolism. *Thorac Cardiovasc Surgeon* 1996; 43: 212-14.