

Myocardial Remodeling After Experimental Acute Myocardial Infarction in Rats. Effect of Renin-Angiotensin-Aldosterone System Blockade

Hindalis Ballesteros Epifanio, Leonardo Antonio Mamede Zornoff, Beatriz Bojikian Matsubara, Sergio Alberto Rupp de Paiva, Roberto Minoru Tani Inoue, Luiz Shiguero Matsubara
Botucatu, SP - Brazil

Objective

To assess the effect of lisinopril and losartan on myocardial remodeling in experimental infarction in rats.

Methods

Male Wistar rats underwent myocardial infarction and were either treated with lisinopril [20 mg/kg/day (LIS, n=13)] or losartan [20 mg/kg/day (LOS, n=11)], or kept without any treatment (NT, n=11) for 3 months. Their results were compared with those of a control group (CONT, n=11) comprising noninfarcted rats. After euthanasia, the left ventricle was isolated and weighed. The following measurements were taken: the sectional area of myocytes (AC), interstitial collagen fraction (CVF), and myocardial hydroxyproline (HOP). The variables were compared by using 1-way ANOVA, with a significance level of $P < 0.05$.

Results

Acute myocardial infarction caused left ventricular hypertrophy. The treatments with lisinopril or losartan could prevent hypertrophy, which was quantified by use of left ventricular weight (LOS=1.06±0.12g, LIS=0.97±0.18g, NT=1.26±0.17g, CONT=1.02±0.09g; $P < 0.05$), of left ventricular weight-to-body weight ratio LV/BW (LOS=2.37±0.21mg/g, LIS=2.41±0.38mg/g, NT=2.82±0.37mg/g, CONT=2.27±0.15mg/g), and of left ventricular AC measurement (LOS=210±39 μ^2 , LIS=217±35 μ^2 , NT=256±35 μ^2 , CONT=158±06 μ^2 ; $P < 0.05$). The CVF was significantly greater in the left ventricle of the infarcted group, and its increase was prevented with treatment (LOS=1.16±0.4%, LIS=1.27±0.5%, NT=1.8±0.4%, CONT=0.7±0.5%). Myocardial hydroxyproline was greater in the infarcted group (NT=6.91±2.98mg/g vs. CONT=2.81±1.21mg/g) and did not change with treatment.

Conclusion

Myocardial remodeling after infarction is characterized by an increase in the remaining ventricular mass and in interstitial collagen. The angiotensin-converting-enzyme blockers and the selective angiotensin II AT1 antagonist prevent hypertrophy of the myocyte and interstitial fibrosis.

Keywords

myocardial remodeling, experimental acute myocardial infarction, renin-angiotensin-aldosterone system

Faculdade de Medicina de Botucatu - UNESP
Mailing address: Luiz Shiguero Matsubara
Depto. de Clínica Médica, Faculdade de Medicina de Botucatu, UNESP. Rubião Júnior s/n - 18618-000 - Botucatu - SP, Brazil
E-mail: lsmatsu@cardiol.br
Received for publication: 4/16/03
Accepted for publication: 3/9/04
English version by Stela Maris Costalonga

Ventricular remodeling is an adaptive response of the heart to hemodynamic, neurohormone stimuli and to genetic factors. It is associated with a modification in the shape, size, composition, and function of the heart¹. Acute myocardial infarction is currently one of the most important causes of cardiac remodeling and significantly contributes to ventricular dilation, myocardial fibrosis, ventricular dysfunction, and development of congestive heart failure. Postinfarction remodeling is a phenomenon that begins right after coronary occlusion. In that phase, myocytic necrosis occurs, being followed by stretching of the infarcted area, which constitutes the expansion of the infarction. This may result in muscular rupture or formation of a ventricular aneurysm. Approximately 72 hours after the acute event, remodeling encompasses the entire heart. During that period, ventricular dilation, change in geometry, and hypertrophy of the remaining musculature is evident. The incapability of the heart to normalize wall stress results in progressive cardiac dilation, recruitment of the myocardium around the scar, and deterioration of the contractile function¹.

Although myocardial remodeling is a complex phenomenon involving several stimuli, the role of the renin-angiotensin-aldosterone system has gained special attention in the last decade. From the therapeutic point of view, the benefits of angiotensin-converting-enzyme inhibitors and of AT1 receptor blockers are innumerable²⁻⁴. However, it has not been well defined whether the effects of the 2 classes of drugs are comparable in regard to ventricular hypertrophy and interstitial fibrosis in the viable myocardium after acute coronary occlusion.

Lisinopril is an angiotensin-converting-enzyme inhibitor widely used in clinical practice for treating arterial hypertension, as well as an adjuvant drug for the treatment of acute myocardial infarction⁵⁻⁸. It inhibits the formation of angiotensin II and aldosterone. That drug has a direct hemodynamic effect on the vessels, reducing the afterload, and a beneficial effect on ventricular remodeling.

Blockade of the angiotensin II activity may also be obtained by use of antagonists of angiotensin type 1 (AT1) receptors. Recent studies have shown the beneficial effects of AT1 antagonists on myocardial remodeling after myocardial infarction with improvement in cardiac function, as well as an increase in survival⁹. Losartan is an antagonist of angiotensin II receptors. It acts through direct competition with angiotensin II for only one class of receptors (AT1), has a significant role in reducing the process of interstitial fibrosis³, and in reducing the mortality and morbidity associated with heart failure after acute myocardial infarction¹⁰.

This study aimed at assessing the role of an angiotensin-converting-enzyme inhibitor (lisinopril) and an AT1 receptor blocker (losartan) in myocardial remodeling in the heart of rats experiencing experimental infarction.

Methods

All procedures were submitted to and approved by the Ethical Committee on Animal Research and were in accordance with the ethical principles on animal experiments adopted by the Brazilian College of Animal Experiments.

This study used male Wistar rats from the Animal Facility of the University, whose weights ranged from 200 to 250g. The animals were anesthetized with an intraperitoneal injection of sodium pentobarbital (50 mg/kg) and underwent left lateral thoracotomy. After exteriorization of the heart, the left atrium was pushed aside and the left coronary artery was ligated with a 5.00 mononylon thread between the emergence of the pulmonary artery and the left atrium. Then, the heart was replaced into the thorax, the lungs inflated with positive pressure, and the thoracic wall was sutured with #10 cotton thread. After recovery from anesthesia, the animals were maintained in cages, fed a standard commercial food preparation, with free access to water. Three animals were placed in each cage, with control of light (12-hour cycles), temperature (approximately 25°C), and humidity.

The 35 surviving animals were divided into 3 groups: group NT (n=11), comprising infarcted animals, which received no medication; group LIS (n=13), comprising infarcted animals, which received lisinopril (20 mg/kg/day dissolved in drinking water); group LOS (n=11), comprising infarcted animals, which received losartan (20 mg/kg/day dissolved in drinking water). The treatment was initiated 12 hours after surgery and maintained for 3 months. Noninfarcted animals of the same race, sex, and age, and submitted to the same environmental conditions were used as controls (CONT, n=11). After 3 months, the animals were weighed (BW), anesthetized with intraperitoneal injection of sodium pentobarbital (50 mg/kg), and underwent euthanasia. Their hearts were removed, dissected, and the right and left ventricles, including the ventricular septum, were isolated and weighed.

Samples of the cardiac tissue were fixed in a solution of 10% formalin for 48 hours. After fixation, the tissue was embedded in paraffin blocks, and, then, 4-micron coronal histological sections were obtained. The histological slides were stained with a solution of hematoxylin and eosin or Masson's trichrome for assessing the sectional areas of myocytes (AC). The myocardial interstitium was assessed on 6-micron coronal histological sections stained using the picrosirius red technique, specific for visualizing collagen.

The histological sections stained with the hematoxylin and eosin solution or Masson's trichrome were used for measuring the sectional areas of the myocytes with a DM LS LEICA microscope coupled with a video camera, which sends a digital image to a computer that has the Image Pro-plus analysis program (Media Cybernetics, Silver Spring, Maryland, USA). Fifty to 70 cells per ventricle analyzed were measured. The myocytes selected were transversely sectioned, had a round shape, a visible central nucleus, and were located in the subendocardial layer of the right and left ventricular muscular wall. This aimed at maximum uniformity of

the sets of myocytes of the different groups. The mean areas obtained for each group were used as an indicator of cell size.

The histological sections stained with the picrosirius red solution were used for assessing the collagen fractions (CVF) present in the interstitium of the cardiac tissues of the right and left ventricles. Reading was performed with polarized light in the LEICA DM LS microscope coupled with a video camera that sends a digital image to a computer that has the Image Pro-plus analysis program (Media Cybernetics, Silver Spring, Maryland, USA). Thirty to 40 fields per ventricle were measured with a 40X objective. The fields chosen were located far from the infarcted area and from the perivascular region.

The biochemical quantification of hydroxyproline (HOP) was performed in a segment of myocardial tissue far from the infarcted area, according to a previously described method¹¹. The method is based on oxidation of a cardiac tissue hydrolysate in 6N HCl by chloramine T solution, followed by color obtainment by use of the reaction with the Ehrlich's solution and reading in optical density at a wave length of 565 nm.

The variables studied are presented as means and respective standard deviations, and the comparisons between the groups were performed using one-way analysis of variance (ANOVA), followed by the Tukey test, adopting a significance level of $P < 0.05$.

Results

The mean values and respective standard deviations of the body weights, ventricular weights, ventricular weights corrected for body weights, sectional areas of the myocytes, and myocardial concentrations of HOP are shown in table I.

No statistical difference was found in mean body weight (BW) between the groups of infarcted rats 3 months after treatment and the control group. No difference was found in the experimental groups (CONT: $36 \pm 7\%$; LIS: $36 \pm 6\%$; LOS: $39 \pm 6\%$) in regard to the infarcted area. The statistical analysis showed that the mean ventricular weights and the left ventricular weight-to-body weight ratio (LV/BW) were lower in groups LIS, LOS, and CONT when compared with those in group NT. No statistically significant difference was observed in the left ventricular weight and in the LV/BW ratio between the groups LIS and LOS. Acute myocardial infarction led to an increase in right ventricular mass, which was prevented by lisinopril, but not by losartan.

The statistical analysis showed that the sectional areas of the myocytes of the right and left ventricles in groups NT, LIS, and LOS were greater than those in group CONT ($P < 0.001$). The areas of the myocytes in groups LOS and LIS were significantly smaller than those in group NT ($P < 0.05$). No significant difference in the sectional area in both ventricles was observed between the groups LOS and LIS.

A statistically significant increase in the left ventricular CVF was observed in group NT as compared with that in groups CONT, LIS, and LOS. Group LIS had a left ventricular CVF significantly greater than that in group CONT, and no difference was observed between groups LIS and LOS. No statistically significant difference in the right ventricular collagen fraction was observed in the groups analyzed. The level of hydroxyproline in the left ventricle was significantly greater in the infarcted group as compared with that in the control group, independently of the treatment received.



Discussion

Acute myocardial infarction was accompanied by left and right ventricular hypertrophy as shown by the ventricular weights and measurements of the cellular areas. The results showed that muscular growth was highly compensatory, ie, the remaining myocytes had a hypertrophy that exceeded the area lost due to myocardial necrosis. According to the literature, this result suggests that hypertrophy is not due only to the mechanical stimulation of the elevation in the preload or afterload¹². Local mechanical stimuli, through stretching and activation of the mechanotransducers, associated with the inflammatory reaction due to myocytic necrosis cause release of growth factors that stimulate hypertrophy and fibrosis^{13,14}.

The right ventricle showed no infarcted area detected on optical microscopy, and the presence of right ventricular hypertrophy could be attributed to 2 factors: the mechanical stimulation triggered by pulmonary hypertension and activation of the systemic or local neurohormone system¹⁵. After acute myocardial infarction, different degrees of left ventricular diastolic dysfunction frequently occur. The consequences of that dysfunction are as follows: pulmonary arterial vasoconstriction, and right ventricular overload and hypertrophy. This hypertrophy could also result from the trophic action of the neurohormone mediators released after acute myocardial infarction, such as angiotensin II, which, by coupling with specific receptors activate intracellular mediators that cause the expression of proto-oncogenes, promoters of protein synthesis^{16,17}.

In the present study, the treatment of rats after acute myocardial infarction with lisinopril or losartan proved to be effective for preventing the increase in ventricular mass. The reductions in the right and left ventricular weights and in the ventricular weight-to-body weight ratio were significant in both measurements as compared with those in the nontreated infarcted group, and the parameters were reduced to levels similar to those in the noninfarcted control group. These results were similar to those obtained by other authors^{18,19}, who reported a reduction in the ventricular mass in infarcted hearts of rats treated with angiotensin-converting-enzyme inhibitor or with an antagonist of the angiotensin AT1 receptors. In the groups treated, the measurement of ventricular weight showed lack of mass gain; however, measurement of the myocytic cellular areas showed the occurrence of myocytic hypertrophy as compared with that in the noninfarcted control group. Therefore, the measurement of ventricular weight and of

ventricular weight-to-body weight ratio is not a good parameter for assessing myocardial hypertrophy in the presence of infarction. Therefore, depending on the size of the infarcted area, the measurement of ventricular weight tends to underestimate the presence of ventricular hypertrophy. Based on the results obtained, we observed that, in the presence of myocardial infarction, the measurement of the cellular area of the myocyte is a better index of ventricular hypertrophy than the parameter of ventricular weight.

The measurement of left ventricular collagen fraction (CVF) showed an increase in interstitial fibrosis in remote areas of infarction (tab. I, fig. 1). In the present study, a smaller CVF was observed in the infarcted groups treated with lisinopril or losartan. These results were similar to those found by other researchers, who reported prevention of interstitial fibrosis in animals treated with angiotensin-converting-enzyme inhibitors or with antagonists of the angiotensin II AT1 receptors^{3,20-22}.

Greater levels of right ventricular CVF were found in infarcted rats. However, no significant differences were detected between the groups studied. We believe that the great variability in these data associated with the small size of the sample may have hindered the detection of the statistical difference. We have also observed smaller CVF values than those reported in the literature. The use of linear polarized light filter (fig. 1) seems to underestimate the CVF value, suggesting that the ideal method would be the use of a circular polarized light filter²³. As the same methodology was used in all groups, the comparison between them could be established.

The HOP value was significantly greater in group NT as compared with that in groups CONT, LIS, and LOS. Unlike CVF measurement, that of HOP was not sufficiently sensitive to detect the modifications in myocardial fibrosis due to treatment. However, we cannot exclude the possibility of including peri-infarction tissue in HOP quantification, which could falsify the effect of the treatment on interstitial fibrosis. Thus, in this model of experimental infarction and in regard to the analysis of myocardial fibrosis, we can assume that CVF measurement is more reliable than HOP quantification, because direct histological viewing allows the definitive exclusion of the scar area.

In conclusion, myocardial remodeling after acute myocardial infarction results mainly from hypertrophy of the remaining myocytes and interstitial fibrosis. Postinfarction hypertrophy of myocytes and interstitial fibrosis may be prevented by using angiotensin-converting-enzyme inhibitors (lisinopril) or an AT1 receptor antagonist (losartan). Further studies are required to establish whether

Table I - Means and standard deviations of the variables studied in the following groups of rats: noninfarcted (CONT). nontreated infarcted (NT). lisinopril-treated infarcted (LIS). and losartan-treated infarcted (LOS).

	CONT (n=11)	NT (n=11)	LIS (n=13)	LOS (n=11)
BW (g)	448±42	448±48	404±44	446±47
LV (g)	1.02±0.09	1.26±0.17*	0.97±0.18#	1.06±0.12#
LV/BW (mg/g)	2.27±0.15	2.82±0.37*	2.41±0.38#	2.37±0.21#
RV (g)	0.29±0.05	0.58±0.17*	0.38±0.14#	0.53±0.18*§
RV/BW (mg/g)	0.65±0.08	1.30±0.41*	0.96±0.36#	1.17±0.37*
LV AC (μ ²)	158±06	256±35*	217±35*#	210±39*#
RV AC (μ ²)	154±11	266±34*	206±38*#	216±34*#
LV CVF (%)	0.71±0.49	1.80±0.40*	1.27±0.52*#	1.16±0.41#
RV CVF (%)	0.99±0.44	1.57±0.69	1.52±1.01	1.80±0.77
LV HOP (mg/g)	2.81±1.21	6.91±2.98*	5.63±1.79*	5.59±1.16*

BW: body weight; LV- left ventricle; RV- right ventricle; AC- cell area; CVF- interstitial collagen fraction; HOP- hydroxyproline; * P<0.05 vs CONT; # P<0.05 vs NT; §P<0.05 vs LIS; ANOVA test followed by the Tukey test for comparison between the groups.

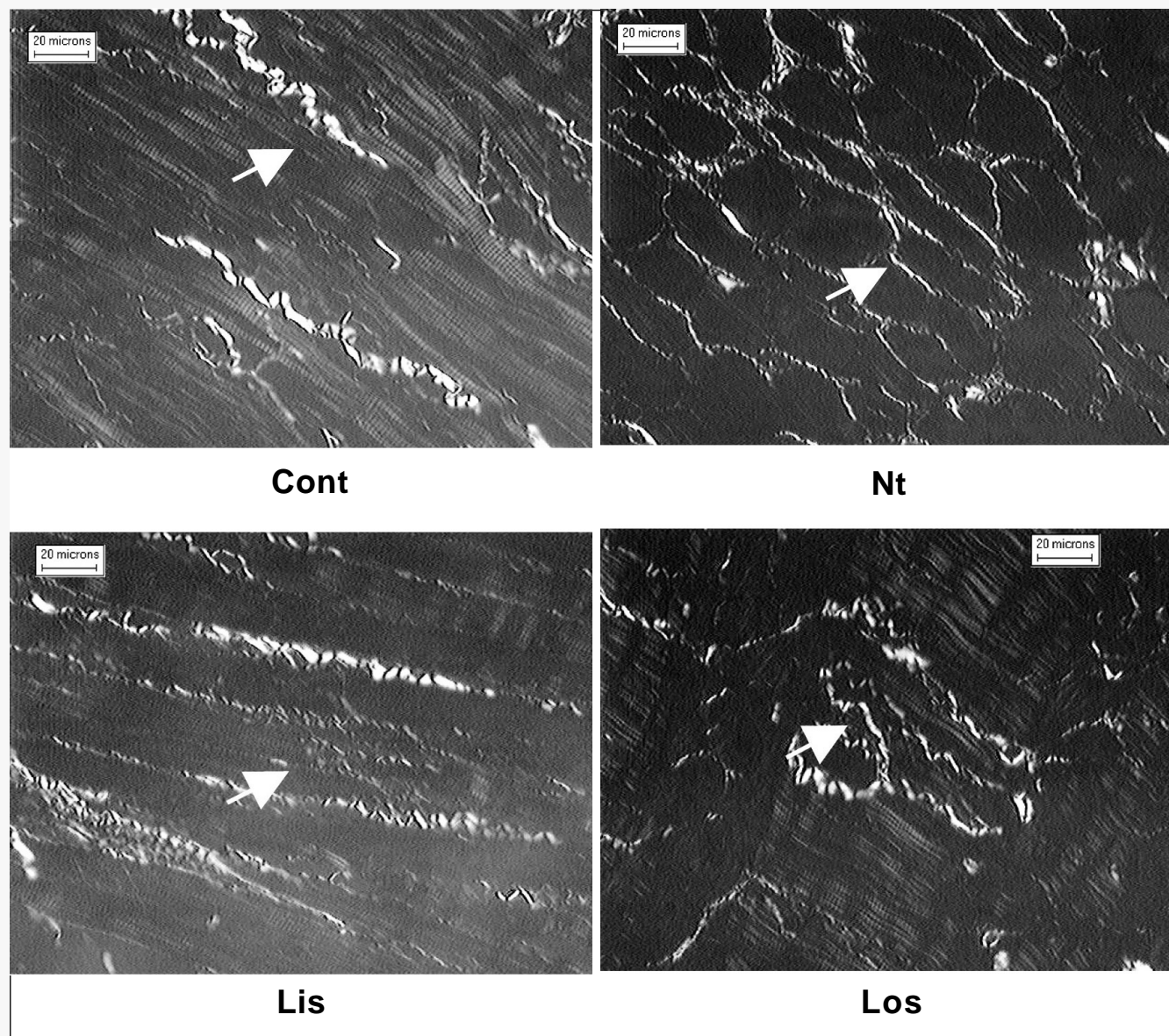


Fig. 1 - Microphotograph of histological sections of rat myocardium (LV) stained with picrosirius red and analyzed under polarized light. The collagen fibers are shown in bright yellow (arrow) and the muscular fibers in brown.

the tissular response in the infarcted area is different from that in the noninfarcted area for the mechanical and neurohormone stimuli, and whether the remodeling response depends on the type of treatment.

Acknowledgments

We thank Elenize Jamas Pereira, Jose Carlos Georgette, Vitor M. Souza, and Rogerio A. Monteiro for technical support, and FAPESP (n1 00/13798 process) for financial support.

References

1. Sutton MGS, Sharpe N. Left ventricular remodeling after myocardial infarction - Pathophysiology and therapy. *Circulation* 2000; 101: 2981-8.
2. Dahlöf B. Effect of Angiotensin-II Blockade On Cardiac-Hypertrophy and Remodeling - a Review. *J Hum Hypertens* 1995; 9: S37-S44.
3. Frimm CD, Sun Y, Weber KT. Angiotensin II receptor blockade and myocardial fibrosis of the infarcted rat heart. *J Lab Clin Med* 1997; 129: 439-46.
4. Mill JG, Milanez MD, de Resende MM, Gomes MDS, Leite CM. Spironolactone prevents cardiac collagen proliferation after myocardial infarction in rats. *Clin Exp Pharmacol Physiol* 2003; 30: 739-44.
5. Brilla CG, Matsubara L, Weber KT. Advanced hypertensive heart disease in spontaneously hypertensive rats - Lisinopril-mediated regression of myocardial fibrosis. *Hypertension* 1996; 28: 269-75.
6. Hansson L, Lindholm LH, Ekbom T et al. Randomised trial of old and new antihypertensive drugs in elderly patients: cardiovascular mortality and morbidity the Swedish Trial in Old Patients with Hypertension-2 study. *Lancet* 1999; 354: 1751-6.
7. Zornoff LAM, Matsubara BB, Matsubara LS, Paiva SAR, Spadaro J. Early rather than delayed administration of lisinopril protects the heart after myocardial infarction in rats. *Basic Res Cardiol* 2000; 95: 208-14.
8. White CM. Angiotensin-converting-enzyme inhibition in heart failure or after myocardial infarction. *Am J Health-Syst Pharm* 2000; 57: S18-S25.
9. Kots YI, Lebedyantsev LV, Saifutdinov RI, Bobylev VV. The use of angiotensin II receptor blockers for the treatment of left ventricular failure in acute period of myocardial infarction. *Kardiologiya* 2001; 41: 30-3.



10. Sharma D, Buyse M, Pitt B, Rucinska EJ. Meta-analysis of observed mortality data from all-controlled, double-blind, multiple-dose studies of losartan in heart failure. *Am J Cardiol* 2000; 85:187-92.
11. Matsubara LS, Matsubara BB, Okoshi MP, Cicogna AC, Janicki JS. Alterations in myocardial collagen content affect rat papillary muscle function. *Am J Physiol-Heart Circul Physiol* 2000; 279: H1534-H1539.
12. Bolognese L, Cerisano G. Early predictors of left ventricular remodeling after acute myocardial infarction. *Am Heart J* 1999; 138: S79-S83.
13. Sadoshima J, Izumo S. Mechanotransduction in Stretch-Induced Hypertrophy of Cardiac Myocytes. *J Recept Res* 1993; 13: 777-94.
14. Suzuki Y, Ruiz-Ortega M, Lorenzo O, Ruperez M, Esteban V, Egido J. Inflammation and angiotensin II. *International Journal of Biochemistry & Cell Biology* 2003; 35: 881-900.
15. Anversa P, Leri A, Li B, Liu Y, Di Somma S, Kajstura J. Ischemic cardiomyopathy and the cellular renin-angiotensin system. *J Heart Lung Transplant* 2000; 19: S1-S11.
16. Unger T, Chung O, Csikos T et al. Angiotensin receptors. *J Hypertens* 1996; 14: S95-S103.
17. Lorell BH. Role of angiotensin AT(1) and AT(2) receptors in cardiac hypertrophy and disease. *Am J Cardiol* 1999; 83: 48H-52H.
18. Mulder P, Devaux B, Richard V et al. Early versus delayed angiotensin-converting enzyme inhibition in experimental chronic heart failure - Effects on survival, hemodynamics, and cardiovascular remodeling. *Circulation* 1997; 95: 1314-9.
19. Ambrose J, Pribnow DG, Giraud FD, Perkins KD, Muldoon L, Greenberg BH. Angiotensin type 1 receptor antagonism with irbesartan inhibits ventricular hypertrophy and improves diastolic function in the remodeling post-myocardial infarction ventricle. *J Cardiovasc Pharmacol* 1999; 33: 433-9.
20. Thai HM, Van HT, Gaballa MA, Goldman S, Raya TE. Effects of AT₁ receptor blockade after myocardial infarct on myocardial fibrosis, stiffness, and contractility. *Am J Physiol-Heart Circul Physiol* 1999; 45: H873-H880.
21. Richer C, Gervais M, Fornes P, Giudicelli JF. Combined selective angiotensin II AT(1)-receptor blockade and angiotensin I-converting enzyme inhibition on coronary flow reserve in postischemic heart failure in rats. *J Cardiovasc Pharmacol* 1999; 34: 772-81.
22. Cavasin MA, Yang XP, Liu YH et al. Effects of ACE inhibitor, AT(1) antagonist, and combined treatment in mice with heart failure. *J Cardiovasc Pharmacol* 2000; 36: 472-80.
23. Whittaker P, Kloner RA, Boughner DR, Pickering JG. Quantitative Assessment of Myocardial Collagen With Picrosirius Red Staining and Circularly-Polarized Light. *Basic Res Cardiol* 1994; 89: 397-410.