

Intramural Haematoma of the Descending Aorta

Bruno Botelho Pinheiro, Walter Vosgrau Fagundes, Rafael Haddad, Maria Cardoso Ramos
Goiânia, GO - Brazil

A 58-year-old female patient, who had reported great abdominal pain in the epigastric and umbilical areas for 3 years followed by an episode of syncope, having been admitted to another health service with probable diagnosis of acute pancreatitis, not confirmed by supplementary exams, was discharged from hospital after 5 days of analgesic use. One year ago, there was abdominal pain relapse, accompanied by faint and sudoresis, and in the last six months the patient has reported precordial, left thoracic paravertebral and abdominal pain, unrelated to effort and of moderate intensity. She denied any history of high blood pressure, alcoholism, smoking, diabetes mellitus, dyslipidaemia, infectious diseases or trauma. She was not in use of medication.

At physical examination, she was in good state, with rosy cheeks, hydrated, without any sign of vestibular disorder, normorhythmic and normophonetic cardiac sounds, without cardiac murmurs, blood pressure = 130/30 mmHg, heart rate = 88 bpm, symmetrical peripheral pulse, absence of oedema in lower limbs and jugular turgescence, physiological vesicular murmur, RF = 13 ipm, flaccid abdomen, which was slightly sore to deep palpation, without visceromegaly.

The electrocardiogram displayed sinus rhythm, QRS-axis = 50°, without any sign of myocardial ischaemia or atrial and ventricular load. The chest X-ray revealed normal cardiac area, pleuropulmonary fields without abnormalities and a slightly increased diameter of the descending aorta. A spiral computed angiotomography of thorax and abdomen exhibited an extensive intramural haematoma of the descending aorta, starting near the origin of the left subclavian artery and extending to the bifurcation of the abdominal aorta (fig. 1). The thickness of the descending aorta wall at T-6 level was 8mm. Atenolol was then prescribed, 50mg/day, and the protocol of periodic clinical (every month) and angiotomographic (every three months) reassessment was introduced.

The aortic intramural haematoma was described in 1920 as "dissection without intimal rupture" and regarded as a distinct pathological entity during necropsy¹. With the arise of modern imaging methods, its diagnosis *in vivo* became possible². Nowadays, the aortic intramural haematoma is considered a precursor of the acute aortic dissections, originating from ruptured vasa vasorum in medial wall layers; it occasionally causes a secondary intimal tear and communication with the aortic lumen. Similarly

to the classic dissections, it may extend along the aorta, progress, regress, or reabsorb³.

The initial clinical presentation is not usually different from that of classic aortic dissections. The anterior or posterior chest pain, in a patient with coexisting history of hypertension, is the most common finding. Abnormalities of either the diameter or contour of the thoracic aorta on chest X-rays are present in approximately 90% of the patients⁴.

Ruling out intimal rupture or dissection lamina is a prerequisite for the diagnosis of intramural haematoma by an imaging method. The localized thickening of the aortic wall > 7mm, circumferential or crescent shaped, and/or evidence of blood accumulation in the media layer is a diagnosis criterion for the aortic intramural haematoma^{5,6}. At computed tomography, the recent haematoma is characterized by a higher density area, in comparison to neighbouring layers of the aortic wall; conversely, the partial or total thrombosis is observed as multiple layers of increasing density⁷. The diagnostic sensitivity between computed tomography, magnetic resonance imaging and the transesophageal echocardiography does not seem to be much different. The choice of one specific imaging method depends on some variables, including the clinical condition of the patient, the doctor's preference and the method's availability⁸.

In the reported case, the high density 8mm thickening of the aortic wall suggests recent intramural haematoma. Therefore, we believe that the event started in the last 6 months, coinciding with the clinical presentation of persistent thoracic and abdominal pain.

The intramural haematoma is more frequent in elderly and hypertensive patients, where aortic wall thickening secondary to atherosclerotic disease and aneurysmatic dilatation with mural thrombus are common, which might be a diagnostic challenge. The identification of the intimal layer and the careful observation of the internal surface of the thickened aortic wall are essential for the differential diagnosis⁹.

The intramural haematoma is thought to lead to acute dissection in 28% to 47% of the patients. Spontaneous regression is seen in 10% of the patients³. Nienaber and cols². demonstrated that the hospital mortality rate, for the patients who presented ascending aortic involvement, was 80% in the group clinically treated and 0% in the group submitted to surgery. The ones with descending aortic involvement did not show significant difference of mortality rate between the groups treated clinically and surgically.

The Stanford Classification of acute aortic dissections also seems acceptable for intramural haematomas. Patients with type A intramural haematoma (involvement of the ascending aorta), reporting persistent or recurrent chest pain should be treated surgically, with replacement of the afflicted region to prevent rupture,

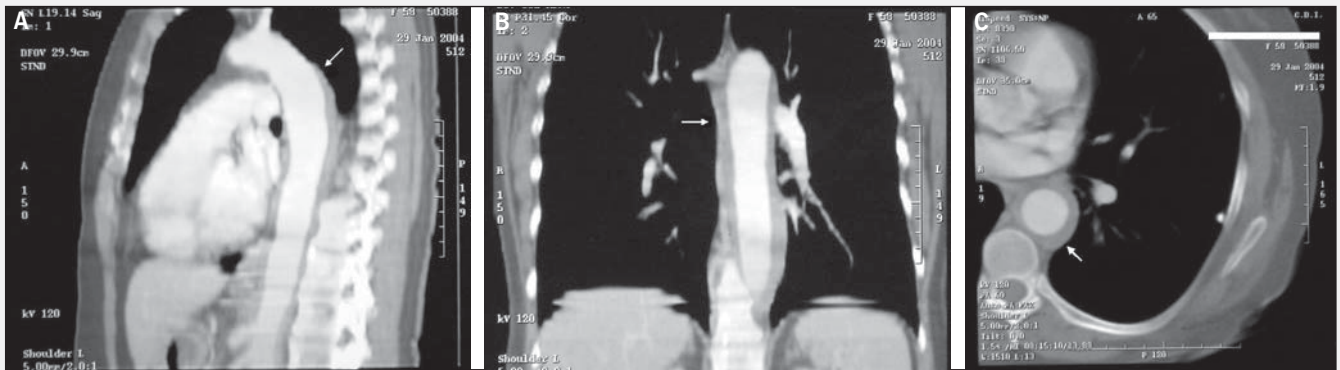


Fig. 1 - Thoracic computed angiography: A) sagittal plane; intramural haematoma of the descending aorta starting near the origin of the left subclavian artery (arrow); B) coronal plane; extension of the intramural haematoma all along the descending thoracic aorta (arrow); C) transverse plane; high density thickening of the aortic wall, suggesting recent intramural haematoma (arrow).

tamponade or compression of coronary ostia². Patients with type B intramural haematoma (involvement of the descending aorta) are medically treated and, if necessary, submitted to stent-graft

placement⁹. In clinical practice, studies with repeated imaging methods are necessary in order to assess the progression or regression of the aortic intramural haematoma.

References

1. Krukenberg E. Beiträge zur Frage des Aneurysma dissecans. Beitr Pathol Anat Allg Pathol 1920; 67: 329-51.
2. Nienaber CA, von Kodolitsch Y, Petersen B, et al. Intramural hemorrhage of the thoracic aorta. Diagnostic and therapeutic implications. Circulation 1995; 92: 1465-72.
3. Nienaber CA, Eagle KA. Aortic dissection: new frontiers in diagnosis and management: Part I: from etiology to diagnostic strategies. Circulation 2003; 108: 628-35.
4. O'Gara PT, De Sanctis RW. Acute aortic dissection and its variants. Toward a common diagnostic and therapeutic approach. Circulation 1995; 92: 1376-8.
5. Yamada T, Tada S, Harada J. Aortic dissection without intimal rupture: diagnosis with MR imaging and CT. Radiology 1988; 168: 347-52.
6. Stanson AW, Welch TJ, Ehman RL, Sheedy PF II. A variant of aortic dissection: computer tomography and magnetic resonance findings. Cardiovasc Imaging 1989; 1: 55-9.
7. Wolverson MK, Crepps LF, Sundaram M, Heiberg E, Vas GW, Shields JB. Hyperdensity of recent hemorrhage at body computed tomography: incidence and morphologic variation. Radiology 1983; 148: 779-84.
8. Song JK. Diagnosis of aortic intramural haematoma. Heart 2004; 90: 368-71.
9. Nesser HJ, Eggebrecht H, Baumgart D, et al. Emergency stent-graft placement for impending rupture of the descending thoracic aorta. J Endovasc Ther 2002; 9 (suppl 2): I172-8.