

Surgical Treatment of the Ascending Aorta Aneurysm. Simultaneous Echocardiographic Observation of Coronary Ostia Reimplanted to Vascular Prosthesis

Marcelo Luiz Campos Vieira, Anderson Benício, Wilson Mathias Jr., Noedir A. Stolf

Instituto do Coração do Hospital das Clínicas – FMUSP - São Paulo, SP - Brazil

A 52-year-old man was admitted for surgical treatment of the ascending aorta aneurysm and aortic valve regurgitation. Upon presentation, he was found to have third heart sound (S3), 6/6+ diastolic murmur at the aortic area, and blood pressure of 3160 x 50 mm Hg. Multiplane transesophageal echocardiography (TEE) showed aneurysm of the ascending aorta measuring 7.3 cm (Figure 1), left ventricular diastolic diameter of 8.3 cm, left ventricular ejection fraction of 0.40 (Simpson's method), and severe aortic valve regurgitation. Echocardiographic findings were confirmed by chest tomography

The patient underwent a Dacron (Figure 2) aortic prosthesis implantation and aortic valve replacement using a Saint-Jude

mechanical prosthesis N^o 27. Coronary ostia were reimplanted to the vascular prosthesis (Figure 3). Right coronary ostium was reimplanted above its anatomic position. Both reimplanted coronary ostia were simultaneously shown during intraoperative transesophageal echocardiogram. Blood flow at the left main coronary artery reimplanted to the vascular prosthesis is shown in figures 4 and 5. The patient evolved uneventfully in the postoperative period and was discharged ten days after surgical correction.

Potential Conflict of Interest

No potential conflict of interest relevant to this article was reported.

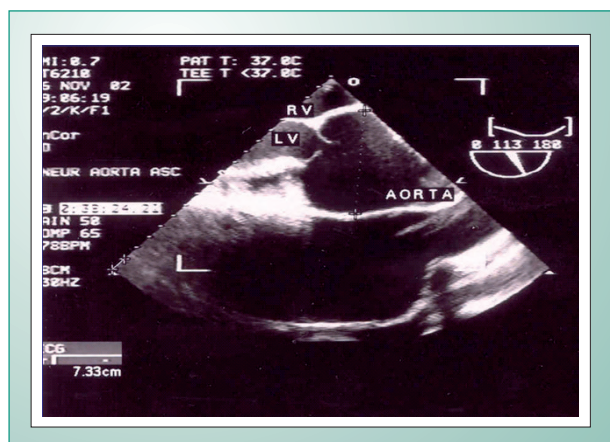


Fig. 1 - Transesophageal echocardiogram showing aneurysm of the ascending aorta (7.3 cm). Left atrium (LA); Left ventricle (LV).

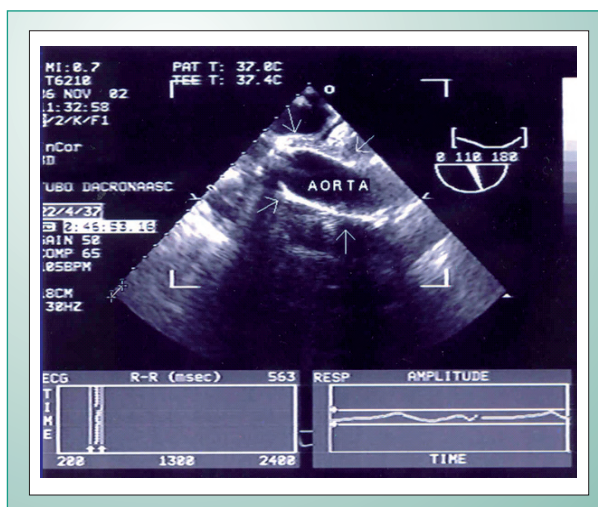


Fig. 2 - Intraoperative transesophageal echocardiogram after implantation of a Dacron vascular prosthesis in the ascending aorta (arrows).

Key words

Aorta, aneurysm, surgery, echocardiophy.

Mailing Address: Marcelo Luiz Campos Vieira •

Rua Cardoso de Melo, 463/21 - 04548-002 – São Paulo, SP - Brazil

E-mail: mlcvieira@aol.com

Received on 7/18/05 • Accepted on 7/25/05

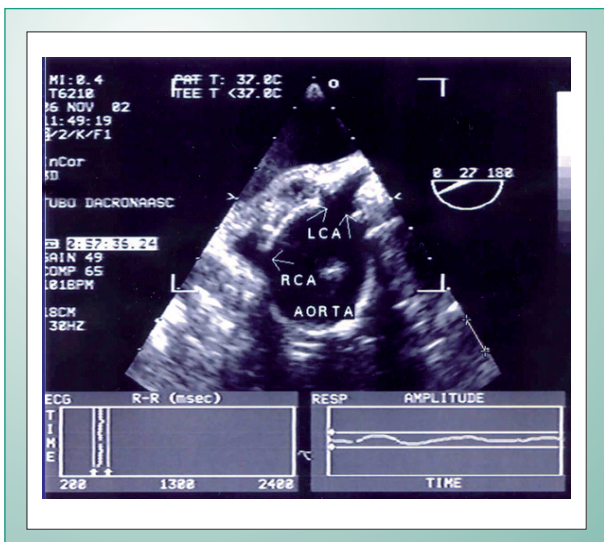


Fig. 3 - Intraoperative transesophageal echocardiogram showing coronary ostia reimplanted to the Dacron vascular prosthesis. Left main coronary artery (LCA); Right coronary artery (RCA) (arrow).

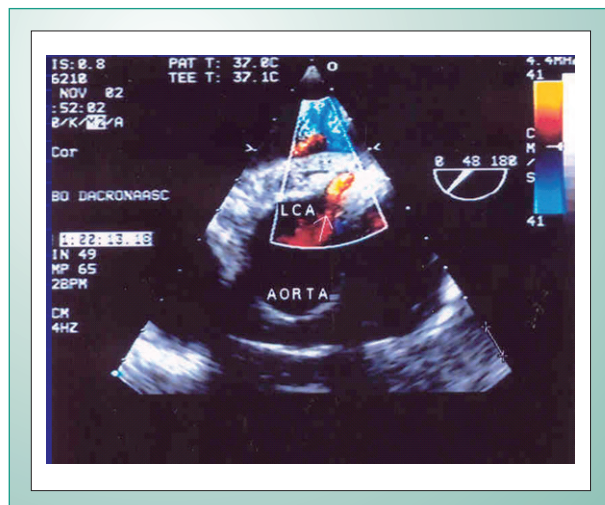


Fig. 4 - Intraoperative transesophageal echocardiogram showing blood flow in the left main coronary artery reimplanted to the vascular prosthesis (color flow mapping) (arrow).

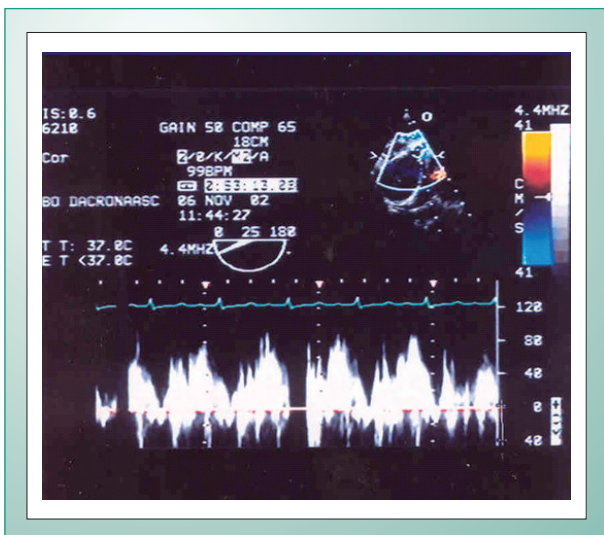


Fig. 5 - Intraoperative transesophageal echocardiogram showing blood flow in the left main coronary artery reimplanted in the vascular prosthesis (pulsed Doppler).