

## In-hospital and Late Outcomes After Coronary Stenting in Patient with Unstable Angina and Myelodysplastic Syndrome

Wercules Oliveira, George César Ximenes Meireles, Allan Longhi, Pedro Beltrão, João Pimenta

Hospital do Servidor Público Estadual de São Paulo, São Paulo, SP, Brazil

Sixty-one-year-old male patient with diagnosis of myelodysplastic syndrome and unstable angina was submitted to coronary angiography and implant of stent. His Blood velle count revealed 40,000 platelets/mm<sup>3</sup>. Coronary angiography with previous platelet transfusion showed obstruction of 80% of the right coronary artery (RCA). Following the administration of clopidogrel, the patient was submitted to another platelet transfusion and stent implantation in the RCA lesion. No bleeding was observed after the introducers removal. After 6 months, treadmill teste was positive and new coronary anigraphy, in the same conditions, showed in-stent restenosis. This case report suggests that coronary stent implantation in patients with thrombocytopenia is a safe procedure, provided that prophylactic platelet transfusion is performed, although late restenosis may occur.

Myelodysplastic syndromes are a heterogeneous cluster of bone marrow disorders characterized by morphological abnormalities of the erythroid, granulocytic, and megakaryocytic series and a hypercellular bone marrow<sup>1</sup>. When the megakaryocytic series is affected, the hemorrhagic tendency is a major aggravating factor. The association of coronary disease and thrombocytopenia due to myelodysplastic syndrome presents a challenge to interventional cardiology, because percutaneous coronary interventions require preventing both intracoronary thrombosis with antiplatelet agents and bleeding after the procedure.

### Case Report

A sixty-one-year-old retired man was admitted to the hospital with a history of pressure-like precordial pain for eight months. First brought on by heavy exertion, one month before admission it started being triggered by mild exertion also. The patient's only risk factor for coronary disease was systemic arterial hypertension. He was taking acetylsalicylic acid (ASA) 200 mg irregularly, propranolol 40 mg every 12 hours and omeprazol 20 mg, folic acid 5 mg, and vitamin B complex daily.

### Key words

Percutaneous transluminal coronary angioplasty, thrombocytopenia, myelodysplastic syndrome.

One year previously, he had developed spontaneous gum bleeding and petechiae. On that occasion, his platelet count was 20,000/mm<sup>3</sup>. Myelogram and bone marrow immunohistochemical studies confirmed the diagnosis of myelodysplastic syndrome involving the granulocytic and megakaryocytic series, with normal erythroid series. The patient was then medicated with folic acid, pyridoxine, and cyanocobalamin. His platelet count remained around 40,000/mm<sup>3</sup>, and no further bleeding events occurred.

Physical examination showed upper limb hypoplasia (phocomelia), blood pressure of 180/110 mmHg, and heart rate of 96 bpm. Cardiopulmonary auscultation was normal. Resting electrocardiogram showed sinus rhythm with nonspecific ventricular repolarization changes in the inferior wall. During precordial pain episodes, ST-segment depression and T-wave inversion (plus-minus) were observed in the same region. Chest radiography revealed cardiothoracic index of 0.5 and normal pleuropulmonary fields. Transthoracic echocardiogram (TTE) showed moderate left ventricular dysfunction due to hypokinesia of inferior, lateral, and posterior walls, with ejection fraction of 0.40. Results of laboratory tests were as follows: platelet count of 40,000/mm<sup>3</sup>, leukocyte count of 1,850/mm<sup>3</sup>, and hemoglobin level of 13.2 g/dl. Clotting profile was within normal limits, with INR (international normalized ratio) 1.09 (normal range 0.90 to 1.26), and activated partial thromboplastin time (aPTT) of 28 seconds (normal range 25 to 45 seconds). Serological tests for B and C hepatitis, HIV, HTLV, CMV, and VDRL were all negative.

The patient underwent coronary angiography two hours after receiving 10 units of platelets. The right femoral artery (RFA) approach was used, according to Judkin's technique, using 6F introducer and catheters. The introducer was removed from the RFA immediately after the procedure, and local compression was applied during 20 minutes. Neither bleeding nor hematoma occurred after compression. The examination showed 80% stenosis in the right coronary artery (RCA) ostium, the reference diameter of which was 3.05 mm (Fig. 1) and 30% stenosis in the anterior descending artery.

Mailing Address: George César Ximenes Meireles •

Rua Sena Madureira, 1265/102 - 04021-051 - São Paulo, SP, Brazil

E-mail: gcxm@cardiol.br, george@tre-sp.gov.br

Manuscript received December 7, 2004; revised manuscript received June 24, 2004; accepted February 24, 2006.

## Case Report

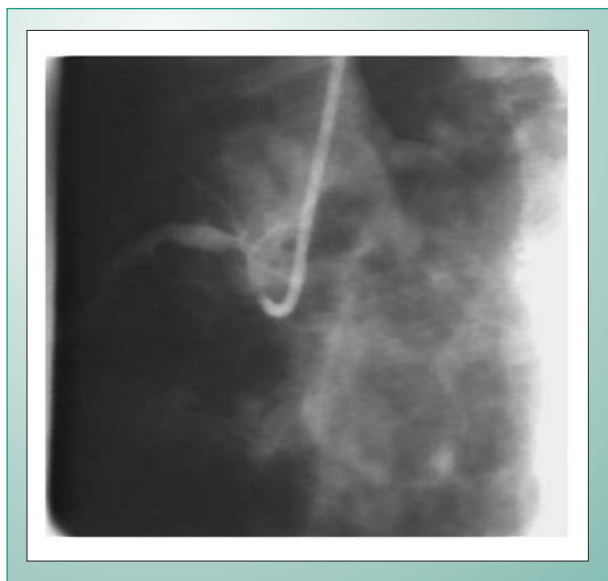

Fig. 1 - Stenotic lesion in the RCA ostium.

Six days after a daily regimen of clopidogrel 75 mg and two hours after another 10-unit platelet transfusion, a 3.0 x 10 mm LEKTON stent was successfully implanted in the RCA ostium, with its proximal end about 1 mm within the aorta (Figs. 2 and 3). The left femoral artery (LFA) approach was used, with a 6F introducer and JR 3.5 guide catheter. During the examination, the patient received 20 mg of intracoronary isosorbide mononitrate and 6,000 IU (100 IU/kg) of intravenous heparin. Stent deployment pressure was 14 atm, and postdilation was performed using the same balloon catheter at 18 atm. Blood cell count and clotting profile at the day of the procedure showed platelet count of 40,000/mm<sup>3</sup>, leukocyte count of 1,620/mm<sup>3</sup>, aPTT of 31 seconds, and INR of 1.03. After the procedure these parameters were platelet count of 71,000/mm<sup>3</sup>, leukocyte count of 2,370/mm<sup>3</sup>, aPTT of 28.9 seconds, and INR of 1.03. **The introducer was removed four hours later, followed by local compression during 30 minutes. Neither bleeding nor hematoma occurred after compression.**

Hospital course was uneventful. Seven days after stent implantation, the patient was discharged on clopidogrel 75 mg daily for another 17 days in order to ensure 30 days of continuous use. Within two weeks of clopidogrel therapy, platelet count remained stable at 40,000/mm<sup>3</sup>.

The patient became asymptomatic and, six months after stent implantation, underwent exercise stress testing, which showed ST-segment depression in the inferior leads. Another catheterization was performed two hours after platelet transfusion (eight units), using the right femoral artery (RFA) approach. A 70% in-stent restenosis was found (Fig. 4). There were no complications deriving from catheterization. Preprocedural platelet count was 20,000/mm<sup>3</sup> and rose to 40,000/mm<sup>3</sup> after transfusion. The patient was taking thalidomide 200 mg, simvastatin 20 mg, and propranolol 40 mg twice daily. In view of his refusal to undergo another percutaneous coronary intervention (PCI), he was kept on clinical treatment with the same medication. Twenty months after stent implantation, the patient remains

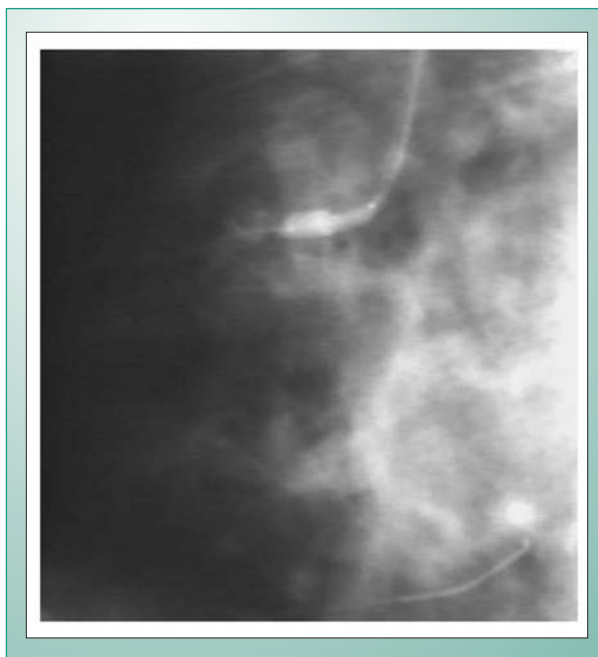


Fig. 2 - Stent placement in the RCA ostium.

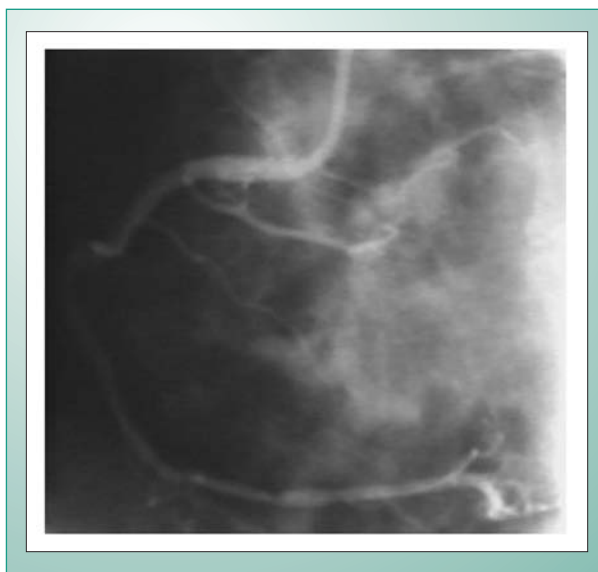


Fig. 3 - Immediate result after stent implantation into the RCA ostium.

asymptomatic and taking the same medication. His last platelet count was 104,000/mm<sup>3</sup>.

## Discussion

The association of thrombocytopenia due to myelodysplastic syndrome and coronary disease is rare, and published data on the management of obstructive lesions through PCI in patients with low platelet count are scarce. The medical literature describes two patients with idiopathic thrombocytopenic purpura (ITP) who underwent percutaneous transluminal coronary angioplasty (PTCA) for acute myocardial infarction<sup>2,3</sup>, one of whom also received stent implantation because of coronary dissection after

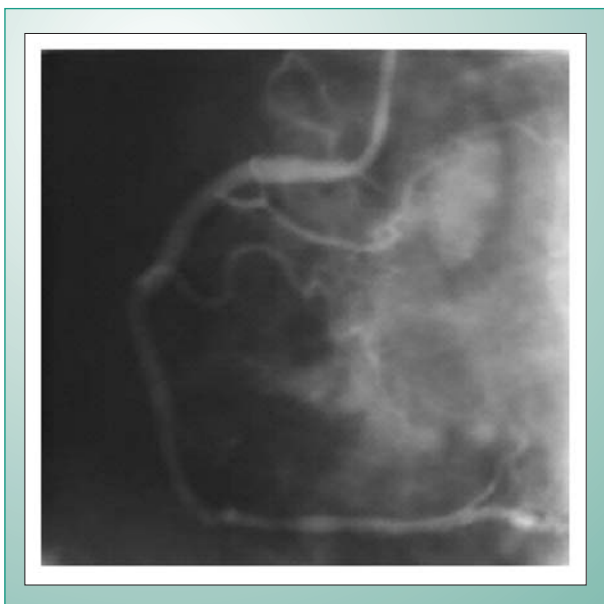


Fig. 4 - Coronary angiography six months after stent implantation.

balloon angioplasty<sup>2</sup>. As these procedures were performed under emergency conditions, no preparations were made, and patients experienced hemorrhagic complications at the puncture site. Recently, the case was reported of a patient with thrombocytopenic purpura and unstable angina who underwent stent implantation in the anterior descending and circumflex arteries via right brachial artery dissection, because platelet count failed to increase after several transfusions<sup>3</sup>. The present study, unlike those previously reported, shows the use of coronary angiography through the femoral artery approach and elective coronary stenting after platelet transfusion in a patient with thrombocytopenia caused by myelodysplastic syndrome.

In addition to the myelodysplastic syndrome, this patient had upper extremity phocomelia, a congenital disorder characterized by bilateral absence of the radius. An association of phocomelia with thrombocytopenia and a decrease in the number of megakaryocytes on the myelogram was described, the TAR syndrome (Thrombocytopenia with Absent Radius), a rare congenital disorder that differs from the myelodysplastic syndrome in that no changes occur in granulocytic and erythroid series<sup>5</sup>. Based on absolute platelet count, thrombocytopenia may be divided into the following categories: mild ( $<150,000/\text{mm}^3$ ), moderate ( $50\text{--}100,000/\text{mm}^3$ ), severe ( $20\text{--}50,000/\text{mm}^3$ ) and profound ( $<20,000/\text{mm}^3$ ). The non-linearity of the bleeding time associated with thrombocytopenia of different etiology and defined value was demonstrated by Harker. This accounts for the differences in absolute platelet count found in medical guides regarding indication for platelet transfusion in patients with thrombocytopenia of different etiologies<sup>6</sup>. According to America's Blood Centers, platelet transfusion should be administered prophylactically to patients with platelet count lower than  $50,000/\text{mm}^3$  and who are undergoing surgery or an invasive procedure in which the operative field can be visualized or external

pressure may be used to maintain hemostasis<sup>7</sup>.

In the present case, platelet count was  $40,000/\text{mm}^3$ , and the patient was given 10 units of platelets two hours before the procedures to increase platelet levels above  $50,000/\text{mm}^3$ . This measure has proved to be safe both for coronary angiography and stent implantation.

The use of heparin at  $100\text{ IU/kg}$  during the procedure has also proved to be safe, since the introducer was removed from the femoral artery four hours postprocedure without bleeding or hematoma formation.

The use of small diameter introducers and catheters is recommended to facilitate postprocedural hemostasis. In the present case a 6F material was employed, because this is the smallest diameter available. The femoral artery was the chosen approach, since it is the technique used by our hemodynamic team. The radial artery is an alternative approach for patients with thrombocytopenia, but it is not routinely used at our institution<sup>8</sup>.

Clinical trials have shown higher restenosis rate in patients with aorto-ostial location after bare-metal stent implantation. In an observational study, drug-eluting stent implantation in patients with aorto-ostial lesions has yielded encouraging results, with 6.3% target-vessel revascularization. In this patient, drug-eluting stent was not used for economic reasons.

Atherosclerotic plaque fissuring or rupture is the most important pathophysiological mechanism of unstable angina. Platelet adhesion and aggregation and thrombus formation following plaque rupture, as well as hemorrhage and edema within the plaque, further aggravates stenosis<sup>10</sup>. In spite of the thrombocytopenia, this patient evolved with progressively unstable angina, suggesting that regardless of the small number of platelets, platelet function remained normal, thereby justifying the use of antiplatelet agents to prevent acute or subacute post-stent thrombosis. Among antiplatelet agents, clopidogrel alone was the treatment of choice, because this drug is better tolerated than ticlopidine. In addition, the combination of clopidogrel and aspirin is associated to higher risk of gastrointestinal bleeding in patients with thrombocytopenia and past history of gastritis, spontaneous gum bleeding, and petechiae<sup>11</sup>.

Thrombocytopenia, kept at around  $20,000/\text{mm}^3$ , failed to protect against restenosis six months after stent implantation. In animal models, intimal hyperplasia inhibition was correlated to the degree of thrombocytopenia. Induced thrombocytopenia at less than  $7,000/\text{mm}^3$  two or three days before balloon injury was necessary to inhibit neointimal formation in animals. Induced thrombocytopenia to prevent restenosis is clinically impracticable, and there are few data in the medical literature regarding clinical course after percutaneous coronary intervention in patients with low platelet count. Clinical trials have failed to demonstrate any beneficial effect of antiplatelet drugs in restenosis following angioplasty, although acute complications were reduced<sup>12</sup>.

This case report suggests that both angiography and percutaneous coronary intervention in patients with thrombocytopenia are safe procedures, provided that prophylactic platelet transfusion is performed two hours before; in the long term, however, restenosis may occur.

### References

1. Heaney ML, Golde DW. Myelodysplasia. *N Engl J Med*. 1999;340:1649-60.
2. Fuchi T, Kondo T, Sase K, Takahashi M. Primary percutaneous transluminal coronary angioplasty performed for acute myocardial infarction in a patient with idiopathic thrombocytopenic purpura. *Jpn Circ*. 1999;63:133-6.
3. Kikuchi S, Hayashi Y, Fujioka S, Kukita H, Ochi N. A case of intracoronary stent implanted for acute myocardial infarction in an elderly patient with idiopathic thrombocytopenic purpura. *Nippon Ronen Igakkai Zasshi*. 2002;39(1):88-93.
4. Marques GM, Furakawa MK, Leitão TP, Quinones JLA, et al. Angioplastia Transluminal Coronária em Portador de Púrpura Trombocitopênica Idiopáticas. *Arq Bras Cardiol*. 2005;84:337-9.
5. Azcorra MU, Lozano PA. Síndrome de von Voss-Cherstvoy (DK-Focomelia): Primera descripción en España y revisión de la literatura. *An Esp Pediatr*. 1997;46:299-302.
6. Lewis B. Thrombocytopenia and Outcome in Invasive Cardiology. *J Invas Cardiol*. 2002, Supp 2002B:38-47B.
7. America's Blood Centers. Indications for platelet transfusion therapy. *ABC Blood Bulletin*. 1999; 2(2).
8. Caputo RP, Abraham S, Churchill D. Transradial coronary stent placement in a patient with severe idiopathic autoimmune thrombocytopenic purpura. *J Invasive Cardiol*. 2000; 12(7):365-8.
9. Iakovou I, Michev I, Sangiorgi GM, et al. Clinical and angiographic Outcome After Sirolimus-Eluting Stent Implantation in Aorto-Ostial Lesions. *J Am Coll Cardiol*. 2004; 44:967-71.
10. Falk E. Coronary thrombosis: Pathogenesis and clinical manifestations. *Am J Cardiol*. 1991;68:28B-35B.
11. Bertrand ME, Rupprecht H-J, Urban P, for the CLASSICS Investigators. Double-blind study of the safety of clopidogrel with and without a loading dose in combination with aspirin compared with ticlopidine in combination with aspirin after coronary stenting. The clopidogrel Aspirin Stent International Cooperative Study (CLASSICS). *Circulation*. 2000;102:624.
12. Breton LH, Plow EF, Topol EJ. Role of platelets in Restenosis After Percutaneous Coronary Revascularization. *J Am Coll Cardiol*. 1996;28:1643-51.