

Anomalous origin of the right coronary artery: diagnosis and treatment

Antonio Carvalho Leme Neto, Roberto Gomes de Carvalho, Remulo José Rauen Junior, Gilberto Melnick, Gustavo Carvalho, Janaine Marchiori

Hospital Santa Cruz, Curitiba, PR - Brazil

We report the case of a rare anomaly of the right coronary artery (RCA) arising from the left aortic sinus, having a single ostium with the left coronary artery, associated with documented episodes of inferior ischemia,

in which surgical treatment with a right internal thoracic artery to RCA bypass graft and the corresponding ligation provided greater stability to the coronary blood flow and good clinical progress.

Introduction

The origin of the coronary artery from the wrong aortic sinus is a rare cause of a congenital anomaly that may potentially lead to sudden cardiac death¹. The most common of these conditions is the anomalous origin of the LCA from the pulmonary artery².

We describe the case of a rare anomaly of the right coronary artery (RCA) originating from the left aortic sinus, with a single LCA and RCA ostium. The patient had experienced episodes of myocardial ischemia, underwent myocardial revascularization surgery and showed good clinical progress.

Case report

O. T., a 58-year-old white male patient presented at the Thoracic Pain Unit (TPU) with a complaint of severe oppressive precordial pain radiating to the cervical area. The pain occurred while the patient was resting, lasted 30 minutes and was alleviated by sublingual nitrate.

The patient had a history of systemic arterial blood pressure, dyslipidemia, and eight months before being admitted to the hospital, he had been seen at the mobile emergency unit for ventricular tachycardia and hemodynamic instability, and had undergone electrical cardioversion. At that time, the coronary angiography showed an anomalous origin of the right coronary artery arising from a single coronary ostium in the left aortic sinus, and the decision was made to treat the patient conservatively with an oral calcium channel antagonist and nitrate.

On physical examination, the patient was anxious, eupneic, afebrile; systemic arterial blood pressure (BP) was 112/82

mmHg and the heart rate (HR) was 72 bpm. On cardiovascular evaluation, heart sounds were normal and rhythmic, with the presence of an audible fourth heart sound and no murmurs. All other physical examination findings were normal.

The electrocardiogram (ECG) showed ventricular repolarization alteration in the inferior wall.

After being monitored for nine hours at the thoracic pain unit by means of ECG, heart enzymes (serial creatine phosphokinase, creatine phosphokinase MB fraction activity and troponin I), and an echocardiogram with no alterations, the patient underwent myocardial scintigraphy which showed signs of ischemia in the inferior wall, accompanied by clinical symptoms (angina), and electrocardiographic abnormalities reverted with the administration of sublingual nitrate.

Coronary angiogram documented the anomalous origin of the RCA arising from the left sinus of Valsava at an acute angle and coursing between the aorta and the pulmonary trunk.

Based on clinical findings and ancillary tests that showed ischemia in an area irrigated by anomalous coronary circulation, the decision was made to perform surgical revascularization with a right internal thoracic artery grafting to the RCA and its ligation.

The patient progressed with no postoperative complications, and showed good clinical progress with complete remission of the thoracic pain during follow-up.

Discussion

Coronary artery anomalies result from disorders that take place during the third week of fetal development. The heart muscle originates entirely from the splanchnic mesoderm which forms the base of the pericardial cavity, known as cardiogenic area, and which gives rise to a pair of endocardial tubes that unite to form the primitive heart tube³. Coronary anomalies result from several anatomic aspects according to their origin, course and distribution.

The anomalous origin of the coronary artery from the opposing aortic sinus is rare, with an incidence estimated to range from 0.05% to 0.1% for the right coronary arising from the left aortic sinus⁴.

Key Words

Coronary vessel anomalies; myocardial ischemia; myocardial revascularization.

Mailing address: Antonio Carvalho Leme Neto •

Rua Walenty Golas 371/202 C - Campo Comprido - 81200-520 - Curitiba, PR - Brazil

E-mail: antonioleme@cardiol.br

Article received on March 4, 2007; received revised on April 2, 2007; accepted on May 21, 2007.

Coronary anomalies are classified as significant or major, which are those that cause myocardial perfusion disorders, and non-significant or minor, which are those in which the coronary flow is normal. Significant anomalies have a low incidence and account for 0.25%-0.9% of congenital heart diseases⁵⁻⁶. For this reason, alterations in the coronary flow caused by these anomalies and their clinical significance remain unknown⁵⁻⁶. Despite their low incidence, there is a high risk of sudden death, usually due to myocardial ischemia in cumulative episodes which, over time, result in sparse fibroses of the myocardium and predispose to lethal ventricular arrhythmias by creating an electrically unstable myocardial substrate. The mechanisms involved are believed to be:

- Origin in an acute angle and folding or occlusion caused by the angulation at the point of coronary artery emergence².
- Coronary spasm resulting from its torsion movement².

- Mechanical compression of the anomalous artery between the pulmonary and aortic trunks during physical exertion; the initial portion of the artery may be intramural (within the aortic tunic media), which may further aggravate the coronary obstruction, especially with the aortic expansion during physical exertion².

Reports of sudden death associated with this anomaly have been described by Isner *et al*⁷ (one case) and Roberts *et al*⁸ (two cases), suggesting that the acute angulation of this artery would lead to the interruption of coronary flow and sudden death.

Clinical presentation is usually nonspecific, with symptoms of syncope and thoracic pain during physical exertion. The diagnosis of these malformations may not be established by abnormalities detected in electrocardiographic or ergometric testing; however, the echocardiogram, nuclear medicine and magnetic resonance may identify or raise suspicion of the existence of these anomalies. Anatomic confirmation

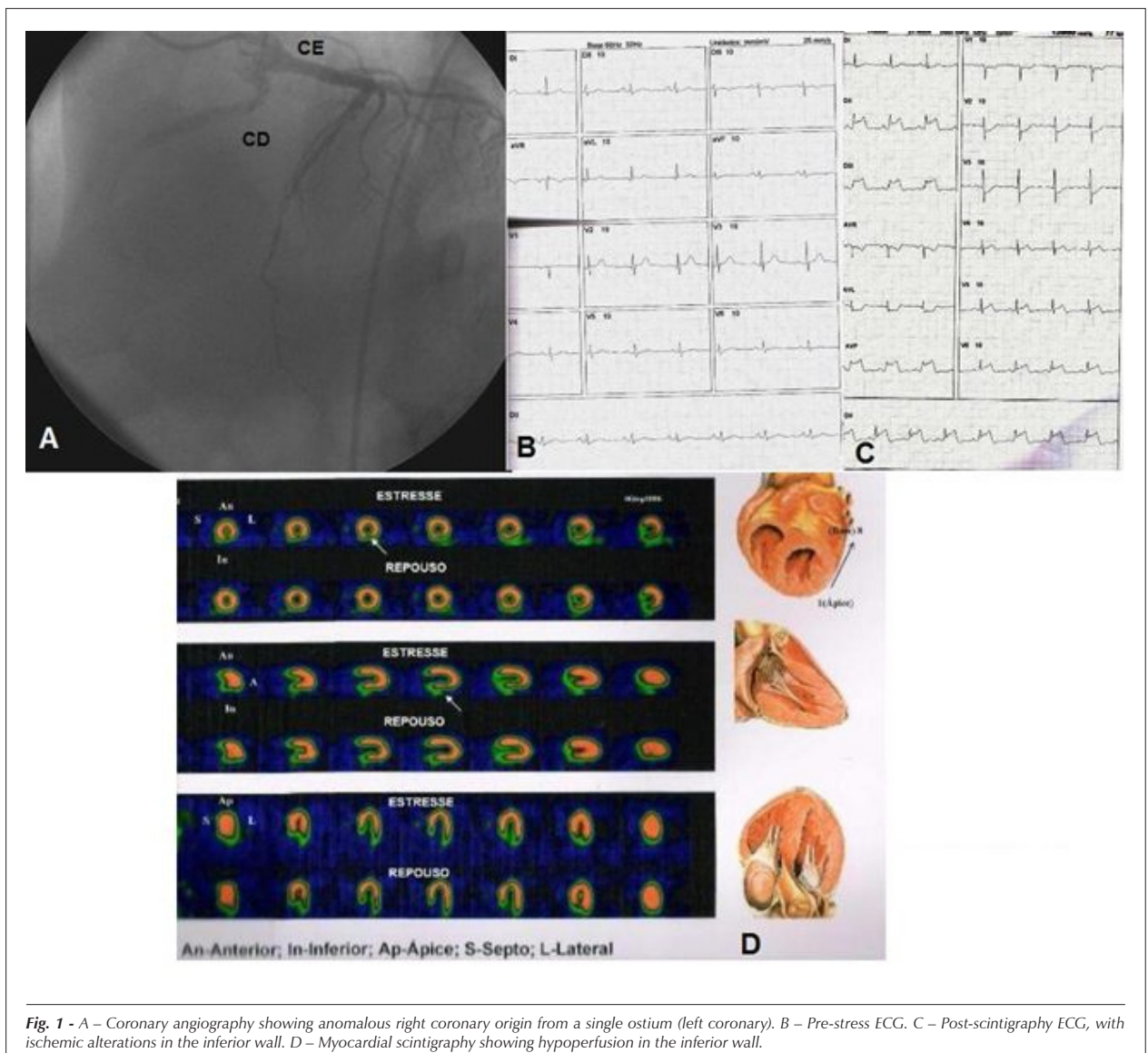


Fig. 1 - A - Coronary angiography showing anomalous right coronary origin from a single ostium (left coronary). B - Pre-stress ECG. C - Post-scintigraphy ECG, with ischemic alterations in the inferior wall. D - Myocardial scintigraphy showing hypoperfusion in the inferior wall.

Case Report

is provided by coronary angiography⁶. Once identified, participation in sports should be prohibited and surgical correction, when feasible, can restore coronary blood flow⁶.

As to the definite treatment of the anomalous coronary artery origin, this should be guided by the anatomy and implantation of the anomalous artery. Treatment may be surgical reconstruction or decompression of its course, coronary reimplantation in the correct coronary sinus, myocardial revascularization and, in some cases, use of endovascular techniques with stent implantation⁹.

In this report, we describe the diagnostic and therapeutic challenge presented by a rare case of right coronary artery anomaly. Despite the initial clinical treatment, the recurrence

of documented ischemic episodes made surgical treatment necessary, using a technique based on the presence of a single ostium for both coronary arteries in the left aortic sinus, which limited its reimplantation. Myocardial revascularization of the RCA was performed with the internal right thoracic artery and corresponding ligation of the RCA, maintaining stable perfusion for the greatest segment of the cardiac muscle at risk.

Previous studies suggest that the surgical ligation of the anomalous coronary artery may be beneficial because it avoids competitive flow from the graft and native coronary artery¹⁰.

In this case, the patient remained stable during follow-up, and the myocardial scintigraphy made at the end of twelve months showed preserved perfusion.

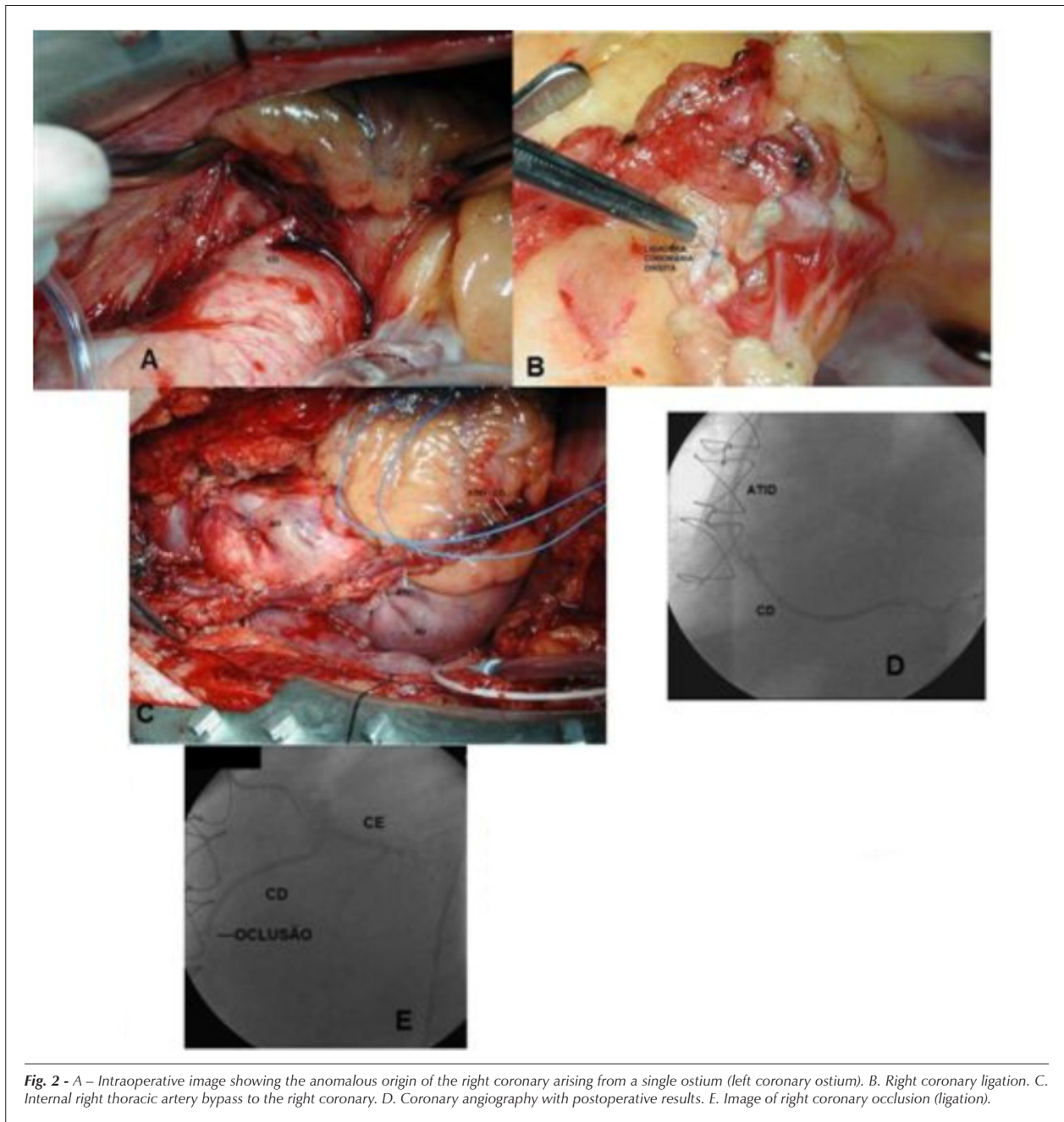


Fig. 2 - A – Intraoperative image showing the anomalous origin of the right coronary arising from a single ostium (left coronary ostium). **B.** Right coronary ligation. **C.** Internal right thoracic artery bypass to the right coronary. **D.** Coronary angiography with postoperative results. **E.** Image of right coronary occlusion (ligation).

Potential Conflict of Interest

No potential conflict of interest relevant to this article was reported.

Sources of Funding

There were no external funding sources for this study.

Study Association

This study is not associated with any graduation program.

References

1. Ogden JA. Congenital anomalies of the coronary arteries. *Am J Cardiol.* 1970; 25: 474-9.
2. Sharbaugh MJAH, White RS. Single coronary artery: analysis of the anatomic variation, clinical importance, and report of five cases. *JAMA.* 1974; 230: 243-6.
3. Fitzgerald MJT. *Embriologia humana.* São Paulo: Harper & Row do Brasil, 1980. p. 48.
4. Alexander RW, Griffith GC. Anomalies of the coronary arteries and their significance. *Circulation.* 1956; 14: 800-5.
5. Lipton MJ, Barry WH, Obrez I, Silverman JF, Wexler L. Isolated single coronary artery: diagnosis, angiographic classification, and clinical significance. *Radiology.* 1979; 130: 39-47.
6. Campos ERS. Anomalias congênitas das artérias coronárias. Incidência e classificação. Estudo angiográfico. [dissertação]. São Paulo: Faculdade de Medicina. Universidade de São Paulo; 1981.
7. Ogden JA. Congenital anomalies of the coronary arteries. *Am J Cardiol.* 1970; 25: 474-9.
8. Isner JM, Shen ME, Martin ET, Fortin RV. Sudden unexpected death as a result of anomalous origin of the right coronary artery from the left sinus of Valsalva. *Am J Med.* 1984; 76: 155-8.
9. Roberts WC, Siegal RJ, Zipes DP. Origin of the right coronary artery from the left sinus of Valsalva and its functional consequences: analysis of 10 necropsy patients. *Am J Cardiol.* 1982; 49: 863-8.
10. Kirklin JW, Barrat-Boyes BG. *Cardiac Surgery.* 3rd. ed. New York: Wiley; 2003.
11. Reul RL, Cooley DA, Hallman GL, Reul GJ. Surgical treatment of coronary artery anomalies. *Tex Heart Inst J.* 2002; 29: 299-307.