

## Desmin-Related Restrictive Cardiomyopathy

Christiano Pereira Silva, Fernando Bacal, Luiz Alberto Benvenuti, Edimar Alcides Bocchi

Instituto do Coração do Hospital das Clínicas da Faculdade de Medicina da Universidade de São Paulo, São Paulo, SP - Brazil

Restrictive cardiomyopathies may have different etiologies, among which we can point out storage diseases by accumulation of different materials such as desmin. Desminopathies are uncommon diseases that progress with conduction abnormalities, peripheral myopathies, and

ventricular dysfunction. The present report describes a patient with complete atrioventricular block as the initial event; he later developed skeletal muscle alterations and heart failure. The investigation led to the diagnosis of restrictive cardiomyopathy due to desmin accumulation.

### Introduction

Cardiomyopathies constitute a group of disorders in which the heart muscle itself is primarily involved. The definition more recently published<sup>1</sup> is that they comprise a heterogeneous group of myocardial diseases associated with electrical or mechanical dysfunction that usually exhibit inappropriate ventricular hypertrophy or even chamber dilatation, generally due to genetic causes. A thorough investigation is usually required to establish the etiology of a cardiomyopathy. It is not unusual to label a not fully investigated disease as idiopathic.

The objective of this report is to discuss restrictive cardiomyopathies, specifically addressing an uncommon etiology – the desmin storage. Restrictive cardiomyopathies are characterized by a reduction in diastolic filling and in ventricular distensibility, which determine a typical hemodynamic pattern. Ejection fraction may be preserved, diastolic volumes are normal or decreased, ventricular thickness is normal or increased and atrial dilatation is almost always present. Dyspnea, edema, palpitation and jugular venous distension are the symptoms most frequently found. The diagnosis may be made using echocardiography, but invariably additional methods such as CT-scan and MRI are necessary to establish a differential diagnosis, especially with constrictive pericarditis<sup>2</sup>.

### Case Report

Male patient, 21 years old, student, single, complained that he had been presenting progressive exertional shortness of breath and nocturnal dyspnea for one year. He denied other associated diseases, except for syncope with permanent pacemaker implantation one year before the onset of

symptoms of heart failure. At that time he was diagnosed with complete atrioventricular block.

The patient was taking carvedilol (12.5 mg/day), digoxin (0.25 mg/day), furosemide (40 mg/day) and spironolactone (25 mg/day). He had a recent echocardiogram showing left ventricular ejection fraction (LVEF) of 55%, left ventricular (LV) diastolic (DD) and systolic (SD) diameter of 52 and 37 mm, respectively, left atrial (LA) diameter of 50 mm, and systolic pulmonary artery pressure (SPAP) of 45 mmHg. On physical examination, he was hemodynamically stable with signs of systemic and pulmonary congestion. His furosemide dose was increased to 60 mg/day and he was advised to follow a strict fluid restriction. A two-month outpatient follow-up visit was scheduled.

For the following two years, the patient progressed with intermittent episodes of decompensation. He sought another medical service when he was in NYHA functional class III. His medical history revealed muscle weakness in proximal lower limbs and neck, as well as dysphagia for two years. On physical examination, he had no respiratory distress at rest, but once more showed signs of congestion. His echocardiogram showed EF = 43%, DD = 56mm, with mild mitral regurgitation. Results of the major laboratory tests were within normal range.

The patient underwent pyrophosphate myocardial scintigraphy, which showed a slightly high uptake of the radionuclide in cardiac and hepatic areas. Peak oxygen consumption on cardiopulmonary exercise test was 19.6 ml/kg/minute. Echocardiogram revealed LA: 50 mm, DD: 59 mm, EF: 35%, SPAP: 51 mmHg, with no dyssynchrony (Table 1). Chest radiograph showed signs of pulmonary congestion, and resting electrocardiogram showed only the pacemaker rhythm. Laboratory tests indicated jaundice due to indirect bilirubin accumulation, AST 50 u/l, ALT 63 u/l, coagulation disorder (INR 1.6; PT 47%) and BNP of 1,028 pg/ml. In light of these results, the possibility of restrictive cardiomyopathy was considered, and a hemodynamic study with endomyocardial biopsy was requested. Figure 1 shows endocardial biopsy fragments on electron microscopy with areas of fibrosis and endocardial thickening with desmin deposits. The hemodynamic data (RV: 57 x 13 x 23.2 mmHg; RA: mean 23 mmHg; Ao: 120 x 82 mmHg; LV: 120 x 23 x 45 mmHg) confirmed the hypothesis of restrictive cardiomyopathy. The carvedilol and furosemide

### Key words

Cardiomyopathy, restrictive; storage disease; desmin.

Mailing address: Christiano Pereira Silva •

Rua Charles Spencer Chaplin, 85/21 - Vila Andrade - 05642-010, São Paulo, SP - Brazil

E-mail: [chrispsilva@cardiol.br](mailto:chrispsilva@cardiol.br)

Manuscript received March 19, 2007; revised manuscript received May 11, 2007; accepted July 26, 2007.

doses were increased, and a genetic screening of the whole family was recommended.

## Discussion

Desmin-related myopathies are diseases with a low prevalence. Desmin is the most important intermediate filament of the skeletal and cardiac muscle. Its function is to keep the structure and functional integrity of myofibrils, thus working as a protein cytoskeleton linking the Z bands to the plasma membrane<sup>3</sup>.

Primary desminopathies are caused by mutations in the desmin gene. The clinical spectrum is quite broad: muscle weakness in the trunk, neck region and even affecting the respiratory muscles may be the initial symptom. Cardiac manifestations may occur in the form of restrictive cardiomyopathy, conduction system abnormalities, arrhythmias and sudden death<sup>4</sup>.

Genetic alterations affecting desmin may also trigger a more common model of cardiomyopathy – the dilated cardiomyopathy. The estimated prevalence of desmin gene mutations in idiopathic dilated cardiomyopathy is between 1% and 2%, and many of them are capable of causing this phenotype<sup>5</sup>.

Desmin cardiomyopathies are diagnosed only with ultrastructural studies, because immunohistochemical findings of sarcoplasmic desmin microfilaments may not be enough to differentiate abnormal patterns found in hypertrophic and dilated cardiomyopathies.

Several mutations have already been identified. Arbustini et al<sup>6</sup> studied four unrelated patients and found three new gene mutations (R16C, T453I and 10 bp), and one known mutation (R406W). In that study, the disease was autosomal dominant in two families, recessive in one, and associated with a de novo mutation in another one. Olivé et al<sup>7</sup> studied ten patients from six unrelated families diagnosed with the disease. The pattern of genetic presentation was variable: autosomal dominant in three families, autosomal recessive in one; there was no family history in two cases. Clinically, desminopathy also had a non-uniform behavior: two patients presented with cardiomyopathy, one patient with respiratory failure, and the remaining patients with lower limb weakness. A total of four patients had cardiac involvement. Serum levels

of CK were slightly abnormal. Muscle biopsies confirmed the diagnoses by showing intracytoplasmic desmin-immunoreactive inclusions<sup>7</sup>.

The major manifestations described in desmin accumulation restrictive cardiomyopathy were found in the present case. Conduction disturbances are determinant for diagnostic suspicion, and in the present case we verified that the first manifestation was precisely complete atrioventricular block. Signs of skeletal muscle involvement are also relevant. The patient discussed presented proximal paresis of the lower limbs and neck region, thus increasing the likelihood of the diagnosis. Initially, the heart failure was predominantly characterized by a diastolic dysfunction, later followed by systolic dysfunction, in addition to a disproportion between oxygen consumption obtained during a cardiopulmonary exercise test and the physical restriction that the patient presented.

When the etiology of the cardiomyopathy was defined, in this case, family investigation became mandatory. History taking did not reveal other family members with heart failure. The clinical management was not modified. There is no specific treatment for desminopathies. The patient will continue to be clinically followed up. The possibility of heart transplantation has not been ruled out as a future alternative.

## Conclusion

The present report shows the importance of attempting to accurately define the etiologic diagnosis of cardiomyopathies. Labeling cardiomyopathies as idiopathic, or classifying them into unspecific categories, frequently on inconsistent grounds, reduces the treatment possibilities, interferes in the definition of prognosis, and does not allow reliable conclusions on statistical data.

Desminopathies are not common diseases, and the diagnosis has little influence on the pharmacological treatment, since there is no specific therapy. The importance of making such a diagnosis lies in the possibility of screening and preventing new cases, in addition to enabling the knowledge on uncommon diseases.

## Potential Conflict of Interest

No potential conflict of interest relevant to this article was reported.

Table 1. Follow-up echocardiographic data

Parameter	1st Initial	2nd (after 2 ys)	3rd (after 3 mo)
LVEF (%)	55	43	35
LVDD (mm)	52	56	59
LVSD (mm)	37	39	44
LA (mm)	50	51	50
PASP (mmHg)	45	49	51
PW (mm)	11	11	12
SEP (mm)	10	11	11

LVEF: left ventricular ejection fraction; LVDD: left ventricular diastolic diameter; LVSD: left ventricular systolic diameter; LA: left atrium; SPAP: systolic pulmonary artery pressure; PW: posterior wall; SEP: septum.

## Case Report

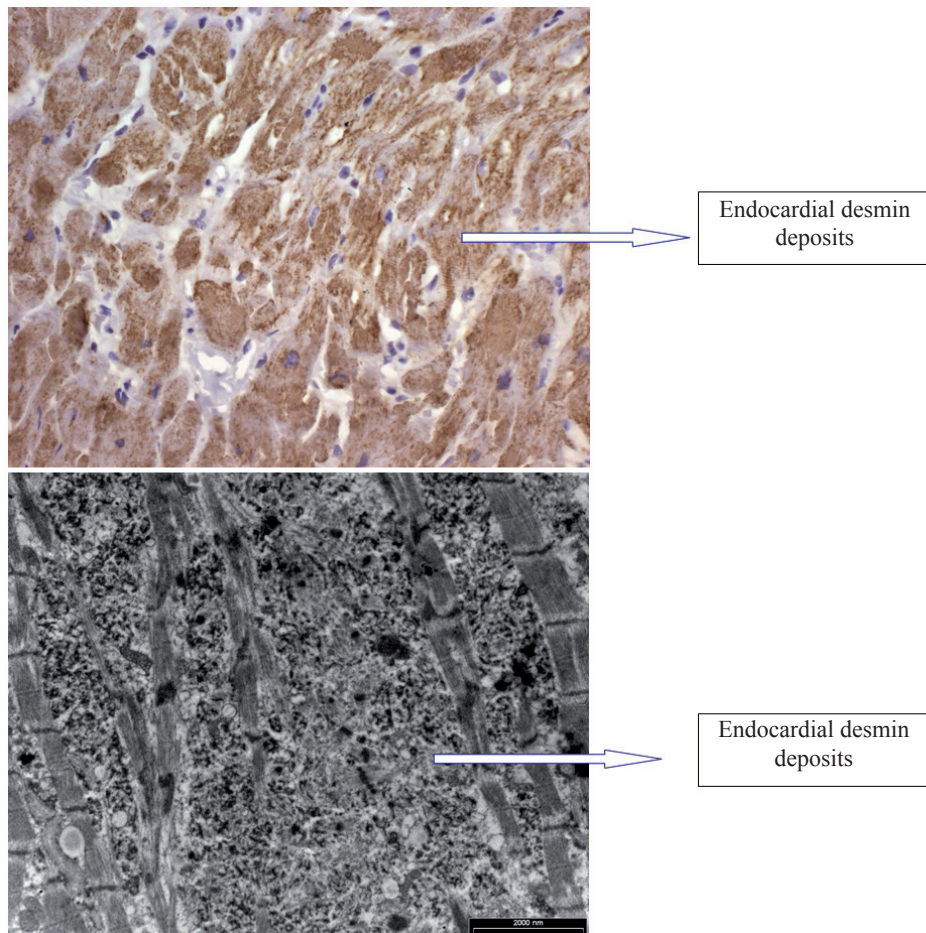


Fig. 1 - Endocardial biopsy fragments showing desmin deposits.

### Sources of Funding

There were no external funding sources for this study.

### Study Association

This study is not associated with any graduation program.

## References

1. Maron BJ, Towbin JA, Thiene G, Antzelevitch C, Corrado D, Arnett D, et al. Contemporary definitions and classification of the cardiomyopathies: an American Heart Association Scientific Statement From the Council on Clinical Cardiology, Heart Failure and Transplantation Committee; Quality of Care and Outcomes Research and Functional Genomics and Translational Biology Interdisciplinary Working Groups; and Council on Epidemiology and Prevention. *Circulation*. 2006; 113: 1807-16.
2. Hancock EW. Cardiomyopathy: differential diagnosis of restrictive cardiomyopathy and constrictive pericarditis. *Heart*. 2001; 86: 343-9.
3. Fuchs E, Cleveland DW. A structural scaffolding of intermediate filaments in health and disease. *Science*. 1998; 279: 514-9.
4. Arbustini E, Morbini P, Grasso M, Fasani R, Verga L, Bellini O, et al. Restrictive cardiomyopathy, atrioventricular block and mild to subclinical myopathy in patients with desmin-immunoreactive material deposits. *J Am Coll Cardiol*. 1998; 31: 645-53.
5. Taylor RGM, Slavov D, Ku L, di Lenarda A, Sinagra G, Carniel E, et al. Prevalence of desmin mutations in dilated cardiomyopathy. *Circulation*. 2007; 115: 1244-51.
6. Arbustini E, Pasotti M, Pilotto A, Pellegrini C, Grasso M, Previtali S, et al. Desmin accumulation restrictive cardiomyopathy and atrioventricular block associated with desmin gene defects. *Eur J Heart Fail*. 2006; 8: 477-83.
7. Olivé M, Goldfarb L, Moreno D, Laforet E, Dagvadorj A, Sambuughin N, et al. Desmin-related myopathy: clinical, electrophysiological, radiological, neuropathological and genetic studies. *J Neur Sci*. 2004; 219: 125-37.