

Use of Centrifugal Pump and Extracorporeal Membrane Oxygenation as Cardiopulmonary Support in Pediatric Cardiovascular Surgery

Fernando A. Atik, Rodrigo Santos de Castro, Fabiana Moreira Passos Succi, Maria Regina Barros, Cristina Afiune, Guilherme de Menezes Succi, Ricardo B. Corso, Cristiano N. Faber, Jorge Y. Afiune, Luiz Fernando Caneio

Instituto do Coração do Distrito Federal, Brasília, DF - Brazil

Summary

Background: Extracorporeal membrane oxygenation is a well-documented resuscitation method in patients with severe hemodynamic and/or respiratory impairment.

Objectives: To describe several aspects related to the use of extracorporeal membrane oxygenation in a pediatric heart center and determine its immediate and late outcomes.

Methods: Between October 2005 and January 2007, 10 patients who were submitted to pediatric cardiac surgery underwent extracorporeal membrane oxygenation implant. Median age was 58.5 days (40% neonates) and median body weight was 3.9 kg. Circulatory assistance was initiated aiming at the recovery and the weaning protocols followed daily clinical and echocardiographic criteria. Support was discontinued when transplant was contraindicated, when the patient was unable to recover or when survival was considered to be limited by a multidisciplinary team.

Results: Extracorporeal membrane oxygenation was employed after corrective or palliative heart surgery in 80% and preoperatively in the remaining ones. It was most often indicated for irresponsive hemodynamic instability (40%), post-cardiotomy shock (20%) and post-cardiac arrest (20%). The mean duration on support was 58 ± 37 hours. Weaning was successfully in 50% of the cases and 30% were discharged home. Actuarial survival was 40%, 30% and 20% at 30 days, 3 months and 24 months, respectively.

Conclusions: Extracorporeal membrane oxygenation is an effective and useful tool for the resuscitation of patients presenting severe hemodynamic and/or respiratory failure in the perioperative period of pediatric cardiovascular surgery. (Arq Bras Cardiol 2008; 90(4): 216-220)

Key words: Extracorporeal Membrane Oxygenation; Cardiovascular Surgical Procedures; Thoracic Surgery

Introduction

Cardiopulmonary support with a centrifugal or peristaltic pump coupled to an oxygenator is known as ECMO (Extracorporeal Membrane Oxygenation). Its main indications are respiratory support, especially in respiratory distress syndrome and cardiopulmonary support in post-cardiotomy cardiogenic shock, cardiorespiratory arrest and as a bridge to a prolonged circulatory assistance device or heart and/or lung transplant.

The use of this device in the context of patients submitted to cardiovascular surgery is related to the early identification and prompt correction of severe hemodynamic disorders that are refractory to conventional measures. The ideal moment for the ECMO indication varies according to the center, being decided on an individual basis. Different studies¹ have implicated this factor, among others, as being responsible for

adverse results associated to circulatory assistance, requiring a standardized approach.

The large experience acquired as well as the increasing progress in this area in international centers¹⁻⁶ has directed the development of this method in our country.

The objectives of this study were to describe several aspects related to the implant of pediatric ECMO in a national Service of Cardiovascular Surgery characterized by the integrated assistance to adults and children and determine its immediate and late outcomes.

Patients and Methods

Between October 2005 and January 2007, 11 patients were submitted to the ECMO as a mode of circulatory and/or respiratory support in patients that were candidate or submitted to cardiovascular surgery. Of these, 10 patients had congenital cardiopathies, which constitute our study sample. The male sex was predominant in 6 patients (60%) and median age was 58.5 days (3 days to 8.3 years). Four patients (40%) were neonates. Median weight was 3.9 kg, ranging from 2.7 and 22 kg.

The patients' anatomical diagnoses are shown in Table 1.

Mailing address: Fernando A. Atik •

Estrada Parque Contorno do Bosque s/n, Brasília, DF, Brazil

E-mail: atikf@mac.com

Manuscript received March 24, 2007; revised manuscript received October 23, 2007; accepted December 05, 2007.

Three of the patients (30%) had univentricular physiology.

The perioperative data were collected retrospectively from the patients' files and the follow-up was carried out through regular clinical consultations followed by echocardiographic assessment. This study was approved by the Ethics Committee in Research of our institution, which did not require the informed consent form.

ECMO implantation and procedure technique

The description of the circuit materials, cannula introduction techniques and the protocol of the ECMO procedure can be found in specific literature publications^{7,8}. In summary, the circuit is based on a centrifugal pump (Bio-Pump BP-80, Medtronic BioMedicus, Eden Prairie, MN, USA) together with an oxygenator (Jostra Quadrox, Maquet Cardiopulmonary AG, Hirrlinger, Germany). The cannula introduction was preferentially central, in the ascending aorta and the right atrium, in 8 patients (80%). The 2 remaining patients were submitted to the ECMO transplant through the right carotid artery and the internal jugular vein, without the need for open-chest procedures in one and right carotid artery and both atriums in the other.

Heparin was administrated before the cannula implant and continuously when the activated coagulation time (ACT) reached 250 seconds, in order to keep ACT between 150 and 200 sec. All patients were kept sedated, under orotracheal mechanical ventilation and with an open sternum, with a silicon membrane sutured around the borders of the surgical wound. Cardiopulmonary support was maintained with the aim of recovery and weaning according to the daily echocardiographic and clinical criteria. The indication for transplant was considered in cases when recovery was unlikely,

excluding severe neurological injury and active systemic infection. The support was discontinued in patients with no indication for transplant, in those unable to recover and patients with limited survival according to the multidisciplinary team's decision.

Statistical analysis

The categorical variables were expressed by frequencies and percentages and the continuous variables by means and standard deviations. Medians were used for samples with heterogeneous distribution. The actuarial survival was obtained through the Kaplan Meier method, using the statistical software JMP 5.0 for SAS Institute, Cary, NC.

Results

The ten patients needed the ECMO due to varied reasons. The implant was performed in the postoperative period of corrective or palliative surgeries in 8 patients (80%) and during the preoperative period in the remaining 2 patients, with one of the latter not undergoing any intervention. This was a patient with Williams syndrome and important hypoplasia of the ascending aorta, which prevented any type of surgical correction.

The ECMO was indicated due to severe hemodynamic instability that did not respond to the routine measures in postoperative period in 4 (40%) patients, post-cardiotomy syndrome at the extracorporeal circulation outlet in 2 (20%) patients, failure of cardiac resuscitation after cardiorespiratory arrest in 2 (20%) patients, severe respiratory failure in one patient in the postoperative period after the surgical correction of total anomalous drainage of the pulmonary veins and important hypoxia with hemodynamic instability

Table 1 - Diagnosis, procedures and evolution of patients submitted to cardiopulmonary support with extracorporeal membrane oxygenation.

| | Age | Weight (kg) | Diagnosis | Procedure | Evolution |
|----|------|-------------|------------------------------|---|-----------------------------|
| 1 | 1 m | 3,4 | Williams Syndrome | Diagnostic catheterism | Death |
| 2 | 7 a | 18,8 | Heterotaxis, DORV, PS | Blalock-Taussig Operation | Death |
| 3 | 3 a | 10,8 | IVC, AF | Ventriculoseptoplasty + aortic valve plasty | Weaning, hospital death |
| 4 | 4 m | 4,3 | TAPVD, IVC | Total correction | Weaning, hospital discharge |
| 5 | 4 d | 3,4 | TGA | Jatene Operation | Weaning, hospital discharge |
| 6 | 3 d | 2,7 | HLHS | Norwood Operation | Weaning, hospital death |
| 7 | 18 d | 3,6 | infra-cardiac TAPVD | Total correction | Death |
| 8 | 8 a | 22 | Right SV | Total Cavopulmonary Operation | Death |
| 9 | 2 m | 4,7 | Anomalous coronary | Total correction | Weaning, hospital discharge |
| 10 | 3 d | 2,9 | TF, pulmonary valve agenesis | Total correction | Death |

DORV - Double outlet right ventricle, PS - pulmonary stenosis, IVC - interventricular communication, AF - aortic failure, TAPVD - total anomalous pulmonary venous drainage, TGA - transposition of the great arteries, HLHS - Hypoplastic left heart syndrome, SV - single ventricle, TF - Tetralogy of Fallot, m - months, yr - years, d - days.

in the postoperative period after the surgical correction of the Tetralogy of Fallot with agenesis of the pulmonary valve, as a means of clinical stabilization. One of the patients that presented cardiorespiratory arrest was submitted to a temporary period of conventional extracorporeal circulation in an attempt to recover the cardiac function, before the ECMO implant.

The implant was carried out more frequently at the surgical center (50%) and at the Intensive Care Unit (40%). The remaining patient presented cardiorespiratory arrest while undergoing a diagnostic cardiac catheterization and the ECMO was implanted at the hemodynamic room. The median time interval between the onset of the event that triggered the indication and the start of the circulatory assistance was 20 minutes (0 to 180 min), with all the patients presenting severe tissue hypoperfusion and a mean serum lactate level of $12.4 \text{ mmol/l} \pm 4.4$.

During the ECMO procedure, the maximum arterial flow was $147 \text{ ml/kg/min} \pm 37$, leading to the normalization of the tissue perfusion data within four hours after the implant in all patients. Bleeding was the most common complication. Eight (80%) patients needed a surgical review of hemostasis, being necessary once in 5 patients, twice in 2 and three times in 1 patient. The causes of bleeding were related to coagulopathy in all patients, associated to sternum fracture in two and aorta bleeding around the arterial cannula in one. The mean amount of transfused red blood cell concentrate was $450 \text{ ml/kg} \pm 269$, frozen fresh plasma was $135 \text{ ml/kg} \pm 91$, platelet concentrate was $236 \text{ ml/kg} \pm 150$ and cryoprecipitate was $12 \text{ ml/kg} \pm 9.7$.

The mean time of the ECMO duration was 58 hours \pm 37. Cardiopulmonary support was successfully withdrawn in 5 (50%) patients and 3 (30%) were discharged from the hospital. The causes of death were related to cardiogenic shock and multiple-organ and system dysfunction in all patients, aggravated by alveolar hemorrhage in one and disseminated intravascular coagulation in another. Six patients presented acute renal failure, three presented sepsis and two presented respiratory distress syndrome. None of the patients was placed in a transplant list due to the presence of multiple-organ dysfunction.

All patients submitted to the ECMO remained with the chest open for the entire period of support, as well as an additional period for hemodynamic stabilization and bleeding control. The surgical chest wound was closed at the Intensive Care Unit (ICU) in all cases. There were no cases of mediastinitis, although the median time of open chest was 5 days (range: 12 hours to 26 days). The median time of mechanical ventilation, ICU stay and total postoperative period were 8.5 days, 15 days and 26.5 days, respectively.

The actuarial survival (Figure 1) was 40%, 30% and 20% at 30 days, 3 months and 24 months, respectively. After a mean follow-up of 11 ± 9 months, two of the three survivors present good general state, at functional class I. The control echocardiogram showed intact ventricular function, with no residual defects. Only one patient died 2 months after the Jatene operation due to cardiogenic shock secondary to acute myocardial infarction.

Discussion

The cardiopulmonary support with membrane oxygenator has been used with some satisfactory results in large world centers for years¹⁻⁶. In our country, its development and clinical application are limited, being restricted to a few high-complexity centers⁸. Nevertheless, the use of the ECMO in the perioperative period of cardiovascular surgery is an effective method to control severe hemodynamic⁹ or respiratory¹⁰ alterations, allowing the recovery of target-organs¹¹ or as bridge for transplant in selected cases¹²⁻¹⁴. The largest world experience with the method occurs in pediatric patients with respiratory failure. However, the use of the ECMO in adult patients has a significant applicability, in severe respiratory failure as well as in short-term circulatory assistance, aiming at recovery, as a bridge for another prolonged circulatory assistance device or as bridge to transplant. The use of the ECMO in adult patients in developed countries is not larger only due to the broad availability of artificial ventricles, of which the Brazilian experience is restricted to isolated cases.

In the present study, the use of the ECMO was restricted to a predominantly pediatric population, with 40% of them being neonates and 30% having univentricular physiology. By adopting a clinical procedure protocol that followed international directives^{7,8}, 50% of the patients had the ECMO successfully withdrawn and 30% were discharged from the hospital. Late survival corroborated the method efficacy in the survivors.

These data are in agreement with the international reported data¹⁵, which includes registered centers that send their data voluntarily. However, our sample does not allow us to corroborate the advantage of the ECMO when the indication is purely respiratory, according to other studies¹⁶. The most recent data of the international data registry, on weaning and hospital discharge, respectively, were 42% and 37% after pediatric cardiovascular surgery and 77% and 55% for respiratory causes. Nonetheless, the ECMO results vary according to the center, reflecting several types of indication and adverse factors related to the patient. Alsoufi et al¹⁷ identified age, weight,

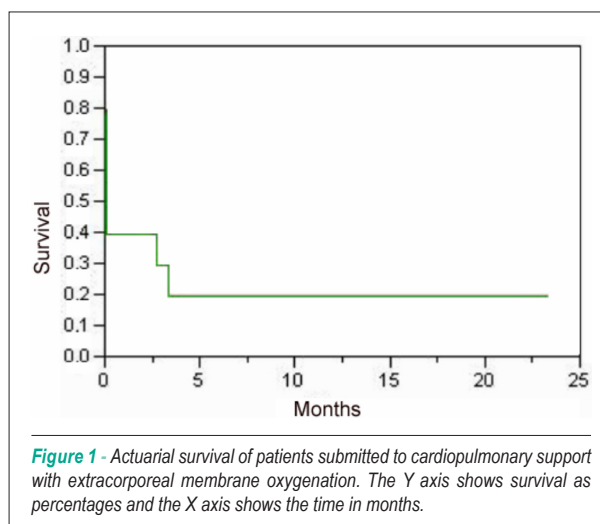


Figure 1 - Actuarial survival of patients submitted to cardiopulmonary support with extracorporeal membrane oxygenation. The Y axis shows survival as percentages and the X axis shows the time in months.

type and duration of assistance, univentricular physiology, re-exploration, number of complications, sepsis, renal and respiratory failure as mortality risk factors

As seen in the present study, the indications for the ECMO can be varied. The main indication was severe hemodynamic instability in the postoperative period. This situation typically manifests as systemic hypoperfusion and severe ventricular dysfunction, usually corroborated by the echocardiography, despite volemic replacement, inotropic support and ventilatory management⁶.

The failure to identify the problem and to promptly establish therapeutic measures leads to a situation of cardiocirculatory collapse and cardiac arrest. The latter was second more frequent indication for the ECMO in our experience, as well as myocardial failure at the extracorporeal circulation outlet. Del Nido¹⁸ defined the criteria for the indication of the ECMO post-cardiorespiratory arrest as rapid implementation of cardiopulmonary resuscitation, recovery failure after 20 minutes of the resuscitation onset and absence of contra-indications for the ECMO such as sepsis, severe neurological injury and multiple-organ failure. Technically, the implementation of the ECMO during cardiac arrest is more complicated, as it requires a previous circuit preparation, constant multiprofessional staff training and team coordination to perform the implant at the bedside. The introduction of the cannulae can be central, which requires the opening of the chest, or peripheral, through cervical or femoral vessels. Despite the need for logistic organization, the use of the ECMO during a cardiorespiratory arrest must be encouraged¹⁹⁻²¹, as it is an effective form of resuscitation and the result is similar to the use of the ECMO due to other causes²².

The concept of elective or semi-elective indication of the ECMO has become increasingly popular. In fact, the proposal of the extensive use of this practice follows intuitive criteria, in order to allow the reversibility of the circulatory shock. Certainly, ECMO failure is directly proportional to the duration of the multiple-organ failure^{1,4}. The longer the duration of the circulatory assistance, the higher the complications, considering that invariably, irreversible microcirculation alterations occur.

These factors encouraged some groups to use the ECMO routinely after complex neonatal surgeries such as the first stage of Norwood²³.

The ECMO complications are mainly related to the exposure of blood to non-endothelial surfaces, especially the membrane oxygenator. The inflammatory cascade activation occurs, followed by coagulation activation, hemolysis and thromboembolytic phenomena are generated, all contributing to multiple-organ injury. The use of membrane oxygenators with a better profile²⁴ and heparin-coated circuits can minimize these complications.

The most frequent complication, as shown in the present study, is bleeding, normally caused by coagulation alterations and the fact that the chest is kept open, exposing a large surgical area to the effects of anticoagulation.

It is extremely important to maintain the activated coagulation time between 150 and 200 seconds, platelet count > 100,000 and fibrinogen levels > 100 mg/dl. The

use of hemocomponents is important in order to warrant adequate oxygen transport to the tissues with hematocrit > 35% and to replace coagulation factors. The surgical review of hemostasis must be carried out as soon as there is a large volume of acute bleeding, persistence of bleeding for several hours or signs of cardiac tamponade. The indication threshold in our experience is low, with the review being carried out at the bedside in the ICU, for all patients.

Renal complications are usually not a problem. Renal function recovery normally occurs with the normalization of tissue perfusion, maintaining an adequate pulse pressure. In case of persistent renal dysfunction, a hemofilter can be added to the circuit to remove fluids and correct electrolyte and acid-base disorders.

As with any severely-ill patient, nutrition optimization is essential for recovery. Similarly, constant care and the liberal use of antibiotics are important in the treatment of infections that can easily lead to sepsis²⁵. The high susceptibility to these problems can be explained by the immunosuppression caused by the circulatory assistance, highly invasive procedures with the use of catheters and cannulae, presence of an open chest, prolonged mechanical ventilation and bacterial translocation.

Although the cost of the ECMO was not specifically assessed in the present study, it is known to be elevated, including the material used and patient care. Although the ECMO is included in the list of procedures covered by health insurance companies and the public health system, the amount paid by these healthcare providers is insufficient. However, the ECMO showed to be an effective method, allowing the survival of some patients who, otherwise, would not have another viable treatment option. We believe that the cost of treatment cannot be used as a negative factor in relation to the method, depriving some patients from having a real possibility of recovery or a bridge to transplant.

We conclude that cardiopulmonary support with membrane oxygenation is an effective and useful method of resuscitation in severe cardiovascular and pulmonary disorders in the perioperative period of cardiovascular surgery. The presence of an experienced and supportive multiprofessional team is essential for the early identification of complications that can abbreviate survival. In this context, it is extremely important to accumulate experience from several centers in the form of a national database in order to determine procedure guidelines. In the future, regular reviews of these data can rationalize the resources in reference centers dedicated to the high complexity of cardiovascular treatment.

Acknowledgements

The authors would like to thank the following professionals who made possible the organization of a mechanical circulatory assistance program. To the clinical perfusionists: Henrique Marangone N. Sampaio, Denise Lopes Costa, Mateus de Souza Santos and Karina Pereira Michelette; to the nursing staff led by Gladis Aparecida de Faria and to the

physical therapy team led by Aida Turquetto.

Potential Conflict of Interest

No potential conflict of interest relevant to this article was reported.

References

- Aharon AS, Drinkwater DC Jr, Churchwell KB, Quisling SV, Reddy VS, Taylor M, et al. Extracorporeal membrane oxygenation in children after repair of congenital cardiac lesions. *Ann Thorac Surg.* 2001; 72: 2095-102.
- Kolovos NS, Bratton SL, Moler FW, Bove EL, Ohye RG, Bartlett RH, et al. Outcome of pediatric patients treated with extracorporeal life support after cardiac surgery. *Ann Thorac Surg.* 2003; 76: 1435-42.
- Undar A, McKenzie ED, McGarry MC, Owens WR, Surprise DL, Kilpack VD, et al. Outcomes of congenital heart surgery patients after extracorporeal life support at Texas Children's Hospital. *Artif Organs.* 2004; 28: 963-6.
- Chaturvedi RR, Macrae D, Brown KL, Schindler M, Smith EC, Davis KB, et al. Cardiac ECMO for biventricular hearts after paediatric open heart surgery. *Heart.* 2004; 90: 545-51.
- Shah SA, Shankar V, Churchwell KB, Taylor MB, Scott BP, Bartilson R, et al. Clinical outcomes of 84 children with congenital heart disease managed with extracorporeal membrane oxygenation after cardiac surgery. *ASAIO J.* 2005; 51: 504-7.
- Thourani VH, Kirshbom PM, Kanter KR, Simsic J, Kogon BE, Wagoner S, et al. Venoarterial extracorporeal membrane oxygenation (VA-ECMO) in pediatric cardiac support. *Ann Thorac Surg.* 2006; 82: 138-45.
- Duncan BW. Mechanical support for cardiac and respiratory failure in pediatric patients. New York: Marcel Dekker, Inc; 2001.
- Caneo LF. Condutas na ECMO. In: Auler JO Jr, Oliveira SA. Pós-operatório de cirurgia torácica e cardiovascular. Porto Alegre: Artmed; 2004. p. 280-302.
- Walters HL, Hakimi M, Rice MD, Lyons JM, Whittlesey GC, Klein MD. Pediatric cardiac surgical ECMO: multivariate analysis of risk factors for hospital death. *Ann Thorac Surg.* 1995; 60: 329-36.
- Dhillon R, Pearson GA, Firmin RK, Chan KC, Leavage R. Extracorporeal membrane oxygenation and the treatment of critical pulmonary hypertension in congenital heart disease. *Eur J Cardiothorac Surg.* 1995; 9: 553-6.
- Duncan BW, Bohn DJ, Atz AM, French JW, Laussen PC, Wessel DL. Mechanical circulatory support for the treatment of children with acute fulminant myocarditis. *J Thorac Cardiovasc Surg.* 2001; 122: 440-8.
- Del Nido PJ, Armitage JM, Fricker FJ, Shaver M, Cipriani L, Dayal G, et al. Extracorporeal membrane oxygenation support as a bridge to pediatric heart transplantation. *Circulation.* 1994; 90 (5 Suppl 2): II66-II69.
- Gajarski RJ, Mosca RS, Ohye RG, Bove EL, Crowley DC, Custer JR, et al. Use of extracorporeal life support as a bridge to pediatric cardiac transplantation. *J Heart Lung Transplant.* 2003; 22: 28-34.
- Fiser WP, Yetman AT, Gunselman RJ, Fasules JW, Baker LL, Chipman CW, et al. Pediatric arteriovenous extracorporeal membrane oxygenation (ECMO) as a bridge to cardiac transplantation. *J Heart Lung Transplant.* 2003; 22: 770-7.
- Meliones JN, Custer JR, Snedecor S, Moler FW, O'Rourke PP, Delius RE. Extracorporeal life support for cardiac assist in pediatric patients: review of ELSO Registry data. *Circulation.* 1991; 84 (5 Suppl): III168-III172.
- Swaniker F, Kolla S, Moler F, Custer J, Grams R, Barlett R, et al. Extracorporeal life support outcome for 128 pediatric patients with respiratory failure. *J Pediatr Surg.* 2000; 35: 197-202.
- Alsoufi B, Shen I, Karamlou T, Giacomuzzi C, Burch G, Silberbach M, et al. Extracorporeal life support in neonates, infants, and children after repair of congenital heart disease: modern era results in a single institution. *Ann Thorac Surg.* 2005; 80: 15-21.
- del Nido PJ. Extracorporeal membrane oxygenation for cardiac support in children. *Ann Thorac Surg.* 1996; 61: 305-11.
- Morris MC, Wernovsky G, Nadkarni VM. Survival outcomes after extracorporeal cardiopulmonary resuscitation instituted during active chest compressions following refractory in-hospital pediatric cardiac arrest. *Pediatr Crit Care Med.* 2004; 5: 440-6.
- Mahle WT, Forbes JM, Kirshbom PM, Cuadrado AR, Simsic JM, Kanter KR. Cost-utility analysis of salvage cardiac extracorporeal membrane oxygenation in children. *J Thorac Cardiovasc Surg.* 2005; 129: 1084-90.
- Massetti M, Tasle M, Le Page O, Deredec R, Babatasi G, Buklas D, et al. Back from irreversibility: extracorporeal life support for prolonged cardiac arrest. *Ann Thorac Surg.* 2005; 79: 178-84.
- Duncan BW, Ibrahim AE, Hraska V, del Nido PJ, Laussen PC, Wessel DL, et al. Use of rapid-deployment extracorporeal membrane oxygenation for the resuscitation of pediatric patients with heart disease after cardiac arrest. *J Thorac Cardiovasc Surg.* 1998; 116: 305-11.
- Ungerleider RM, Shen I, Yeh T, Schultz J, Butler R, Silberbach M, et al. Routine mechanical ventricular assist following the Norwood procedure: improved neurological outcome and excellent hospital survival. *Ann Thorac Surg.* 2004; 77: 18-22.
- Horton S, Thuys C, Bennett M, Augustin S, Rosenberg M, Brizard C. Experience with the Jostra rotaflo Quadrox oxygenator for ECMO. *Perfusion.* 2004; 19: 17-23.
- Montgomery VL, Strotman JM, Ross MP. Impact of multiple organ system dysfunction and nosocomial infections on survival of children treated with extracorporeal membrane oxygenation after heart surgery. *Crit Care Med.* 2000; 28: 526-31.

Sources of Funding

There were no external funding sources for this study.

Study Association

This study is not associated with any graduation program.