

## Traumatic Fistula between the Brachiocephalic Trunk and the Brachiocephalic Vein Due to Gunshot Wound

Pedro Paulo Martins de Oliveira, Orlando Petrucci, Karlos Alexandre de Souza Vilarinho, Lindemberg Mota Silveira, Reinaldo Wilson Vieira, Domingo Marcolino Braile

Faculdade de Ciências Médicas da Universidade Estadual de Campinas (Unicamp), Campinas, SP - Brazil

We describe the case of a 49-year old male patient who suffered a gunshot wound in the chest which transfixed the medial mediastinum. He was hemodynamically stable, but had tachycardia and tachypnea. He was submitted to integrated work-up with chest radiogram, transthoracic echocardiography, computerized chest tomography, and arteriography of the aortic arch. A traumatic fistula was evidenced between the brachiocephalic trunk and the brachiocephalic vein. Surgical repair was performed using extracorporeal circulation and deep hypothermia with total circulatory arrest. The patient progressed well and was discharged on the fifth day postoperatively.

### Introduction

Arteriovenous fistula is a well described type of traumatic vessel injury caused by a firearm projectile found in most cases in peripheral vessels. Arteriovenous fistulas in central vessels are highly lethal and there are few reports of satisfactory outcomes after treatment in the literature<sup>1,2</sup>. In most of the cases described, the clinical picture has a late onset and presents cardiac decompensation at variable intervals between the trauma and the diagnosis of high output fistula. Here we report the case of an individual who presented with a gunshot wound with an acute clinical picture and with a fistula between the brachiocephalic trunk and the brachiocephalic vein that had early treatment.

### Case Report

The 49-year old male patient was the victim of a firearm projectile wound in that the entrance orifice was in the second right intercostal space on the hemiclavicular line and the projectile lodged at the level of the fifth left intercostal space in the medial mediastinum, on the hemiclavicular line. He was referred to our department six hours after the incident. First care received was the administration of a cristalloyd infusion (2,000 ml).

### Key words

Arteriovenous fistula; brachiocephalic trunk; firearms.

On admission, the patient presented with pallor, tachypnea (RF 28), tachycardia (HR 150 bpm), and arterial pressure of 130 x 90 mmHg, symmetric in superior limbs. He presented no alterations in peripheral pulses or murmurs on heart auscultation. The chest radiogram evidenced enlargement of the superior mediastinum with no other alterations (fig.1). Chest computerized tomography showed the image of a hematoma in the anterior mediastinum, small pleural effusion on the left, with no signs of lesions in large vessels and absence of pericardial effusion. No alterations were shown on upper digestive endoscopy. The transthoracic echocardiography showed intense mosaic-pattern flow close to the origin of the brachiocephalic trunk. On aortography a fistula from the brachiocephalic trunk to the brachiocephalic vein was observed. The lesion was located in the origin of the brachiocephalic trunk (fig. 2).

We decided to perform an urgent surgical procedure. After anesthetic induction and monitoring, the right common femoral artery was dissected. After complete median longitudinal sternectomy had been performed, we observed the presence of a large hematoma in the anterior mediastinum. Under systemic heparinization, the common femoral artery and the right atrium were cannulated with a double-stage cannula; during cannulation there was rebleeding of the aortic injury and the aorta was digitally controlled. The extracorporeal circulation was started with induction of deep hypothermia (20° C), followed by complete circulatory arrest which allowed the dissection of vascular injuries and their repair.

An injury in the origin of the brachiocephalic trunk, covering approximately half its circumference and a complex injury of the brachiocephalic vein were found. The arterial injury was sutured with separate polypropylene 4.0 stitches and the brachiocephalic vein was ligated. The total time of circulatory arrest was seven minutes and the total time of extracorporeal circulation was 43 minutes.

The patient progressed well postoperatively. He remained in the intensive care unit for 48 hours and was discharged on the fifth day postoperatively; he recovered uneventfully and was totally asymptomatic. The pulses and the arterial pressure measurement were symmetric in the upper limbs.

### Discussion

Traumatic aortic injury accounts for a small number of firearm wounds (5.3%)<sup>3</sup>; however the mortality rate is high, and 73% of the patients arrive to the emergency room with detectable arterial pressure; 78% of them require urgent thoracotomy<sup>1</sup>. Penetrating injuries of the aorta account for less than 1% of all

Mailing address: Orlando Petrucci •

Rua João Baptista Geraldi, 135, Barão Geraldo - 13085-020 - Campinas, SP - Brazil  
E-mail: orlandopetrucci@gmail.com

Manuscript received June 17, 2007; revised manuscript received August 26, 2007; accepted October 2, 2007.

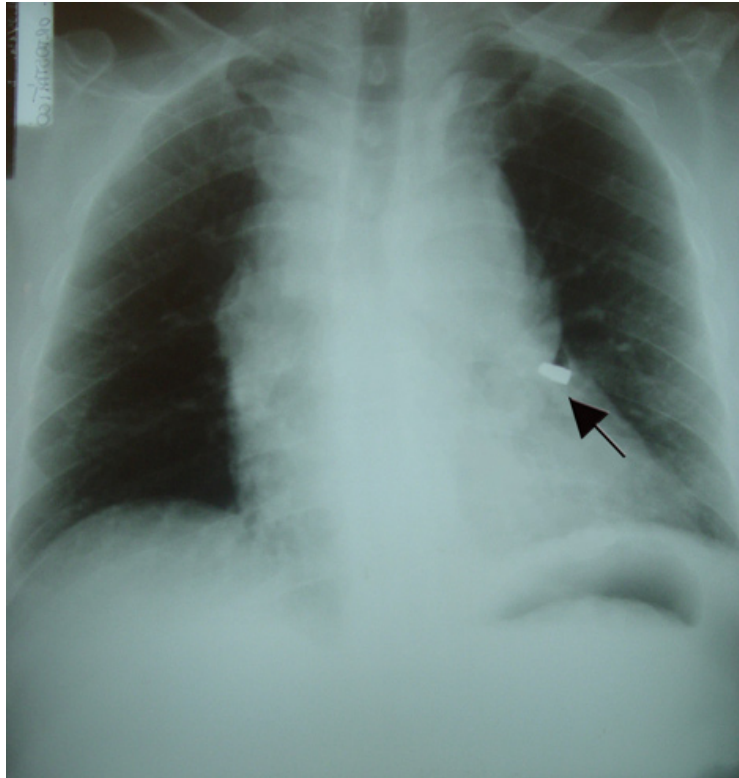


Figure 1 - Chest X-ray showing mediastinal widening and a bullet in the left hemithorax (arrow).

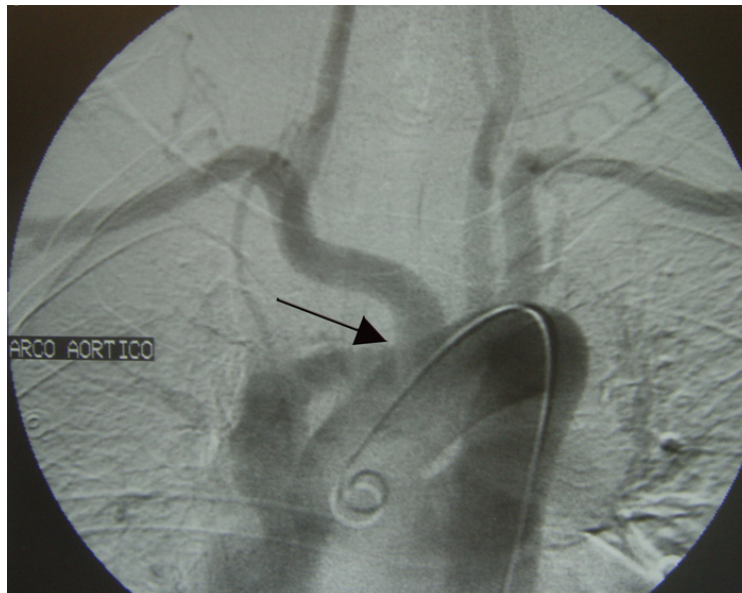


Figure 2 - Aortogram demonstrating contrast material in the brachiocephalic vein. The arrow indicates the site of the fistula.

aortic injuries<sup>1</sup>. In the English language literature we researched, there is only one case described of fistula between the aorta and the brachiocephalic vein secondary to wound caused by a firearm projectile diagnosed soon after the trauma<sup>2</sup>.

Beall et al.<sup>4</sup>, in 1962, was the first to describe the acute presentation of fistula between the aorta and the brachiocephalic vein, with diagnosis reached by the progressive enlargement of the mediastinum in serial chest

## Case Report

radiograms, associated with fremitus and murmur in the anterior chest region, as well as venous distension<sup>4</sup>.

The initial procedure for these cases is controversial. After Brickell's prospective study about patients with penetrating trauma of the chest, where higher mortality and longer hospital stay were described when patients underwent immediate volume replacement as compared with late volume replacement in the operation theater, it was suggested that mild hypotension might have a protective effect in this type of patients<sup>5</sup>.

The population of patients with penetrating trauma of the aorta differs a little from the population with blunt trauma of the aorta. In the first group the patients are younger, without comorbid diseases, whereas in the second group patients are generally older and sometimes have comorbidities. The incidence of penetrating injuries of the aorta has been increasing by virtue of the high rates of urban violence. Surgical treatment by open route is still considered the standard treatment<sup>6</sup>.

We point out the importance of an accurate diagnosis and the location of the arterial injury preoperatively which allows the development of a targeted surgical strategy, thus reducing surgery time and increasing the possibilities of satisfactory outcomes. We highlight that complete circulation arrest is necessary in the repair of this type of injury. Without the circulatory arrest, surgical repair would have been more difficult, and more blood products would have been used because of the large volume of blood loss and the higher risk of ischemic and embolic injuries during surgical repair.

Some observations are valid as regards the procedure adopted, especially since no endovascular procedure was used. Firstly, even in reference centers, prostheses of the appropriate size as regards caliber are not easily found because the aortas are healthy and young and have the normal caliber. The durability of these prostheses in the long term is still unknown in view of the potential secondary procedures in late follow-up<sup>6</sup>.

Secondly, the site of the fistula was unfavorable and it was proven intraoperatively that injuries in the brachiocephalic vein and in the brachiocephalic trunk were too large for endovascular treatment.

Demmers et al.<sup>7</sup>, in a series from 1993 to 2000, with an average follow-up of  $55 \pm 29$  months of patients with ulcer of the aorta submitted to endovascular treatment, showed that in a 6-year follow-up period only 51% of the patients were free from reoperation. These authors suggest that the procedure is safe in the short term; however, the long term follow-up doesn't provide reliable data regarding the durability of the prostheses. Although these authors reported on ulcer of the aorta, follow-up is related with complications of self-expandable stents. Therefore, these results suggest that these patients with a low life expectancy or high risk for surgery should be submitted to endovascular treatment of aortic penetrating injuries, whereas young patients with no other concurrent injuries should be submitted to conventional surgery<sup>7</sup>.

Patients who survive penetrating trauma of the aorta and concurrently of the brachiocephalic vein are still uncommon and constitute a challenge for surgeons in all phases of the care, from pre-hospital care to surgical procedures. However, with the evolution of diagnostic and therapeutic methods, associated with improved systematization of pre-hospital care, the success rates of the treatment of these occurrences that have a mortality rate above 80% are expected to improve<sup>1</sup>.

It is worth noting that the patient's injury was accurately diagnosed preoperatively and that other associated injuries have been ruled out, which allowed a targeted intervention with the purpose of providing safe and efficient repair.

### Potential Conflict of Interest

No potential conflict of interest relevant to this manuscript was reported.

### Sources of Funding

There were no external funding sources for this study.

### Study Association

This study is not associated with any graduation program.

## References

1. Demetriades D, Theodorou D, Murray J, Corwell E, Asensio J, et al. Mortality and prognostic factors in penetrating injuries of the aorta. *J Trauma*. 1996; 40: 761-3.
2. Roye GD, Zorn GL, McGiffin DC, Kirklind JW, Hamrick KM, Bessey PQ, et al. Acute repair of aorta-innominate vein fistulas. *J Trauma*. 1995; 39: 753-6.
3. Demetriades D. Penetrating injuries to the thoracic great vessels. *J Card Surg*. 1997; 12 (Suppl): 173-80.
4. Beall AC, Roof WR, De Bakey ME. Successful surgical management of through-through stab wounds of aortic arch. *Ann Surg*. 1962; 156: 823-6.
5. Bickell WH, Wall MJ Jr, Pepe PE, Martin RR, Genger VF, Allen MK, et al. Immediate versus delayed fluid resuscitation for hypotensive patients with penetrating torso injuries. *N Engl J Med*. 1994; 331: 1105-9.
6. Fang TD, Peterson DA, Kirilcuk NN, Dicker RA, Spain DA, Brundage SI. Endovascular management of a gunshot wound to the thoracic aorta. *J Trauma*. 2006; 60: 204-8.
7. Demers P, Miller DC, Mitchell RS, Kee ST, Chagonjian L, Dake MD. Stent-graft repair of penetrating atherosclerotic ulcers in the descending thoracic aorta: mid term results. *Ann Thorac Surg*. 2004; 77: 81-6.