

Case 5/2010 - A Seven-Year-Old Girl with Tetralogy of Fallot and Absent Pulmonary Valve

Edmar Atik, Fabiana M. Passos, José L. Andrade

Hospital Sírio Libanês, São Paulo, SP - Brazil

Clinical data

The patient presented with hypoxia in the neonatal period, and for this reason an early systemic-to-pulmonary shunt was indicated at 13 days of life. Shortness of breath since birth did not prevent her from performing full physical activity. She continued to present with mild cyanosis on exertion, although the Blalock-Taussig shunt had not been patent since she was one year old. The patient was receiving digoxin sinceas of three years of age.

On physical examination, she was in good general state of health, with no respiratory distress or cyanosis and her pulses were normal. Wake arterial oxygen saturation was 88.0% and the aorta was not palpable at the suprasternal notch.

The cardiovascular examination revealed slightly forceful precordial impulses at the left sternal border, and the apex impulse was palpable at the 4th left intercostal space. The heart sounds were accentuated, and a grade 2/6 systolic-diastolic murmur was heard along the left sternal border, with no thrill. The liver was not palpable and the lungs were clear to auscultation, with no abnormal chest sounds.

Electrocardiogram showed normal sinus rhythm and signs of right and left ventricular overload with predominance of the right ventricle. The AQRS was at +90°, AP: +60°, AT: +80° (Figure 1).

Radiographic image

The radiographic image shows a mildly enlarged cardiac silhouette with a rounded ventricular contour, bulging main pulmonary artery contour +++ and increased pulmonary vasculature, especially in the pulmonary hila (Figure 1).

Diagnostic hypothesis

The image is consistent with the diagnosis of pulmonary valve regurgitation, which leads to significant dilatation of the

Key words

Fallot tetralogy, absent pulmonary valve.

main pulmonary arteries. Usually, this anomaly accompanies tetralogy of Fallot with annular pulmonary stenosis and interventricular septal defect.

Differential diagnosis

Other heart diseases associated with pulmonary valve regurgitation may also have manifestations similar to those previously described. Among them, we can mention pulmonary valve stenosis, heart diseases with pulmonary artery dilatation due to increased pulmonary blood flow, and also heart diseases accompanied by pulmonary arterial hypertension, all in the long term.

Diagnostic confirmation

The clinical findings were decisive for the diagnosis of tetralogy of Fallot with absent pulmonary valve, particularly the systolic-diastolic murmur with mild hypoxemia (bidirectional shunt through the VSD) and, above all, the characteristic radiographic image.

Echocardiography confirmed this diagnosis, showing significantly dilated pulmonary arteries with diameters of 24 mm on the right and 14 mm on the left. The pulmonary annulus was narrow, measuring 8 mm; there was also infundibular pulmonary stenosis with anterior deviation of the infundibular septum and a large subaortic VSD, with 15 mm of diameter. Pulmonary valve regurgitation and tricuspid valve regurgitation were also present. The ventricles were dilated (Figure 2).

Cardiac catheterization showed similar pressures in both ventricles (80/10 mmHg), and the pressure in the main pulmonary artery (30/5 mmHg) evidenced severe pulmonary valve regurgitation, in addition to pulmonary valve stenosis.

Management

During surgery, ECC time was 160 min and anoxia time was 70 min. The infundibular stenosis was resected via the right atrium; the absent pulmonary valve was visualized via the pulmonary trunk, as remaining thick and retracted buds in a narrow pulmonary ring. The RV outflow tract was enlarged to the pulmonary trunk and the VSD was closed with bovine pericardium. Number-18 decellularized homograft was implanted in the pulmonary position, and the tricuspid regurgitation was repaired using annuloplasty.

The patient had a favorable outcome and was discharged seven days later.

Mailing address: Edmar Atik •

Rua Dona Adma Jafet, 74 conj. 73 - Bela Vista - 01308-050 - São Paulo, SP - Brazil

E-mail: conatik@incor.usp.br, eatik@cardiol.br

Manuscript received July 30, 2009; revised manuscript received November 12, 2009; accepted November 12, 2009.

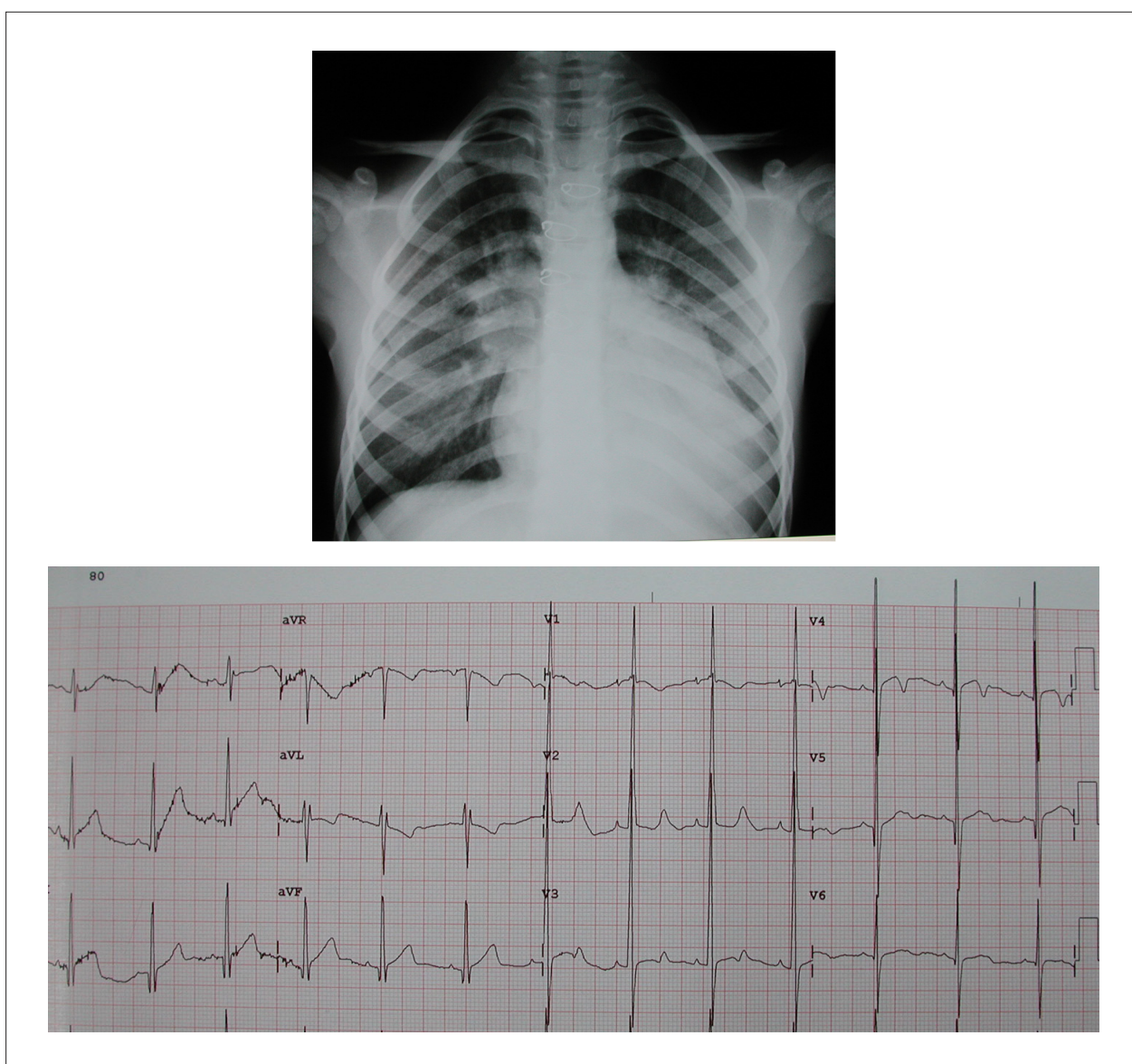


Figure 1 - Chest radiography showing mildly enlarged rounded cardiac silhouette, with increased pulmonary vasculature in both pulmonary hila and bulging main pulmonary artery contour. The electrocardiogram shows signs of right and left ventricular overload, with predominance of the right ventricle.

Comments

Absent pulmonary valve is easy to recognize clinically and there are different explanations for its variable outcomes. Usually, it manifests with marked pulmonary artery dilatation that leads to intraparenchymal bronchial compression; this is responsible for the significant and early pulmonary manifestations which require surgical intervention, sometimes even in the first few months of life.

Rare cases, such as the one reported here, live beyond this age range and have a more favorable outcome because of

the more intense bronchial wall thickening, which prevents extrinsic compression and makes the surgical correction less risky.

It is noteworthy that this patient did not benefit from the systemic-to-pulmonary shunt performed in the neonatal period, given that she persisted with mild hypoxia, even after the shunt was demonstrated to be closed at the age of one year. This aspect emphasizes the need for greater care when indicating this technique to similar patients, especially neonates, whose risk is certainly higher.

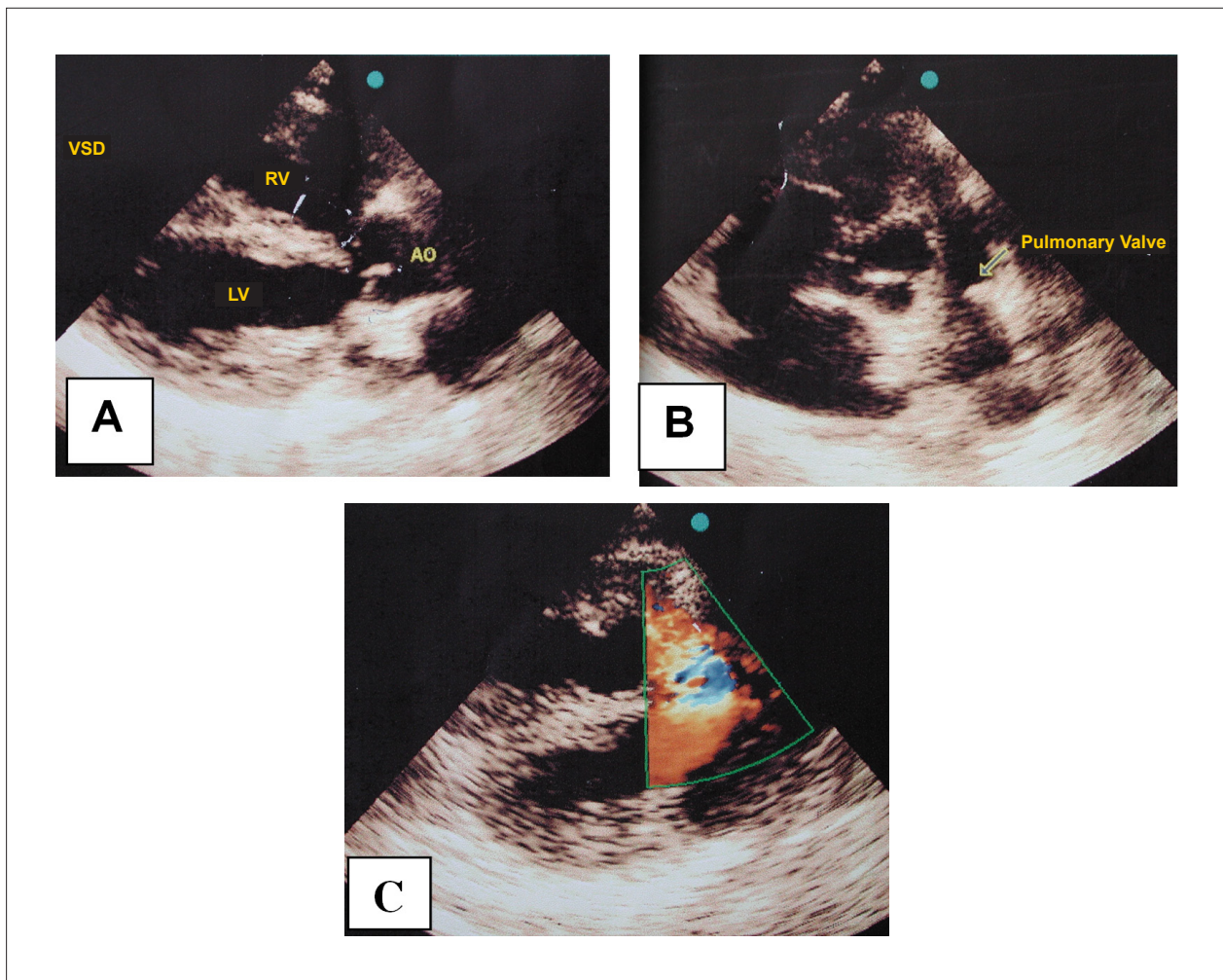


Figure 2 - Echocardiogram showing signs of tetralogy of Fallot with the aorta riding over the interventricular septum and subaortic VSD (A); narrow pulmonary annulus and dilatation of the main and central pulmonary arteries (B); and pulmonary valve stenosis and regurgitation on color-Doppler (C).