

## Cardiac Magnetic Resonance and its Anatomical Planes - How do I do it?

Marcelo Souto Nacif<sup>1,2,3,4</sup>, Amarino Carvalho de Oliveira Junior<sup>4</sup>, Antonio Carlos Pires Carvalho<sup>3</sup>, Carlos Eduardo Rochitte<sup>4,5</sup>

Centro Universitário Serra dos Órgãos (UNIFESO)<sup>1</sup>, Teresópolis, RJ; Hospital de Clínicas de Niterói (HCN)<sup>2</sup>, Niterói, RJ; Universidade Federal do Rio de Janeiro (UFRJ)<sup>3</sup>; Hospital Pró-Cardíaco<sup>4</sup>, Rio de Janeiro, RJ; Instituto do Coração (InCor) - Hospital das Clínicas da Faculdade de Medicina da Universidade de São Paulo<sup>5</sup>, São Paulo, SP - Brazil

### Abstract

Due to the increasing use of the cardiac magnetic resonance (CMR) method and the frequent implementation of such method in new services, we describe herein, in a step-by-step format, the acquisition techniques that are necessary for a complete cardiac approach, of the main anatomical planes of the heart used by CMR.

### Introduction

The cardiac magnetic resonance (CMR) gained prominence as a standard method in the study of the ventricular function, by the Simpson method, and in the myocardial viability research, by the late enhancement technique<sup>1,2</sup>.

Recent studies have revealed the CMR importance in the research on myocardial ischemia, in which the technique of perfusion under pharmacological stress is used. That is why now it is considered a well-established multimodal method in the study of the heart in the coronary artery disease<sup>2-5</sup>.

According to Bezerra et al<sup>6</sup>, in a 2006 article, CMR has gained more and more and prominence and importance in radiology and image diagnosis services, mainly because there is a reduction in test time and because it allows one to obtain images in patients with arrhythmia or in those whose performance level in breath-holding tests is below the standard<sup>6,7</sup>.

A fact that has been neither defined nor sufficiently addressed in scientific articles is the cost-effectiveness ratio of the test in our country. This is an important issue, because it may limit the adoption of such method, which is currently used in large centers only. Real-time sequences are accelerating the test, causing its implementation on daily basis to be more advantageous, as there is a time gain with no detriment to

measures associated with volumes, indexes and ejection fraction, which are necessary for a full heart analysis<sup>8,9</sup>.

The diagnosis accuracy in the elucidation of etiologies of non-ischemia cardiomyopathies, especially in myocarditis cases, has established a new role for CMR in the daily cardiologic and radiological practice<sup>7,10</sup>. With the increase in the number of articles referring to the theme<sup>10-16</sup> in Brazil, we are certain that CMR will have a lot of influence on the prognosis of patients with cardiopathy, causing the method to be indisputably indispensable to the cardiologic and radiologic practice.

The increasing application of magnetic resonance in therapeutic routine requires that requesting doctors be more familiarized with anatomical planes normally used. Therefore, our main purpose was to describe, in an educational way, CMR's major planes.

### Anatomical planes

#### Cardiac axis orientation

In the beginning of the resonance study, there are always three anatomical planes: coronal, sagittal and axial (Figures 1A, 1B and 1C, respectively), which are axes that are orthogonal to the thorax and do not follow the cardiac orientation. We prescribe, in the axial axis of the thorax, a plane that covers the left ventricle (LV) and the left atrium (LA) extending towards the median plane of the ventricular cavity (Figure 1C). This acquisition will provide us with a plane known as the vertical long axis (two-chamber localizer - Figure 1D), in which we will be able to identify the obliquity of the cardiac axis in the superoinferior plane. In the image, we will be able to plan the acquisition of the horizontal long axis (four-chamber localizer - Figure 1E) that, as the name says, will allow the identification of the LV, the LA, the right ventricle (RV) and the right atrium (RA). At this point in the exam, we have the oriented cardiac axis and we can prescribe the short axis (Figure 1E or 1F), always orthogonal to the LV, and from the base to the apex (Figure 1G), and in some cases, it may even be extended to the atriums.

#### Marking of radial long-axis planes

Starting at the basal planes of the short axis near the left ventricular outflow tract (LVOT) and at the first basal plane in which we do not identify it, we mark the radial long axes (Figure 2A). The marking is important for the complete territorial,

### Keywords

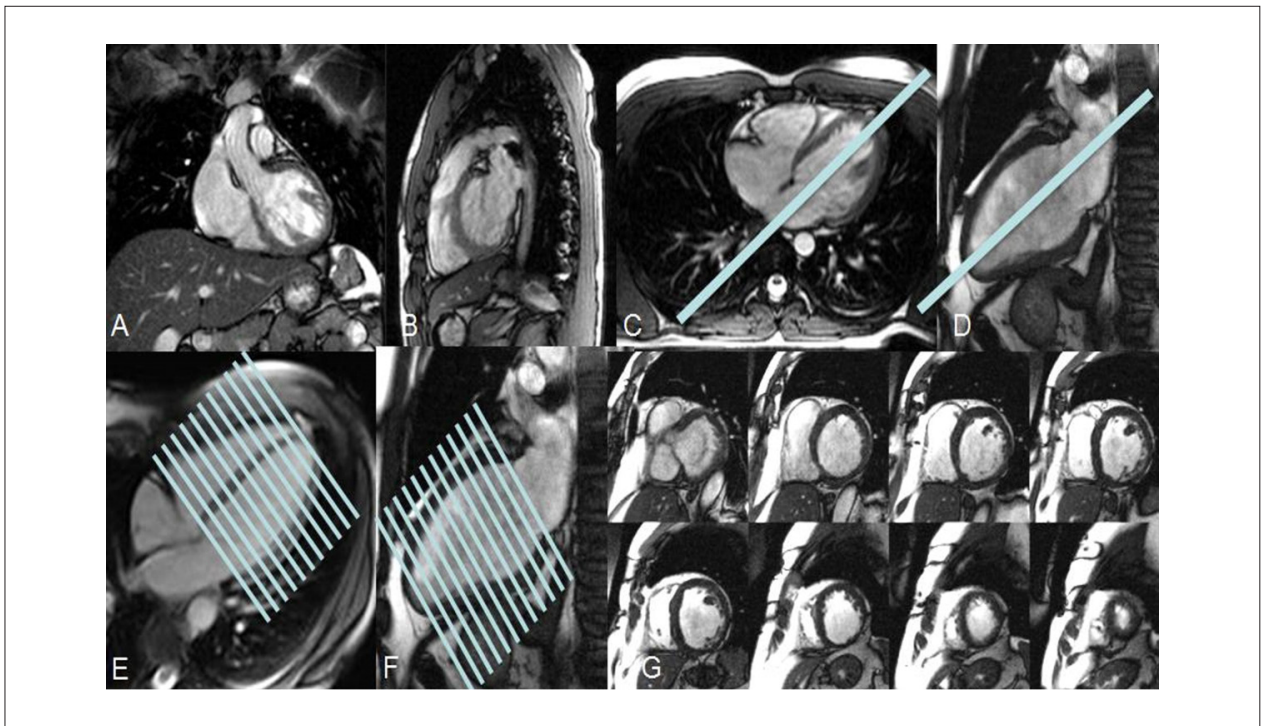
Magnetic resonance imaging; heart; education, medical.

Mailing address: Marcelo Souto Nacif •

Rua Tavares de Macedo 136/1503 Bl A - Icaraí - 24220-211 - Niterói, RJ - Brazil

E-mail: msnacif@yahoo.com.br, msnacif@gmail.com

Manuscript received March 20, 2009; revised manuscript received March 20, 2009; accepted June 24, 2009.



**Figure 1** - The beginning of the exam. Localizing sequences of CMR, according to thorax planes. (A) Coronal, (B) Sagittal and (C) Axial. (C) Planning of the long-axis two-chamber localizer plane, which includes the left atrium (LA) and the left ventricle (LV). (D) Long-axis two-chamber localizer and the planning of the long-axis four-chamber localizer. (E) Long-axis four-chamber localizer and the short-axis planning. (F) Long-axis two-chamber localizer and the short-axis planning. (G) Short axis, images from the heart base to its apex.

segmental and functional analysis of the LV. Based on this principle, we consider that it is important to have four planes, that is, the four-chamber plane (Figure 2B), the LVOT plane (three chambers - Figure 2C) and the two-chamber long-axis planes (Figure 2D and 2E). The four-chamber plane will cover the segments associated with the anterolateral and inferoseptal wall from the base to the apex of the LV. The outflow tract plane will cover the segments associated with the anteroseptal and inferolateral wall from the base to the apex of the LV. The two-chamber long axes will mainly cover the anterior and inferior walls from the base to the apex of the LV, but they will also help in the segmental transition planes, as the anteroseptal and anterior planes or the anterior and the anterolateral planes, which will facilitate the segmental analysis of the myocardial contractility and the study of the 17 segments of the LV. It is important to learn how to identify the planes, because one of the two-chamber long axes will have the liver below it and the lung above it (Figure 2D) and the other one will have the pulmonary artery above it and the stomach below it (Figure 2E).

In the literature, some groups prefer to have only three long axes (two chambers, three chambers or four chambers), but according to what was described above and due to observation in daily practice, we know that the four-plane planning yields greater diagnostic accuracy.

### RV study

With the short basal axis, two types of planning are possible: a four-chamber scan (Figure 3A), which follows the radial

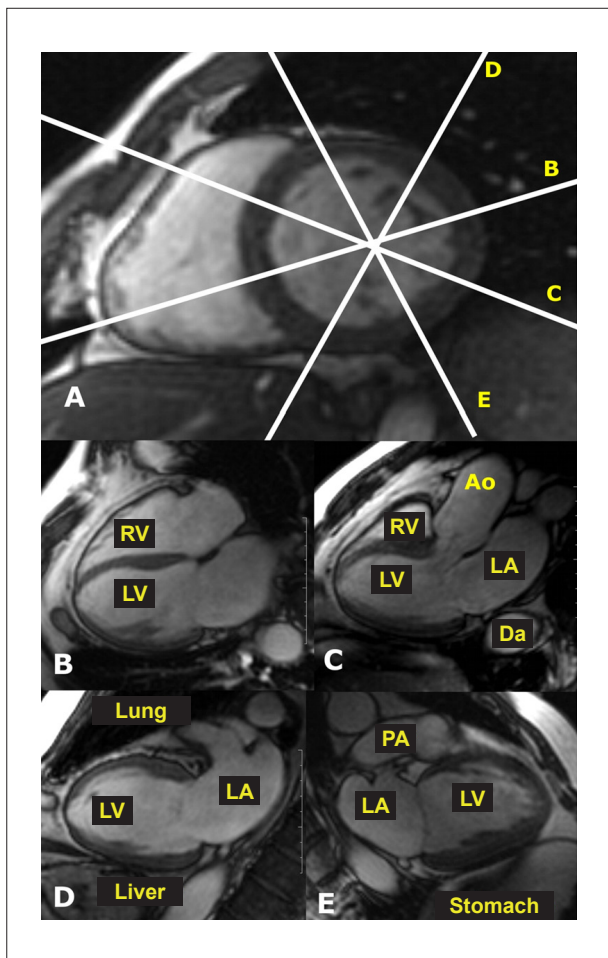
four-chamber axis, but which covers the entire RV all the way to the outflow tract (RVOT); and another one that may be performed in an oblique way in the RV itself for the complete RVOT study (Figure 3B). Another possible approach is the use of the four-chamber type itself for covering the RV and the RA, allowing us to view of the two-chamber long-axis plan to the right (Figure 3C). This last acquisition will provide us with a plane known as long-axis of the RV, in which we will be able to study the tricuspid plane and the RVOT (Figure 3D). With these planes, we will be able to prepare specific studies for the RVOT and the pulmonary artery (Figure 3E - RVOT in the sagittal plane; Figure 3F - aortopulmonary plane).

### Aortic valve plane

Although the CMR has a better spatial resolution than the echocardiogram (ECHO) - a method that has a better temporal resolution -, it has images with greater limitation in the functional valve approach, which may, in many cases, help in the complete non-invasive study of the valves and large vessels.

We start with the basal short axis (Figure 4A), after identification of the LVOT, in which we prescribe a plane along this segment. The image acquired is considered to be the three-chamber view or plane of the LVOT (Figure 4B), in which we will study the LA, the mitral valve, the LV, the aortic valve, the aortic root and a segment of the RV. In this plane, we can prescribe an axis that covers the LVOT and the aorta (Figure 4B), which will show an oblique coronal plane under

## Review Article



**Figure 2** - Planning of long axes (radial). (A) Basal short axis, first image of the heart base in the short axis after the outflow tract. Line B is the planning of the true four-chamber long axis. Line C is the planning of the three-chamber or LV outflow tract plane. Line D is the planning of the true two-chamber long axis, where we can observe, next to the inferior (lower) wall, the liver and next to the anterolateral basal segment, the lung. Line E is the planning of the true two-chamber long axis, where we can see, next to the basal inferolateral segment, the stomach and next to the anterior wall, the pulmonary artery. (B) True long axis four chamber. (C) LV outflow tract or three chamber. (D) Two chamber long axis. (E) Two chamber long axis. RV - right ventricle; LV - left ventricle; Ao - Aorta; LA - left atrium; DA - Descending Aorta; PA - pulmonary artery.

the aortic valve (Figure 4C). After preparing these planes with the complete coverage of the aortic valve, there is the need for a true perpendicular plane over the valve, which may be accomplished in Cine-MRI or in PC (phase contrast technique - Figures 4B to 4D show the prescription planes for the cross-sectional slice of the aortic valve in Cine-MRI). Echo gradient images allow studying the valve morphology and coaptation study, in addition to the study of the flow through the valve (Figure 4E - systole and Figure 4F - diastole, in a short axis of the aortic valve: phase contrast images are not shown).

### Mitral valve plane

Like in the case of the aortic valve, the study of the mitral valve is important, mainly to measure the regurgitation volume. Starting at the basal short axis (Figure 5B), always being careful

not to involve the aorta root (Figure 5A - dotted blue plane), we prescribe the four-chamber plane (Figure 5C). In this step, it is important to identify the aorta root so that the four-chamber plane will not include, due to a prescription error, the aorta root image, as this would impair the analysis of the basal septum. With the true four-chamber plane (Figure 5C) and the three-chamber plane (Figure 5D), we can draw up planes that are tangential to the mitral valve, making it easy to study its entire circumference during the closing (Figure 5E) and opening (Figure 5F) of the valve.

### Planes of tricuspid and pulmonary valves

Through the long axis that covers the RV and the RA (Figure 6A) or through the four-chamber plane (Figure 6B), we can draw planes that are tangential to the tricuspid valve, which will facilitate the study, in the axial and tangential plane, in the opening (Figure 6C) and closing (Figure 6D) of the valve. By using the RVOT planes, which may be the sagittal oblique plane (Figure 6E) or the coronal oblique plane (Figure 6F), it is possible to prescribe the tangential planes in the pulmonary valve, making it easier to study the valve circumference during the diastole (Figure 6G) and during the systole (Figure 6H). The PC study, right above the aortic valve and right above the pulmonary valve, provides us with information about the speed of the flow, of the flow through the pulmonary valves, and through the systemic flow, aortic valve. This can reveal the ratio of pulmonary systolic volume to systemic systolic volume ( $Q_p/Q_s$ ). The normal value is close to 1. When there is a left-to-right shunt, the pulmonary systolic volume increases, as well as the  $Q_p/Q_s$  ratio.

### Coronary planes

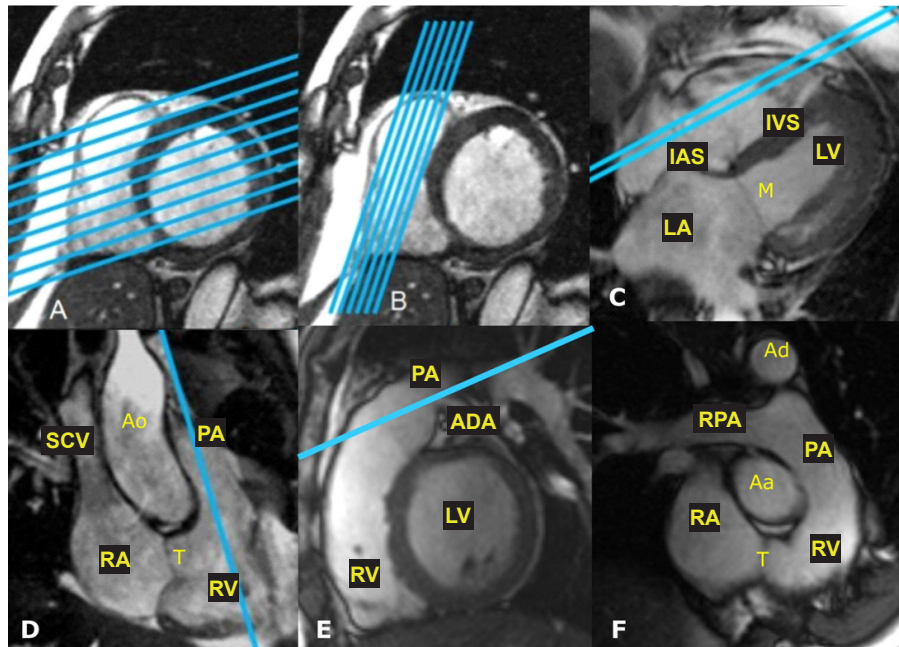
This is a specific purpose concerning the CMR development, but it still requires other studies and application of advanced technology. Therefore, it is partially impossible to adopt it in the current clinical practice. With the development of new techniques and the arrival of new devices in the market, specialized centers can already employ such method to study the coronary artery disease (CAD).

There has been an important revolution in multi-detector computed tomography devices, but they still have large doses of radiation. That is why there is still a lot of concern about the need to use reduction systems that will keep the quality of the angiographic image. It is important to remember that the coronary angiotomography is already well established as a major CAD exclusion method in clinical practice.

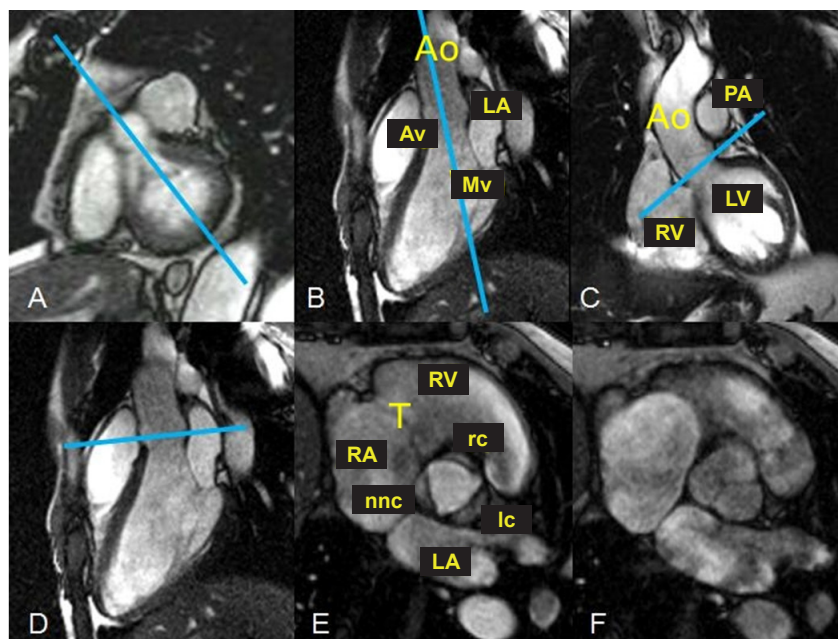
With the focus on a non-invasive study, in which it may be possible to do the exam without venous contrast, we can characterize the real potential of magnetic resonance.

We must say that we and other authors<sup>17</sup> are of the opinion that it is not possible to use the technique on a daily basis as a routine practice, although there is consensus that, in the very near future, the magnetic resonance will overcome its limitations and will reach technical maturity, and there will be a learning curve that is enough to justify its use on a routine basis.

We usually conduct the study with a patient breathing and without venous contrast, but there are breath-holding and gadolinium infusion techniques. With the patient breathing,

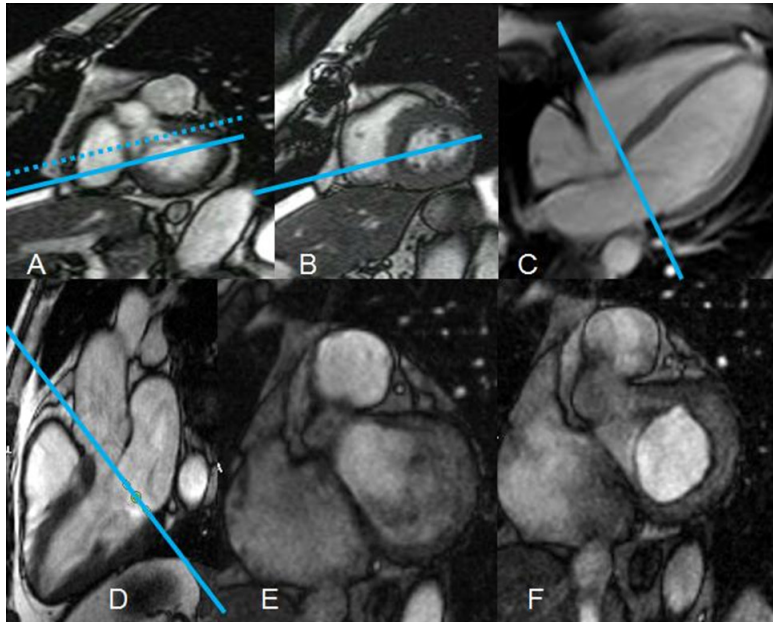


**Figure 3** - Planning of the complete right ventricle study. (A) Short basal axis and planning of the four-chamber scan plane. (B) Basal short axis and planning of the RV outflow tract plane. (C) Four-chamber long axis and planning of RV outflow tract plane. (D) Two-chamber long axis of the RV, study of the RV inflow tract and outflow tract. Planning of the RV outflow tract plane in the short axis. (E) Short axis, RV outflow tract. Planning of the pulmonary study and the RV outflow tract. (F) Pulmonary artery branch plane. IAS - interatrial septum; IVS - interventricular septum; LV - left ventricle; M - mitral valve; LA - left atrium; SCV - superior cava vein; RA - right atrium; T - tricuspid valve; RV - right ventricle; PA - Pulmonary artery branch; ADA - anterior descending coronary artery; Aa - ascending aorta; Da - descending aorta; RPA - right pulmonary artery.

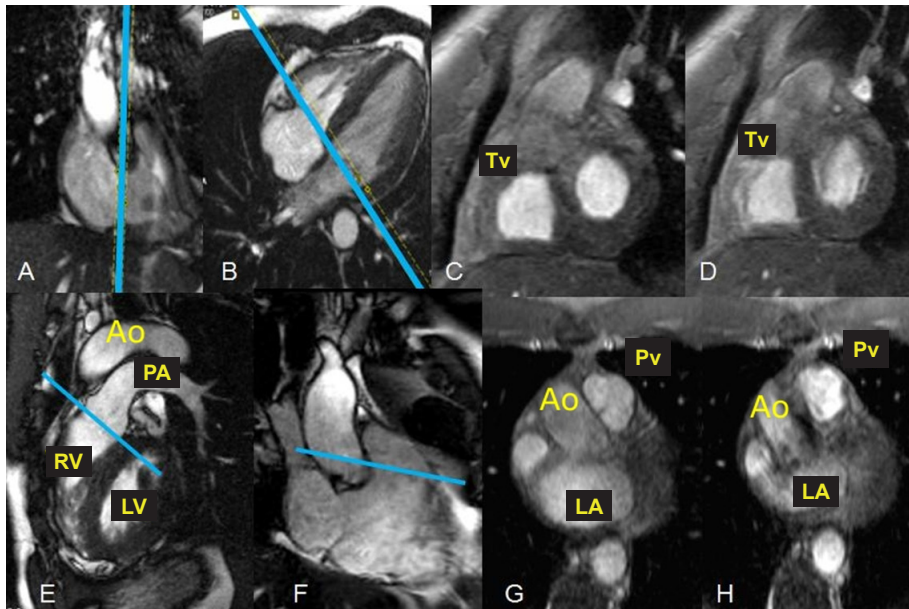


**Figure 4** - Study of the aortic valve. (A) Basal short axis with the LV outflow tract and planning of the three-chamber or outflow tract plane. (B) Three-chamber or outflow tract plane with the perpendicular planning of the ascending aorta. (C) True coronal plane of the ascending aorta and the correct planning for studying the aortic valve. (D) Three-chamber or outflow tract plane with incorrect planning for studying the aortic valve. (E) Open aortic valve. (F) Closed aortic valve. RA - right atrium; RV - right ventricle; LA - left atrium; T - tricuspid valve; ncc - non-coronary cusp; rc - right cusp; lc - left cusp; Av - aortic valve; Mv - mitral valve; Ao - aorta; PA - pulmonary aorta.

## Review Article



**Figure 5** - Study of the mitral valve. (A) Basal short axis with the LV outflow tract. Dotted line, wrong plane for planning the true four-chamber plane. Full line, right plane for planning the true four-chamber plane. (B) Basal short axis, first image after the LV outflow tract with the correct planning for the true four-chamber plane. (C) True four-chamber and planning tangential to the mitral valve. (D) Three-chamber or LV outflow tract and the planning tangential to the mitral valve. (E) Closed mitral valve. (F) Open mitral valve.



**Figure 6** - Study of the tricuspid valve and pulmonary valve. (A) Long axis of RV with tangential planning of the tricuspid valve. (B) Four chambers with tangential planning in the tricuspid valve. (C) Open tricuspid valve. (D) Closed tricuspid valve. (E) RV outflow tract and tangential planning of the pulmonary valve. (F) Long axis of the RV with tangential planning of the pulmonary valve. (G) Closed pulmonary valve. (H) Open pulmonary valve. Tv - tricuspid valve; RV - right ventricle; LV - left ventricle; PA - pulmonary aorta; Ao - Aorta; LA - left atrium; Pv - pulmonary valve.

it is necessary to use the navigator placed on the apex of the right diaphragm dome so as to remove the respiratory artifacts.

We will always need to use the ECHO and the fixed time delay after the R wave, which must be set to mid-diastole, the phase in which the coronary artery is full and there is less flow.

In the present work, we show a 3D volume of the whole heart, acquired by the navigation technique with free breathing, conducted at *Hospital Universitário Clementino Fraga Filho*, of Federal University of Rio de Janeiro (HUCFF-UFRJ), and its coronary curve reconstructions (branch of the anterior descending artery and right coronary artery - Figure 7).

### Segmentation of left ventricle and coronary territories

Due to a recommendation from image and cardiology societies, we standardized the myocardial segmentation study among the various heart imaging methods, as seen in the article of Cerqueira et al<sup>18</sup>.

The left ventricle is subdivided into 17 segments and it may be represented by the bulls-eye chart or polar map (Figure 8A). In this representation, we find three slice planes: basal, medial and apical. The basal one will represent the segments from 1 to 6, which are, respectively, the basal anterior, basal anteroseptal, basal inferoseptal, basal inferior, basal inferolateral and basal anterolateral. The medial one will represent the segments from 7 to 12, which are, respectively, the mid anterior, mid anteroseptal, mid inferoseptal, mid inferior, mid inferolateral and mid anterolateral. The apical plane will be represented by four segments only, from 13 to 16, which are, respectively, the apical anterior, the apical septal, the apical inferior and the apical lateral. Segment 17 is the apex, which is studied only in the long axes of the LV.

Modern devices allow studying the coronary arteries in a non-invasive way. This makes the CMR the only complete method and without ionizing radiation that permits you to analyze the heart in three dimensions, allowing the individualized study of coronary arteries, muscles and functions.

In addition, we established a relationship between the coronary territories and the LV segments. We can see in Figure 8B that segments 1, 2, 7, 8, 13, 14 and 17 are associated with

the anterior descending coronary artery (ADA). Segments 3, 4 and 10 are associated with the right coronary artery (RCA). Segments 9 and 15 may be irrigated by RCA or ADA. Segments 5 and 11 may be irrigated by the circumflex coronary artery (Cx) or by the RCA. And segments 6, 12 and 16 will be irrigated by Cx or by ADA (Figure 8B). Such segment is in accordance with the most frequent dominance standards and it is only a guide for the real coronary distribution, which may be individualized, in case we can obtain the information about the coronary tree anatomy, which is possible if we use specific equipment, as we have shown.

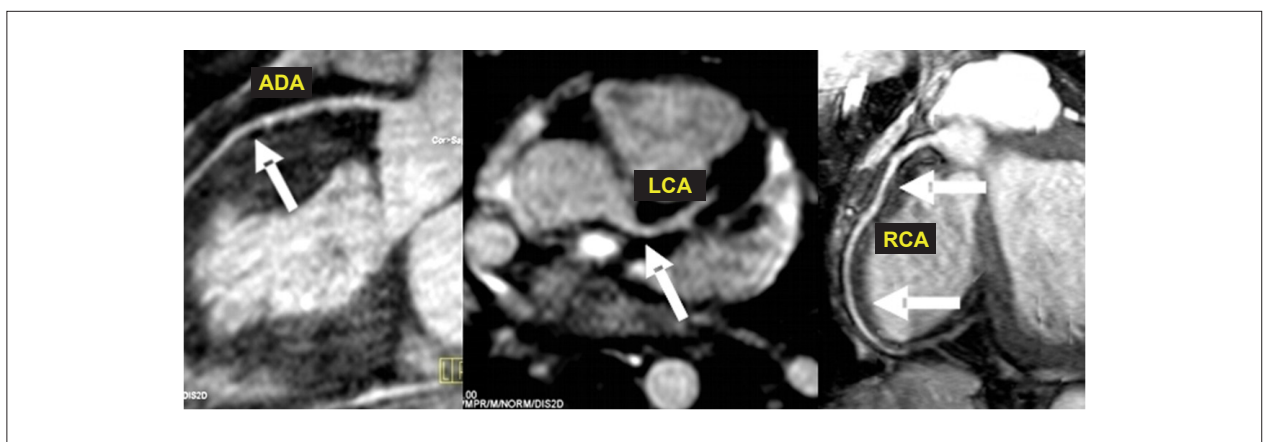
### How is the exam done?

As the study with pharmacological stress is the most complex and most complete study protocol, and the one that involves most steps of the simplest exams, we will discuss it in detail.

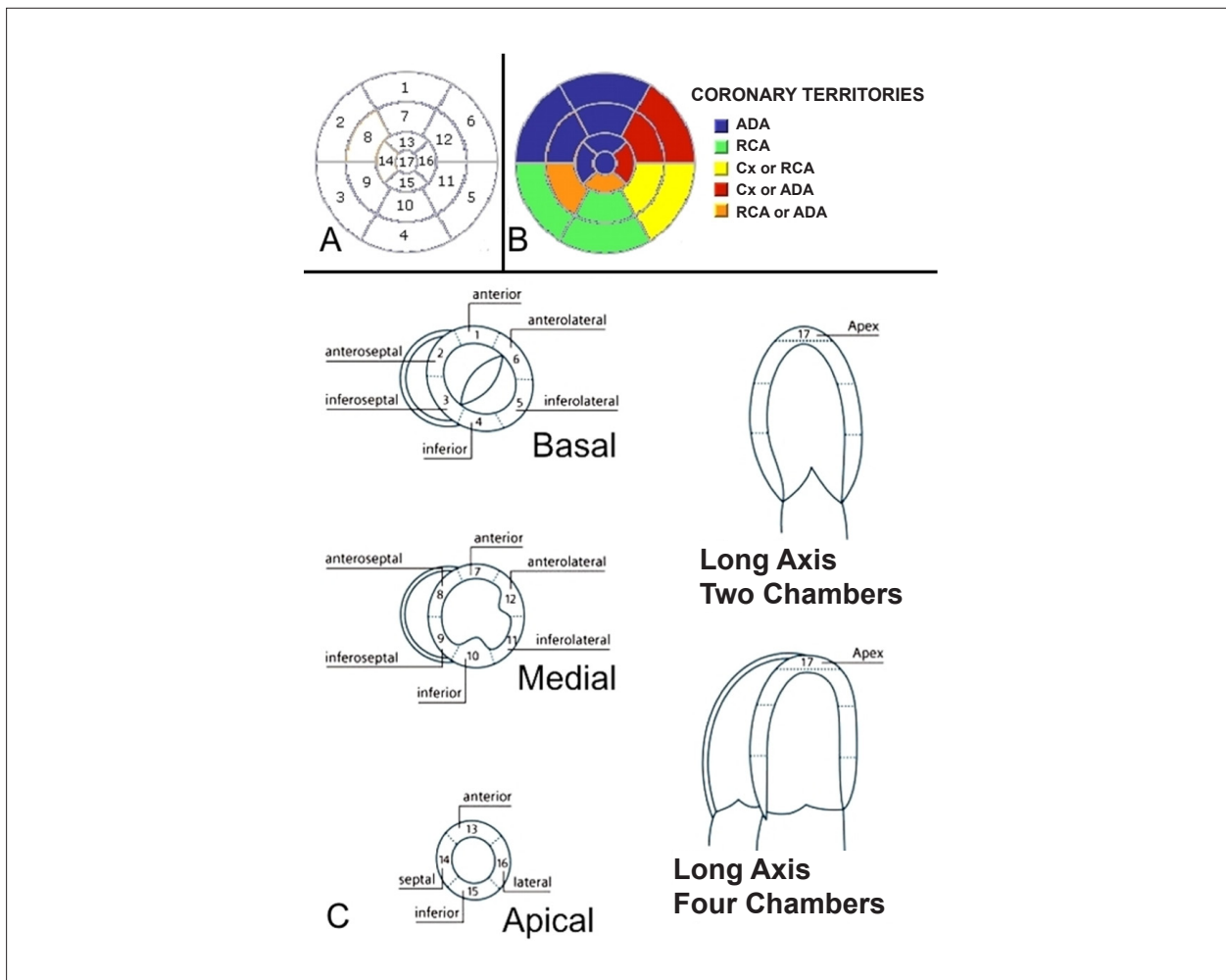
Strictly speaking, the exam has 8 steps. With the correct training and better integration of the support team (technicians, scheduling, reception, nursing and medical staff), their length of time may be reduced. Nowadays, it may take from 30 to 50 minutes to do the exam, depending on the steps that will be described below.

The first step starts on the day the exam is scheduled and it will have great influence on the exam. As it is a heart study, there is a different emotional characteristic, present in patients that will have the exam. So, with the proper guidance and preparation, patients understand the procedure better, feel less anxious and cooperate more on the day of the exam. The most important recommendation has to do with the patients' diet, mainly to have them refrain from ingesting caffeine at least 24 hours before the exam. It is important to highlight that the exam is not contraindicated for patients with coronary stents, biological or metallic valve prostheses, aortic endoprostheses and sternum sutures.

The second step is the pre-exam and it happens on the same day as the exam. This step may take from 10 to 15 minutes, and it includes collecting information about the reasons why that person is taking that exam. It also includes



**Figure 7** - MRI Coronary angiography. ADA - anterior descending coronary artery; LCA - left coronary artery branch; RCA - right coronary artery. Exam performed in the magnetic resonance imaging service of Hospital Clementino Fraga Filho of Federal University of Rio de Janeiro.



**Figure 8** - Left ventricle segmentation. (A) Polar map with the LV segments. (B) Polar map with the correlation between the LV segments and the possible coronary territories. (C) Left ventricle in the basal short, medial and apical axes and in the long axes, of two and four chambers, demonstrating the correct relationship of the segments.

a basal electrocardiogram (ECG) basal and the person's blood pressure, height, weight and heart rate are measured. At this point, the patient must be trained and guided to follow the correct breath-holding procedure. The patient must enter the equipment with a venous puncture, preferably in the right antecubital vein with a large-gauged Jelco, for the infusion of the paramagnetic contrast agent (gadolinium). The time for accomplishing this step does not influence the test time, because the procedure can be done outside of the magnetic resonance device.

The third step may take around 10 minutes and it is restricted to the making sure that the patient's position is correct, and fastening the cardiac and respiratory monitoring apparatuses. There will be the processing of images to locate the heart axis and the Cine-MRI of short axis at rest.

The fourth step may take around 6 minutes and it is completed after the patient is injected with Dipyridamole (0.56 mg/kg) for 4 minutes. At peak, it is possible to obtain the images of perfusion under stress with gadolinium (0.05 - 0.1 mmol/kg at the infusion speed of 4 to 5 ml/sec).

The fifth step may last around 5 minutes and it refers specifically to the study of the myocardial contraction and Cine-MRI during the pharmacological stress.

The sixth step may last about 5 minutes and it is performed with the infusion of Aminophylline for two minutes to reverse the vasodilator effect (Dipyridamole). At this point, the studies in Cine-MRI in long-axis planes are conducted.

The seventh step may take about 5 minutes and it is restricted to the study of perfusion at rest with a new injection of gadolinium (0.05 - 0.1 mmol/kg at the infusion speed of 4 to 5 ml/sec).

The eighth step can be completed in 10 minutes - from 5 to 15 minutes after the last infusion of gadolinium -, when the long and short-axes of the LV are acquired with the late myocardial enhancement technique (Figure 9) for assessing cases of fibrosis or heart attacks (Figure 10).

When all steps are completed, the device use time will be around 30 to 50 minutes, but the entire process needs to be organized from the date on which the appointment is scheduled until when the patient enters the device.

The time for the quantitative analysis of the exam may be from 30 to 40 minutes, with the use of the appropriate software and a full workstation, in order for all measures and analyses to be correctly used. The quantitative analysis of myocardial ischemia and the feasibility analysis take only a few seconds, allowing the early handling of the patient's case.

### Final considerations

We have demonstrated that the cardiac magnetic resonance exam represents a great increase in the service quality and provides essential clinical information to patients and their assistant doctors. It is important to emphasize that the CMR's main advantage are the quality and the technological improvement, with a direct clinical benefit to patients due to accurate and well-structured diagnoses.

Professionals in charge of cardiac magnetic resonance exams must have extensive knowledge of anatomy, physiology, physiopathology and the different study tools offered by the CMR to run the tests, because not knowing one of such steps

may significantly reduce the method's diagnostic capacity.

Finally, this article has demonstrated, in a simple and objective way, the slice planes used by CMR in the routine, explaining to clinicians whether or not (and how) each one of them can be reproduced and how they must be acquired. We also tried to show professionals involved with the method the classic images of the cardiac magnetic resonance.

### Potential Conflict of Interest

No potential conflict of interest relevant to this article was reported.

### Sources of Funding

There were no external funding sources for this study.

### Study Association

This study is not associated with any post-graduation program.

### References

1. Kim RJ, Fieno DS, Parrish TB, Harris K, Chen EL, Simonetti O, et al. Relationship of MRI delayed contrast enhancement to irreversible injury, infarct age, and contractile function. *Circulation*. 1999; 100: 1992-2002.
2. Sociedade Brasileira de Cardiologia. I Diretriz de ressonância e tomografia cardiovascular. *Arq Bras Cardiol*. 2006; 87: e48-e59.
3. Mahrholdt H, Goedecke C, Wagner A, Meinhardt G, Athanasiadis A, Vogelsberg H, et al. Cardiovascular magnetic resonance assessment of human myocarditis: a comparison to histology and molecular pathology. *Circulation*. 2004; 109: 1250-8.
4. Cury RC, Cattani CAM, Gabure LAG, Racy DJ, de Gois JM, Siebert U, et al. Diagnostic performance of stress perfusion and delayed-enhancement MR imaging in patients with coronary artery disease. *Radiology*. 2006; 240: 39-45.
5. Schwitler J, Wacker CM, van Rossum AC, Lombardi M, Al-Saadi N, Ahlstrom H, et al. MR-IMPACT: comparison of perfusion-cardiac magnetic resonance with single-photon emission computed tomography for the detection of coronary artery disease in a multicentre, multivendor, randomized trial. *Eur Heart J*. 2008; 29: 480-9.
6. Bezerra LB, Marchiori E, Pontes PV. Avaliação da função cardíaca por ressonância magnética com sequências em equilíbrio estável: segmentadas x tempo real. *Radiol Bras*. 2006; 39 (5): 333-9.
7. Barkhausen J, Ruehm SG, Goyen M, Buck T, Laub G, Debatin JF. MR evaluation of ventricular function: true fast imaging with steady-state precession versus fast low-angle shot cine MR imaging – feasibility study. *Radiology*. 2001; 219: 264-9.
8. Barkhausen J, Goyen M, Ruhm SG, Eggebrecht H, Debatin JF, Ladd ME. Assessment of ventricular function with single breath-hold real-time steady-state free precession cine MR imaging. *AJR Am J Roentgenol*. 2001; 178: 731-5.
9. Miller S, Simonetti OP, Carr J, Kramer U, Finn JP. MR imaging of the heart with cine true fast imaging with steady-state precession: influence of spatial and temporal resolutions on left ventricular functional parameters. *Radiology*. 2002; 223: 263-9.
10. Nacif MS, Oliveira Junior AC, Moreira DM, Nagano MR, Luz JHM, Martins MS, et al. Qual o seu diagnóstico?. *Radiol Bras*. 2007; 40 (4): 11-3.
11. Nacif MS, Saad ED, Camanho LEM, Ferreira FAC, Costa IP, Oliveira Jr AC. Qual o seu diagnóstico?. *Radiol Bras*. 2007; 40 (6): 9-12.
12. Nacif MS, Santos AASMD, Barros Filho CM, Sales LC, Souza VP, Carvalho ACP. Qual o seu diagnóstico?. *Radiol Bras*. 2007; 40 (5): 9-12.
13. Nacif MS, Oliveira Jr AC, Moreira DM, Nagano MR, Luz JHM, Dutra da Silva PR, et al. Qual o seu diagnóstico?. *Radiol Bras*. 2007; 40 (2): 7-9.
14. Nacif MS, Oliveira Jr AC, Moreira DM, Nagano MR, Luz JHM, Dutra da Silva PR, et al. Qual o seu diagnóstico?. *Radiol Bras*. 2007; 40 (1): 7-9.
15. Nacif MS, Oliveira Jr AC, Moreira DM, Nagano MR, Luz JHM, Dutra da Silva PR, et al. Qual o seu diagnóstico?. *Radiol Bras*. 2006; 39 (5): 5-7.
16. Nacif MS, Oliveira Jr AC, Moreira DM, Nagano MR, Luz JHM, Dutra da Silva PR, et al. Qual o seu diagnóstico?. *Radiol Bras*. 2006; 39 (6): 9-12.
17. Loureiro R, Favaro D, Baptista L. ABC da ressonância magnética cardíaca - Parte 2: perfusão, viabilidade e anatomia coronariana. *Rev Imagem*. 2003; 25 (1): 75-8.
18. Cerqueira MD, Weissman NJ, Dilsizian V, Jacobs AK, Kaul S, Laskey WK, et al. Standardized myocardial segmentation and nomenclature for tomographic imaging of the heart: a statement for healthcare professionals from the Cardiac Imaging Committee of the Council on Clinical Cardiology of the American Heart Association. *Circulation*. 2002; 105: 539-42.