

Secondary Hypertension to Rare Adrenal Gland Tumor

Joana Silva, Maria do Carmo Cachulo, António Leitão-Marques

Departamento de Cardiologia, Centro Hospitalar de Coimbra, Coimbra - Portugal

The ganglioneuroma is a tumor of the sympathetic nervous system and may be associated with hypersecretion of vasoactive substances responsible for various symptoms and signs such as hypertension. The authors report a case of ganglioneuroma and a literature review, focusing on the most important aspects of diagnosis and therapy. The patient had recurrent symptomatic hypertensive crises, having performed an imaging study that found a nodule in the right adrenal gland. As neuroblastic tumors are radiologically undistinguishable, the patient underwent excision, confirming the diagnosis by pathology analysis. This case demonstrates the clinical variability of ganglioneuroma, the usefulness of imaging and the importance of histological study.

Introduction

The ganglioneuroma (GN) is a rare and benign tumor of the sympathetic nervous system, originating from the neural crest, from undifferentiated cells. It is more often found in the chest, but it may also arise in the adrenal gland. It may vary clinically, but the most common associated symptoms are compression of surrounding structures which, in most cases, are detected in routine examinations.

Case report

The authors report the case of a female patient, 65 years of age, referred to a cardiology appointment due to hypertension with about 10 years of development, not controlled with a combination of antihypertensive drugs. The patient reported headaches, malaise, and facial flushing, symptoms that coincided with peak blood pressure (maximum of 190 mmHg systolic blood pressure (BP) and 120 mmHg of diastolic BP), which recently had worsened in terms of frequency and duration. She had been taking indapamide 1.5 mg (1×day), ramipril 5 mg (1×day) and hydrochlorothiazide 12.5 mg (1×day).

Keywords

Hypertension; ganglioneuroma; sympathetic nervous system/abnormalities.

As for personal history, she reported an appendectomy at age 17 and a laparoscopic cholecystectomy at age 53. She has never been a smoker or drinker. Her family history was irrelevant and was negative for endocrine neoplasia.

On physical examination, cushingoid characteristics or signs of virilization were not found. Cardiopulmonary auscultation was normal, as well as the remaining examination.

The electrocardiogram showed normal sinus rhythm and chest radiograph revealed no mediastinal widening, increased cardiothoracic ratio or pleuroparenchymal alterations. Abdominal ultrasound revealed "increased dimensions of the right adrenal gland (3.5 x 2cm) of heterogeneous echotexture, outlining some calcifications and no other abnormalities." Then, the patient underwent abdominal computed tomography (CT) to clarify the abnormalities mentioned (Fig. 1), which confirmed the presence of a "nodular formation in the right adrenal gland, with microcalcifications of solid density with about 34 mm in diameter." Ambulatory blood pressure monitoring during 24h (ABPM) revealed maximum systolic BP of 160 mmHg and maximum diastolic BP of 90 mmHg with non-dipper pattern (Fig. 2). In laboratory tests, there was an increase in serum aldosterone (798 $\mu\text{mol/l}$, normal: 28 to 443 $\mu\text{mol/l}$) with serum renin, plasma metanephrines, cortisol, vanillylmandelic acid and ionogram within normal parameters (1st analytical determination performed).

She was admitted to the Cardiology Department to study the picture. During hospital admission, a new laboratory study was performed: serum aldosterone and renin, potassium and sodium in urine and serum, measurement of urinary vanillylmandelic acid, plasma and urine metanephrines, thyroid function, erythrocyte sedimentation rate, C-reactive protein, plasma and urinary cortisol. All of these tests proved to be within normal parameters. The echocardiogram showed abnormalities in left ventricular relaxation, with no other abnormalities (normal wall thickness and systolic function). Meta-iodobenzylguanidine scintigraphy (¹²³I-MIBG) revealed no overactive areas over adrenal glands.

During this period, the patient showed some blood pressure peaks associated with headache and malaise, despite therapy with four antihypertensive drugs (1.5 mg indapamide (1×day), 5 mg ramipril (1×day), 12.5 mg hydrochlorothiazide (1×day) and 6.25 mg carvedilol (2×day)).

As it was not possible to deliver a definitive diagnosis through imaging examinations, it was decided to excise the tumor, so the patient underwent laparoscopic unilateral adrenalectomy. The procedure took place without significant complications (there was a transient peak blood pressure during the excision of the adrenal gland).

Mailing address: Joana Silva •

Rua da Chainça, 35, Carvalhais de Cima - 3040-690 - Coimbra - Portugal

E-mail: joanadelgadosilva@gmail.com

Manuscript received May 27, 2009; revised manuscript received December 04, 2009; accepted December 30, 2009.

From the standpoint of pathology, the surgical specimen was described macroscopically as a well-defined lesion, 4 cm in its largest diameter, whitish, with elastic consistency and fasciulate appearance; Schwann cells, ganglion cells, and fibrous and nervous tissue were microscopically detected, with no evidence of immature cells, atypia or necrosis. In view of these findings, the patient was diagnosed with a mature type of ganglioneuroma.

Upon six months of follow-up, the patient is asymptomatic and blood pressure controlled with two antihypertensive drugs (ramipril and hydrochlorothiazide). The patient underwent a new ABPM (Fig. 2) and abdominal CT (Fig. 1) which confirmed the success of the surgery and no recurrence.

Discussion

The ganglioneuroma belongs to the group of neuroblastic tumors, together with neuroblastoma (NB) and ganglioneuroblastomas (GNB). These are often primary

tumors progressing to mature tumors or, more rarely, they can differentiate from a NB or GNB (secondary ganglioneuroma) or from metastatic lesions. Association with other tumors may often occur, such as pheochromocytomas¹.

GN are tumors that arise from places where there is sympathetic nervous tissue, and its most frequent location is the posterior mediastinum, retroperitoneum, adrenal gland and neck, unusual places include the heart, bone and gut. They are more commonly found in women and may appear in all age groups. However, they are more often diagnosed in adolescents and young adults^{1,2}.

GN are usually asymptomatic, and are typically discovered in routine examinations. Predominant signs and symptoms associated are abdominal pain, cough, dyspnoea and palpation of an abdominal mass. These tumors are often functional and can secrete various active substances (catecholamines, vasoactive intestinal polypeptide, among others) leading to a typical clinical picture: hypertension,

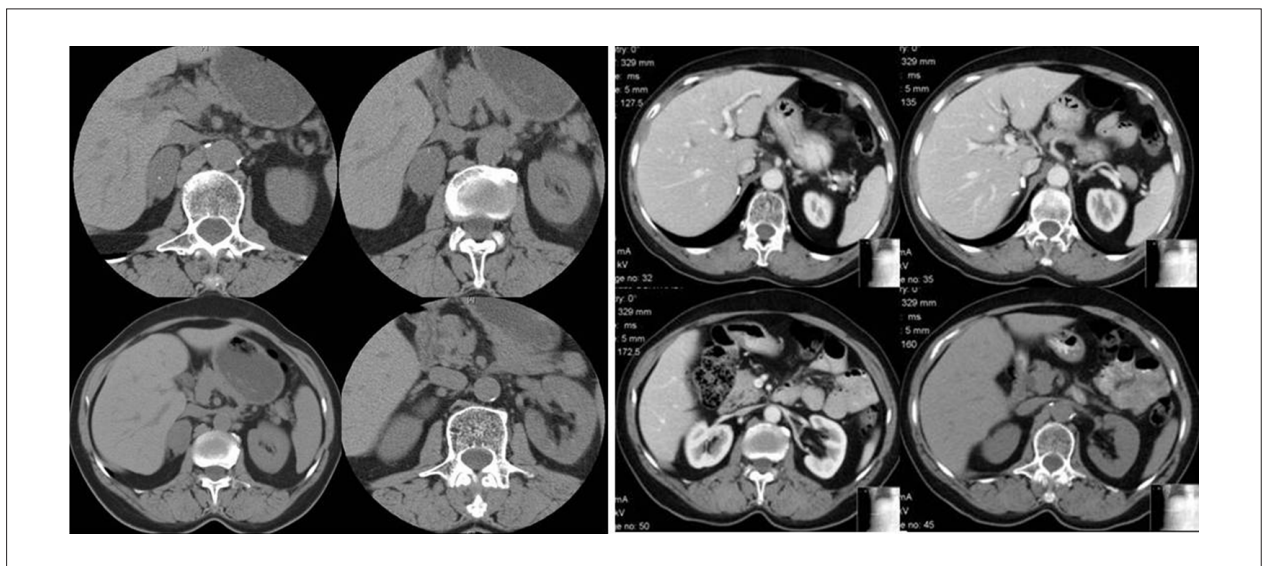


Figure 1 - Abdominal CT: formation in the right adrenal gland, with discrete calcifications (on the left) and absence of recurrence six months after surgery (on the right).

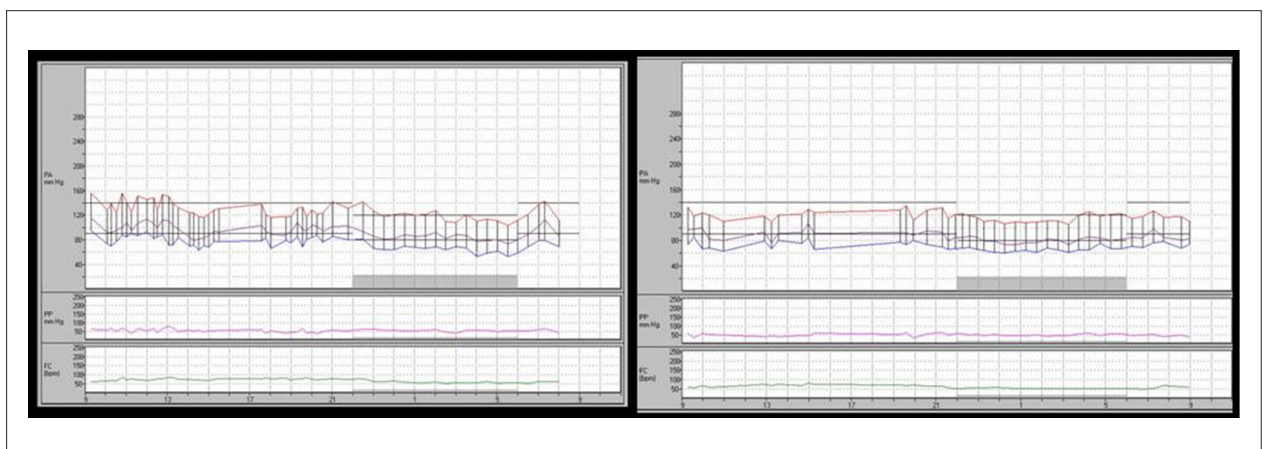


Figure 2 - ABPM (24 h): pre-surgery (on the left) and six months after the surgery (on the right).

Case Report

facial flushing, diarrhea and virilization²⁻⁴. Metastases are rare and are often bone or liver metastases.

Computed tomography and magnetic resonance imaging are baseline diagnosis methods¹. However, only one histopathological examination can confirm the diagnosis of ganglioneuroma and to distinguish it from its malignant relatives (neuroblastoma and ganglioneuroblastoma)⁵. GN are tumors composed of mature Schwann cells, ganglion cells, fibrous tissue and nervous tissue, not containing neuroblasts. The three tumors are radiologically indistinguishable but the presence of metastases is suggestive of malignancy. Pathologically, the GN are well-distinguished tumors with well-defined limits, containing a pseudocapsule, often with areas of calcification. When the location is retroperitoneal or adrenal, discrete calcifications may occur in 42% to 60% of the cases; usually growing in the vicinities of blood vessels, vascular invasion or compression is rare¹.

Radin et al studied nine cases of ganglioneuroma; imaging characterization revealed a mass with regular borders, well-defined, which may be surrounded by blood vessels without compromising its lumen. Evaluation by CT revealed a homogeneous mass, often with calcifications⁶.

Just like the GNB and NB, GN may accumulate meta-iodobenzyl-guanidine (MIBG), an analogue of catecholamines used to identify tumors that produce catecholamines such as pheochromocytoma, carcinoid tumors and medullary thyroid carcinoma. GN are tumors that typically have little or no metabolic activity, and MIBG uptake does not distinguish the different histologic types (particularly the ¹³¹I-MIBG⁷). Georger et al, in an analysis of 49 patients with primary ganglioneuroma, reported that 57% of tumors had detectable uptake of MIBG, even those too small, and 39% of patients had increased serum levels of catecholamines⁸.

Treatment depends on various factors like lesion size, picture of endocrine dysfunction and presence of metastases. In most cases, a complete surgical resection allows analyzing the specimen and determining a diagnosis. An analysis conducted by Hayes et al⁷ revealed that these tumors are consistent with a prolonged disease-free survival even when excision is not possible⁷. In rare cases, tumor recurrence may arise. Clinical and imaging follow-up for long periods are important measures.

In our case, the final diagnosis was a mature ganglioneuroma compatible with intermittent secretion of catecholamines. Therapy with multiple antihypertensive drugs may lead to false negative results for the secretion of catecholamines and their metabolites, which may also affect the uptake of MIBG. The surgery, which consisted of a complete excision of the tumor, had a single complication, which was a transient peak blood pressure. In addition, it was healing and led to the disappearance of hypertensive crises and associated symptoms. The clinical and radiological follow-up upon six months revealed no recurrence of the mass or evidence of metastases.

Potential Conflict of Interest

No potential conflict of interest relevant to this article was reported.

Sources of Funding

There were no external funding sources for this study.

Study Association

This study is not associated with any post-graduation program.

References

1. Jedynek AR, Schwartz RA, Lebovitz Y. Ganglioneuroma and ganglioneuroblastoma: follow-up (on line). [Accessed in 2009 Dec. 10]. Available from <http://emedicine.medscape.com/article/340723-followup>
2. Singh D, Singh A, Prabhakar BR, Arora R, Jain S, Hara GS, et al. Ganglioneuroma of the adrenal gland. *Indian J Surg.* 2003; 65: 436-8.
3. Koch CA, Brouwers FM, Rosenblatt K, Burman KD, Davis MM, Vortmeyer AO, et al. Adrenal ganglioneuroma in a patient presenting with severe hypertension and diarrhea. *Endocrine Relat Cancer.* 2003; 10: 99-107.
4. Suárez-Peñaranda JM, Gómez-Otero I, Muñoz JJ, Pedreira-Pérez M. Muerte cardiaca asociada a ganglioneuroma suprarrenal. *Rev Esp Cardiol.* 2008; 61(5):545-52.
5. Gupta R, Dinda AK. Ganglioneuroma of the adrenal gland: a rare case. *Indian J Pathol Microbiol.* 2007; 50 (4): 782-4.
6. Radin R, David CL, Goldfarb H, Francis IR. Adrenal and extra-adrenal retroperitoneal ganglioneuroma: imaging findings in 13 adults. *Radiology.* 1997; 202 (3): 703-7.
7. Hayes FA, Green AA, Rao BN. Clinical manifestations of ganglioneuroma. *Cancer.* 1989; 63 (6): 1211-4.
8. Georger B, Hero B, Harms D, Grebe J, Scheidhauer K, Berthold F. Metabolic activity and clinical features of primary ganglioneuromas. *Cancer.* 2001; 91 (10): 1905-13.