

## Multislice Coronary Angiotomography in the Assessment of Coronary Artery Anomalous Origin

Daniel Rocha Rabelo, Márcio Vinicius Lins Barros, Maria do Carmo Pereira Nunes, Cristiane Carneiro C. Oliveira, Maria Helena Albernaz Siqueira

Hospital Mater Dei - Belo Horizonte, MG, Brazil

### Abstract

**Background:** Anomalous origin of coronary arteries is a relatively rare entity, which may show different clinical forms and develop an adverse outcome. Multislice coronary angiotomography has gained importance in daily clinical practice, representing an important patient assessment method with great potential in the anatomical evaluation of these arteries.

**Objective:** This study aimed to describe angiotomographic findings and evolution of patients with anomalous origin of coronary arteries.

**Methods:** From January 2008 to March 2011 404 patients were evaluated consecutively, who had been referred for coronary angiotomography for several reasons, with a mean follow-up of 21 months.

**Results:** Nine patients (2.2%) had anomalous origin of coronary arteries, of which four had an anomalous origin of the Circumflex (Cx) artery in the Right Coronary Artery (RCA), two had anomalous origin of the RCA (one originating from the Cx and one in the left coronary sinus), a patient with single coronary trunk (anterior descending and Cx out of the left coronary sinus), one had anomalous left main coronary artery trajectory between the aorta and pulmonary artery and one patient with left coronary trunk originating from the right coronary sinus. Of the evaluated patients, one received an implantable cardioverter-defibrillator; one died due to sudden death during hospitalization; and the others showed no complications.

**Conclusion:** The multislice coronary angiotomography represents minimally invasive assessment method that allows detecting the origin, course and termination of anomalous coronary arteries with excellent accuracy, allowing the correct diagnosis and aiding therapeutic planning. (Arq Bras Cardiol 2012;98(3):266-272)

**Keywords:** Heart defects, congenital; coronary disease; coronary angiography; coronary vessels; angiotomography.

### Introduction

The normal anatomy of coronary arteries can be summarized as described by James in 1961, as the presence of two arterial orifices located in a central position in the left and right aortic sinus of Valsalva, close to the free border of the coronary cusps.

The anomalous origin of coronary arteries (AOCA) is a relatively rare entity, and its incidence is estimated at about 1.5% of the general population<sup>1-6</sup>. The evolution of AOCA is highly variable and may be benign or have potentially severe outcomes, such as myocardial infarction and sudden death. Among the available diagnostic methods, multislice CT angiography of the coronary arteries has great potential in the anatomical evaluation of these arteries<sup>7</sup> (Figs. 1 and 2).

This study aims to describe the anatomic findings and evolution of patients with anomalous origin of coronary arteries detected by multislice CT angiography of the coronary arteries.

### Methods

From January 2008 to March 2011, all patients referred for coronary angiotomography were registered and followed (after receiving information and signing the informed consent form for study participation), totaling 404 patients. A 64-channel CT scanner was used (Aquilion, Toshiba Medical Company, Japan), and the images of the entire heart were acquired during apnea of 6 to 8 seconds, with intravenous infusion of 85 to 90 mL of iodinated contrast material (Iopamiron 350) in infusion pump flow of 5 mL/s. Contrast auto-detecting ROI was positioned in the descending aorta (150 HU) starting the image acquisition.

Patients with HR > 70 bpm and no contraindications received 5 mg intravenous metoprolol. Images were reconstructed with 0.4 mm slice interval and 0.3 mm slice thickness, with retrospective gating. All data were analyzed by physicians experienced in the method, using multiplanar reformatting and volume rendering technique for 3-D reconstruction.

**Mailing Address:** Daniel Rocha Rabelo •

Rua dos Timbiras, 1364 - Funcionários - 30140-060 - Belo Horizonte, MG, Brazil

E-mail: danielrabelo@cardiol.br

Manuscript received June 12, 2011; revised manuscript received August 23, 2011; accepted October 05, 2011.

The patients were followed by telephone or personal interview for a median of 21 months.

## Results

Of the 404 patients, nine (2.2%) were diagnosed with AOCA, with a mean age of  $50.4 \pm 20$  years, of which eight (88%) being males (Table 1).

These patients were referred to the angiot-TC for various reasons, such as chest pain (four patients), altered myocardial scintigraphy (three patients), syncope (one patient) and post-cardiorespiratory arrest (one patient).

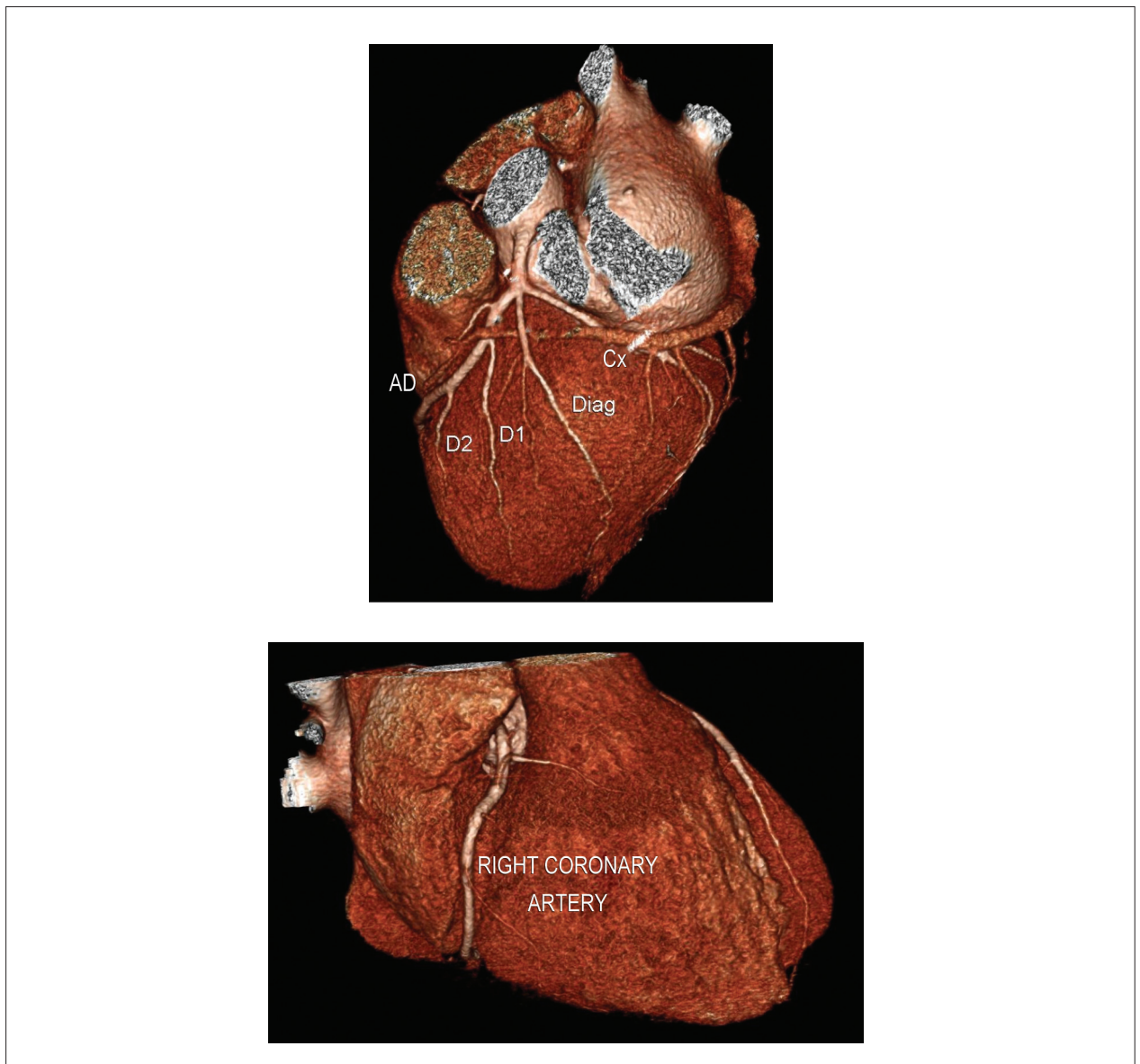Of the 404 patients, nine (2.2%) were diagnosed with AOCA, with a mean age of  $50.4 \pm 20$  years, of which eight (88%) were males (Table 1).

These patients were referred to the angio-CT for various reasons, such as chest pain (four patients), altered myocardial scintigraphy (three patients), syncope (one patient) and post-cardiorespiratory arrest (one patient).

Regarding the family history, four had a positive family history for coronary artery disease. There were no reports of other significant familial diseases.

The main angiotomographic findings were (Table 1):

- Four patients with anomalous origin of Cx in RCA (fig. 3);
- Two with anomalous origin of RCA (one with RCA origin in the Cx, and one with RCA origin in the left coronary sinus);

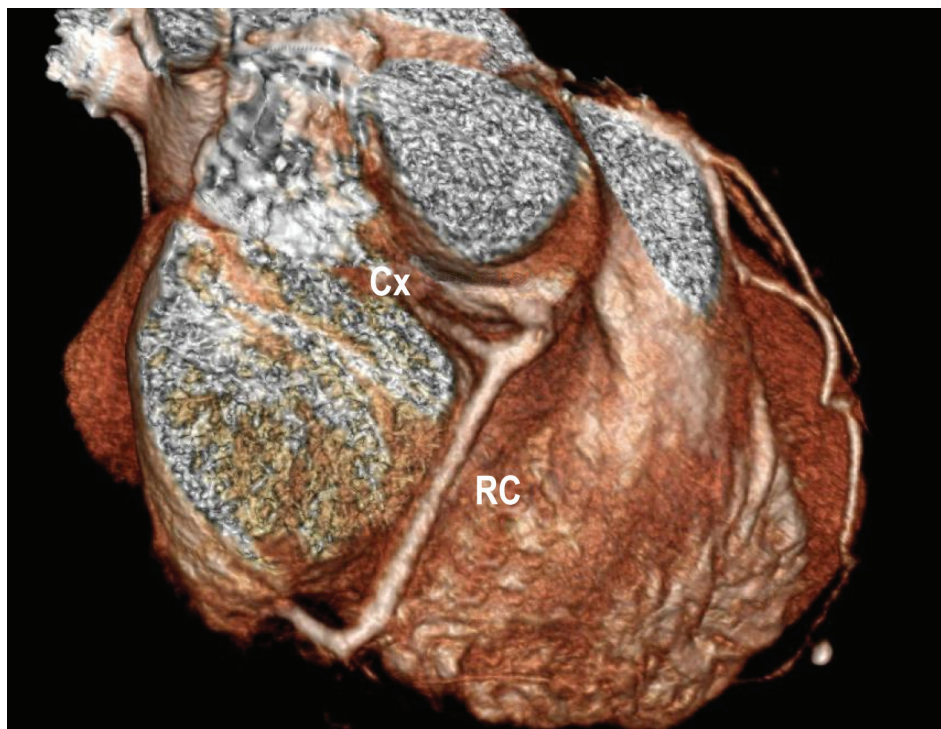


Figures 1 and 2 – Multislice angio-CT of the coronary arteries. Cx - Artery circumflex; AD - Anterior descending; D1 - First diagonal; D2 - Second diagonal; Diag. - Diagonal.

**Table 1 - Patients diagnosed with anomalous origin of coronary artery and their characteristics**

Age	Sex	Reason for referral	Anomaly	Evolution
58 years	M	Myocardial scintigraphy alteration	Cx originating from RCA	No complications
39 years	F	Post-CRA	Single left Coronary artery. Anomalous origin of the RCA in Cx with retroaortic trajectory with no luminal reduction by extrinsic compression.	ICD implant on 09/10/10.
76 years	M	Chest pain	Single artery: left coronary trunk	No complications.
58 years	M	Myocardial scintigraphy alteration	Left coronary trunk originating from right coronary sinus	No complications.
64 years	M	Chest pain	Cx originating from RCA, with retroaortic trajectory .	No complications.
34 years	M	Chest pain	RCA in left coronary sinus, with trajectory between the aorta and pulmonary trunk, with no extrinsic compression .	No complications.
72 years	M	Chest pain	Supernumerary pulmonary veins bilaterally. Anomalous origin of Cx in RCA.	Underwent CCA on 08/2010: Normal. No complications.
16 years	M	Syncope	Left coronary trunk with trajectory between the aorta and pulmonary trunk.	Sudden death in Jan/2011 during hospital admission.
48 years	M	Myocardial scintigraphy alteration	Cx originating from RCA, with retroaortic trajectory .	No complications.

*M – male; F – female; CRA – cardiorespiratory arrest; Cx – Circumflex artery; RCA – right coronary artery; ICD – implantable cardioverter defibrillator; CCA – catheter-coronary angiography.*



**Figure 3 – Multislice coronary angiogram showing circumflex artery originating from the right coronary artery. Cx - Artery circumflex; RC - Right coronary.**

- One patient with single coronary trunk (ADA and Cx originating from the left sinus (fig. 4));
- One patient had left coronary sinus originating from the right coronary sinus (fig. 5);
- One with anomalous trajectory of LCT between the aorta and pulmonary artery (fig. 6).

During evolution (Table 1), one patient received an implantable cardioverter defibrillator and progressed without complications, and another patient, who underwent the examination due to atypical chest pain, died due to sudden death during hospitalization, while awaiting surgery to correct the coronary anomaly.



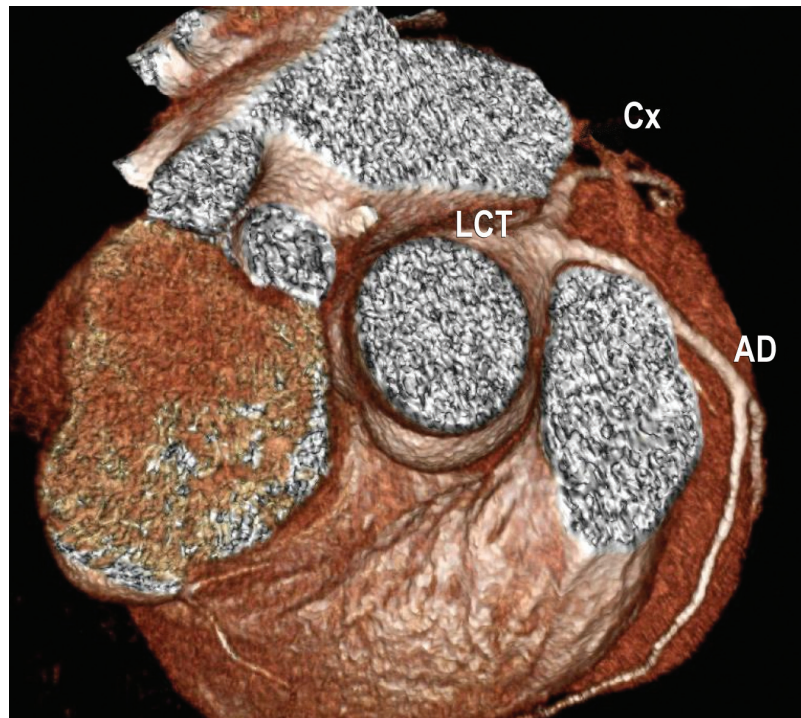


Figure 4 – Multislice coronary angiography demonstrating single coronary trunk. Cx - Artery circumflex; AD - Anterior descending; LCT - Left coronary trunk.

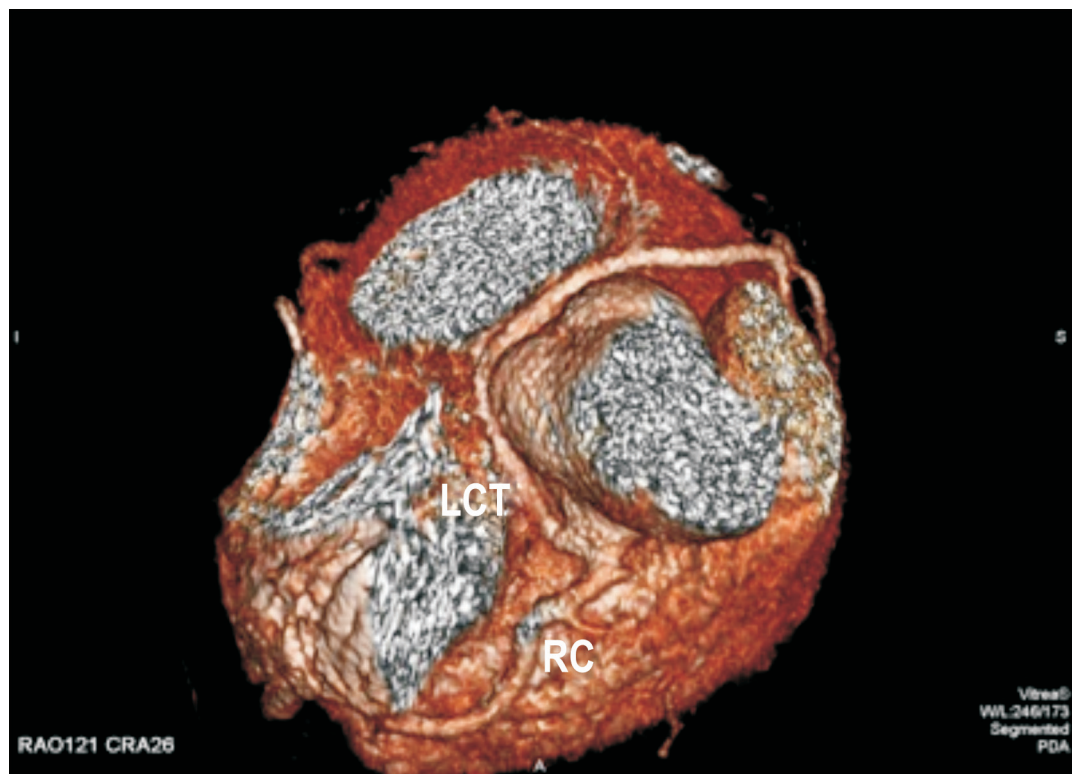


Figure 5 - Left coronary trunk originating from right coronary sinus. LCT - Left coronary trunk; RC - Right coronary.

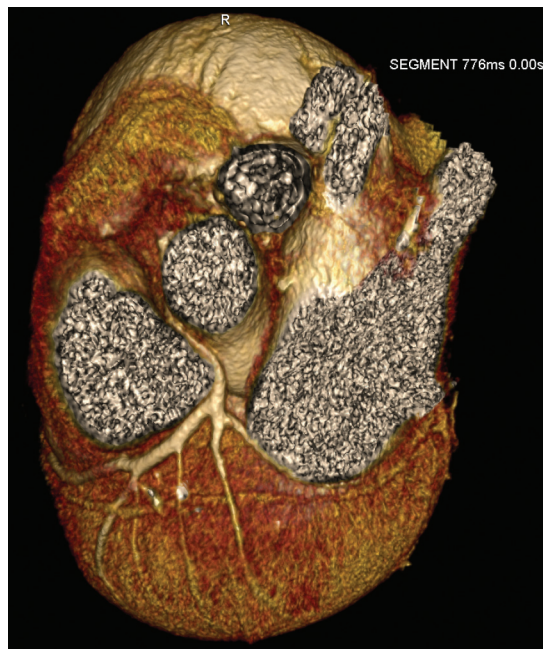

Figure 6 - Multislice coronary angiogram demonstrating anomalous trajectory of the left coronary trunk.

The other patients had no complications until the conclusion of the present study.

## Discussion

The normal coronary anatomy is characterized by two ostia located centrally in the right and left Valsalva sinuses, of which diameter should be equal to or greater than the diameter of the coronary artery that arises from it, being universally defined as follows<sup>8,9</sup>:

The coronary trunk originates from the left coronary sinus, usually below the sinotubular junction and is usually divided into the left anterior descending artery and circumflex artery; in 37% of individuals, the coronary trunk has a trifurcation in the left anterior descending artery (ADA), circumflex artery (Cx) and a median or intermediate branch. The latter usually supplies the free wall along the left lateral ventricular wall.

The anterior descending artery advances posteriorly to the pulmonary trunk on the anterior interventricular groove and has diagonal branches with a trajectory toward the anterolateral wall of the left ventricle.

The circumflex artery follows the atrioventricular groove posteriorly and varies in size and extension, depending on the degree of coronary dominance.

The Cx usually gives rise to one or three obtuse marginal branches, which supply the LV free wall. In only 1% of the population, the origins of ADA and Cx occur separately in the left coronary sinus<sup>10,11</sup>.

The right coronary artery (RCA) originates from the right coronary sinus and follows the right atrioventricular groove. Its first branch is the conal (or infundibular) artery, which

runs anteriorly, supplying the right ventricular outflow tract or infundibular region. In 50% of the population, the infundibular branch arises separately from the right coronary sinus<sup>7</sup>.

In 90% of the population, the RCA extends posteriorly and gives rise to the posterior descending artery, characterizing the “right dominance” system. In 10% of the population, the posterior descending artery arises from the circumflex artery and not from the RCA, characterizing the “left dominance” system.

Occasionally, a “balanced” system is present when the posterior surface is supplied by branches of both right and left arteries. Another branch of the RCA found in 59% of the individuals is the sinoatrial nodal artery, running posteriorly along the upper portion of the atrial septum and anterior wall of the right atrium, supplying the sinus node and right atrium. In 38% of individuals, this artery originates from the left coronary artery, and in 3% it originates from both arteries<sup>7</sup>.

Any alteration in this pattern must be considered as abnormal coronary anatomy, i.e., a coronary anomaly must be defined as any coronary pattern with a characteristic (number of ostia, proximal trajectory, distal bed, etc.) “rarely” found in the general population<sup>10</sup>.

This anomaly has low incidence in the general population, ranging from 0.3% to 6.6%. Alexander and Griffiths in 18,950 autopsies, found only 54 cases of anomalous origin of coronary arteries (0.3%); Angelini et al<sup>10</sup> conducted a study that included 1,950 consecutive cardiac catheterizations for the evaluation of coronary artery disease, finding an incidence of 5.6%, but these studies were limited due to patient enrollment selection and the absence of clear diagnostic criteria. Shi et al<sup>11</sup>, using

multislice coronary angiography, have shown an incidence of 6.6%. In the series presented in this study, we found an incidence of 2.2%

Coronary angiography is currently the most frequently used examination for the diagnosis of anomalous origin of coronary artery, but this method has limited use for this purpose due to its invasive characteristic and projection analysis.

64-Channel Multislice Computed Tomography is an excellent method in clinical practice for the detection of coronary artery anomalies, and it is a fast, minimally invasive (using only peripheral vein for contrast administration) and accurate method to detect the origin, course and termination of these vessels. Some authors have shown the superiority of the angio-CT of coronary arteries compared to conventional angiography to demonstrate ostial origin and the proximal trajectory of anomalous coronary arteries<sup>3,12,13</sup>.

Due to the very unspecific clinical picture, one should always bear in mind the possibility of AOCA, especially in young athletes, as it is a potentially lethal disease, being implicated as cause of chest pain, sudden death, heart failure, syncope, dyspnea, ventricular fibrillation and myocardial infarction<sup>10</sup>.

The origin and proximal trajectory of anomalous coronary arteries are the major predictors of severity<sup>14</sup>. Currently, it constitutes the second most common cause of sudden cardiovascular death in competitive athletes<sup>15</sup> and can also be the cause of heart failure and death in infants<sup>16,17</sup>.

Regarding patient evolution, we must take into account the limitations of the study, where there was a relatively short follow-up (mean of 21 months), and the possible anatomical variations.

Of the nine patients described in this study, four had the Cx artery originating from the RCA, being compatible with the literature that shows that the circumflex artery originating from the right coronary sinus or right coronary artery with a retroaortic trajectory, is the most common congenital anomaly of the coronary artery<sup>18,19</sup>.

This anomaly does not have important clinical significance, but it should certainly be considered before cardiac surgery.

We also observed a patient with single left coronary artery, where the origin of the RCA arises from the circumflex artery with retroaortic trajectory, and this patient was admitted to the service after a dramatic picture of cardiac arrest at home, having been resuscitated by the paramedic team. Even though they are the cause of myocardial ischemia, ischemia-inducing tests may be normal.

The anomalous origin of the left coronary artery from the right coronary sinus (in this series found in a patient with trajectory between the aorta and pulmonary trunk) can be associated with sudden death in 59% of cases, preceded by physical activity in 81% of the events<sup>10</sup>. This anomaly may present four trajectories: anterior to the pulmonary artery; posterior to the aorta; intraseptal between the aorta and pulmonary artery, and interarterial between the aorta and pulmonary artery<sup>20</sup>.

All subtypes of this anomaly have been associated with sudden death, but the interarterial variation, which is the most common pattern, has a stronger association with disastrous sequelae<sup>20-22</sup>.

We also diagnosed a patient with RCA origin in the left coronary sinus with a trajectory between the aorta and pulmonary trunk, without extrinsic compression. This patient was submitted to the examination due to chest pain, and an abnormal trajectory of the left coronary trunk was observed between the aorta and pulmonary artery. This patient died due to sudden death during hospitalization, while awaiting scheduled surgery for the correction of the coronary anomaly.

We also observed a patient with a single artery: left main coronary artery, where the left coronary sinus gave rise to the ADA and Cx; this is a rare anomaly with an incidence of 0.04% and may be associated with congenital heart defect (tetralogy of Fallot, transposition of great vessels, truncus arteriosus) in 40% of cases. The prognosis of this anomaly ranges from excellent (no decrease in survival), to guarded, according to their anatomical distribution, including the risk of sudden death, as 15% of patients develop severe heart disease before age 40. When coronary artery disease develops, the consequences are significant and the prognosis is severe if the obstruction is proximal, as the ostium is single and there is no possibility of collateral circulation.

The indication for revascularization should be considered in the presence of symptoms, even in the absence of coronary atherosclerosis, due to the considerable chance of acute myocardial infarction and sudden death.

According to current evidence, coronary segments with abnormal trajectory are more susceptible to atherosclerotic obstructive disease than normal segments in the same individual<sup>10,15</sup>.

The possibility of anomalous origin of coronary arteries must always be kept in mind in patients with chest pain, pre-syncope, syncope, or other nonspecific symptoms, especially when observed in young and athletic individuals, and if available, use multislice coronary angiography to attain a correct diagnosis and treatment of this entity which, if left untreated, may develop into an adverse event.

## Conclusion

AOCA is a relatively rare, potentially lethal entity if not diagnosed and treated early and can show different clinical forms and develop into adverse outcomes.

The angio-CT is minimally invasive diagnostic method that allows the detection of the origin, course and termination of anomalous coronary artery origin, allowing the correct diagnosis and aiding in treatment planning.

## Potential Conflict of Interest

No potential conflict of interest relevant to this article was reported.

## Sources of Funding

There were no external funding sources for this study.

## Study Association

This study is not associated with any post-graduation program.

## References

1. Hayashi JH, Abreu F<sup>o</sup> LM, Sumita MK, Takimura CK, Hotta VT, Forte AAC. Incidência de anomalias coronárias em hospital geral. *Rev Bras Cardiol Invas*. 2002;10(3):26-32.
2. Yamanaka O, Hobbs RE. Coronary artery anomalies in 126.595 patients undergoing coronary arteriography. *Cathet Cardiovasc Diagn*. 1990;21(1):28-40.
3. Baltaxe HA, Wixson D. The incidence of congenital anomalies of the coronary arteries in the adult population. *Radiology*. 1977;122(1):47-52.
4. Leberthson RR, Dinsmore RE, Bharati S, Rubenstein JJ, Caulfield J, Wheeler BO, et al. Aberrant coronary artery origin from the aorta: diagnosis and clinical significance. *Circulation*. 1974;50(4):774-9.
5. Engel HJ, Torres C, Page HL Jr. Major variations in anatomical origin of the coronary arteries: angiographic observations in 4.250 patients without associated congenital heart disease. *Cathet Cardiovasc Diagn*. 1975;1(2):157-69.
6. Chaitman BR, Lesperance J, Saltiel J, Bourassa MG. Clinical, angiographic and hemodynamic findings in patients with anomalous origin of the coronary arteries. *Circulation*. 1976;53(1):122-31.
7. Dawn B, Talley JD, Prince CR, Hoque A, Morris GT, Xenopoulos NP, et al. Two-dimensional and Doppler transesophageal echocardiographic delineation and flow characterization of anomalous coronary arteries in adults. *J Am Soc Echocardiogr*. 2003;16(12):1274-86.
8. Shi H, Aschoff AJ, Brambs HJ, Hoffmann MH. Multislice CT imaging of anomalous coronary arteries. *Eur Radiol*. 2004;14(12):2172-81.
9. Taylor AM, Thorne SA, Rubens MB, Jhooti P, Keegan J, Gatehouse PD, et al. Coronary artery imaging in grown up congenital heart disease: complementary role of magnetic resonance and X-ray coronary angiography. *Circulation*. 2000;101(14):1670-8.
10. Angelini P, Velasco JA, Flamm S. Coronary anomalies: incidence, pathophysiology, and clinical relevance. *Circulation*. 2002;105(20):2449-54.
11. Shi H, Aschoff AJ, Brambs HJ, Hoffmann MH. Multislice CT imaging of anomalous coronary arteries. *Eur Radiol*. 2004;14(12):2172-81.
12. Wollenek G, Damanig E, Salzer-Mufar U, Havel M, Wimmer M, Wolner E. Anomalous origin of the left coronary artery: a review of surgical management in 13 patients. *J Cardiovasc Surg*. 1993;34(5):399-405.
13. Wesselhoeft H, Fawcett JS, Johnson AL. Anomalous origin of the left coronary artery from the pulmonary trunk: its clinical spectrum, pathology and pathophysiology, based on review of 140 cases with seven further cases. *Circulation*. 1968;38(2):403-25.
14. Dawn B, Talley JD, Prince CR, Hoque A, Morris GT, Xenopoulos NP, et al. Two-dimensional and doppler transesophageal echocardiographic delineation and flow characterization of anomalous coronary arteries in adults. *J Am Soc Echocardiogr*. 2003;16(12):1274-86.
15. Maron BJ. Sudden death in young athletes. *N Engl J Med*. 2003;349(11):1064-75.
16. Oliveira SA, Snitcowsky R. Origem anômala da artéria coronária esquerda do tronco pulmonar. In: Macruz R, Snitcowsky R, eds. *Cardiologia pediátrica*. São Paulo: Sarvier; 1983. p. 508-43.
17. Takimura CH, Nakamoto A, Hotta VT, Campos MF, Málamó M, Otsubo R. Origem anômala da artéria coronária esquerda no tronco pulmonar. relato de um caso em adulto. *Arq Bras Cardiol*. 2002;78(3):309-14.
18. Kruskal JB, Hartnell GG. Nonatherosclerotic coronary artery disease: more than just stenosis. *Radiographics*. 1995;15(2):383-96.
19. Ropers D, Moshage W, Daniel WG, Jessl J, Gottwik M, Achenbach S. Visualization of coronary artery anomalies and their anatomic course by contrast-enhanced electron beam tomography and three-dimensional reconstruction. *Am J Cardiol*. 2001;87(2):193-7.
20. Ropers D, Gehling G, Pohle K, Maeffert R, Regenfus M, Moshage W, et al. Anomalous course of the left main or left anterior descending coronary artery originating from the right sinus of Valsalva: identification of four common variations by electron beam tomography. *Circulation*. 2002;105(6):e42-3.
21. Memisoglu E, Ropers D, Hobikoglu G, Tepe MS, Labovitz AJ. Usefulness of electron beam computed tomography for diagnosis of an anomalous origin of a coronary artery from the opposite sinus. *Am J Cardiol*. 2005;96(10):1452-5.
22. Kasprzak JD, Kratochwil D, Peruga JZ, Drozd J, Rafalska K, Religa W, et al. Coronary anomalies diagnosed with transesophageal echocardiography: complementary clinical value in adults. *Int J Card Imaging*. 1998;14(2):89-95.