

## Mitral Valve and Atrial Septal Defect Surgery - Minimally Invasive or Sternotomy Approach

Josué V. Castro Neto<sup>1</sup>, Emanuel Melo<sup>1</sup>, Juliana Fernandes<sup>1,2</sup>, Regina Gomes<sup>1,2</sup>, Caroline Freitas<sup>1</sup>, João Machado<sup>1</sup>, Francisco Martins<sup>1</sup>, Aloísio Barbosa<sup>1</sup>, Bernardo Oliveira<sup>1</sup>, Cesar Gondim<sup>1</sup>

INCONE - Instituto do Coração do Nordeste<sup>1</sup>, Fortaleza, CE; UNIFOR - Universidade de Fortaleza<sup>2</sup>, Fortaleza, CE – Brazil

### Abstract

**Background:** To decrease the surgical trauma in heart procedures, minimally invasive (MI) techniques were alternatively introduced.

**Objective:** To compare MI surgical access with median sternotomy (MS) for the treatment of mitral valve (MV) disease and atrial septal defect (ASD).

**Methods:** Forty patients underwent surgery for correction of MV disease or ASD. Patients were divided into group A (GA) (n=20), access by right minithoracotomy and video-assistance; and group B (GB) (n=20), access by full MS. Aortic cross-clamp and cardiopulmonary bypass time, intensive care unit (ICU) time, hospital stay and morbidity were compared in this prospective study.

**Results:** Fifteen patients were submitted to MV procedures and five to ASD corrections in each group. There were 9 mitral replacements (7 bioprosthetic and 2 mechanical) and 6 repairs in GA, and 10 (all bioprosthetic) and five in GB. The mean aortic cross-clamp and cardiopulmonary bypass time, in minutes, were  $65.1 \pm 29.3$  in GA and  $50.2 \pm 21.4$  in GB ( $p=0.074$ ); and  $91.8 \pm 35$  in GA and  $63.7 \pm 27.3$  in GB ( $p=0.008$ ). The mean ICU time, in hours, were  $51.7 \pm 16.3$  in GA and  $55.8 \pm 17.5$  in GB ( $p=0.45$ ). The in hospital stay, in days, were  $5.2 \pm 1$  in GA and  $6.4 \pm 1.5$  in GB ( $p=0.009$ ).

**Conclusion:** MI access for correction of the MV disease and ASD implicated in a longer cardiopulmonary bypass time for finalization of the main procedure, nevertheless it didn't affect patient's recuperation. MI treated patients were discharged earlier than sternotomy treated patients. (Arq Bras Cardiol 2012;99(2):681-687)

**Keywords:** Mitral valve / surgery; sternotomy; heart septal defects, atrial / surgery; surgical procedures, minimally invasive.

### Introduction

Mitral valve (MV) disease, especially of rheumatic etiology, has a significant incidence in Brazilian population<sup>1</sup>. In addition, due to limitations on health care access, atrial septal defect (ASD) frequently present between adults. These two diseases have a significant impact on cardiovascular care in our country.

Although the very early MV and septal defect surgery were performed by thoracotomy approaches, the traditional incision for surgical treatment of heart diseases has shifted to a complete median sternotomy (MS). It provides central cannulations and access to all heart chambers. Recent advances in surgical techniques and medical technologies, including videoscopic instruments, permitted the revival of right side surgical access by minithoracotomy-based approaches in selected cases<sup>2-5</sup>. Minithoracotomy seems to reduce surgical trauma, bleeding and it might be associated with a decrease in hospital stay.

Despite of growing application of minimally invasive (MI) cardiac surgery as a method for the treatment of those two conditions there are limited publications comparing this alternative to the standard MS based approach, especially in Brazil.

This study aims to compare the MS with a MI surgical technique in the treatment of MV disease and ASD in northeastern Brazilian adult population.

### Methods

Forty adult patients with MV disease or ASD were enrolled between October of 2008 and January of 2010 in this prospective interventional study approved by Institutional Review Board of the University of Fortaleza.

### Patient selection and grouping

Symptomatic patients presenting with MV disease or ASD were selected and, after informed consent, divided in two groups according to: the technique utilized for the access of the defect, pathoanatomical characteristics, the surgeon's decision following the cardiology societies guidelines.

Group A (GA) comprised twenty patients submitted to surgical correction with a right minithoracotomy and group B (GB) twenty patients submitted to MS.

**Mailing Address:** Josué V. Castro Neto •

Av. Santos Dumont, 5753/108, Papicu. Postal Code 60175-047, Fortaleza, CE – Brazil

E-mail: jvcn@cardiol.br, jvcn@uol.com.br

Manuscript received November 23, 2012; manuscript revised November 29, 2012; accepted February 28, 2012.

The variables considered were: cardiopulmonary bypass and aortic cross-clamp times, intensive care unit (ICU) stay time, hospitalization time and postoperative complications.

Exclusion criteria were: age greater than sixty years old, body mass index greater than 30 kg/m<sup>2</sup>, chronic obstructive lung disease, previous heart or thoracic interventions, renal failure, interstitial or inflammatory lung disease, thoracic deformities, mitral valve or aortic calcifications, systolic pulmonary pressure greater than 80 mmHg, coronary artery disease, severe tricuspid insufficiency, femoral vessel calcification, femoral artery smaller than 6 mm, inadequate femoral vessel puncture, moderate or severe aortic insufficiency and patient's consent withdraw at any moment.

### Operative technique

All surgical procedures were carried out by the same surgeon (JC). Patients were submitted to surgical interventions under general anesthesia and cardiopulmonary bypass with moderate hypothermia and cold crystalloid cardioplegic arrest.

Group A - Surgical access through a right minithoracotomy (5 cm).

The surgical procedure was performed through indirect vision offered by a 30° high definition camera mounted in a 5 mm optical system. Femoral arterial perfusion was achieved with a cannula adequate for the patient's body weight and introduced by direct puncture utilizing the Seldinger's technique. The vacuum assisted venous return with a single right femoral venous cannula could be associated or not with a right jugular venous cannula. Aortic occlusion was obtained with a transthoracic aortic cross-clamp. Operative field was cleared with a CO<sub>2</sub> blower at 2 l/min. Patients were monitored with transeophageal echocardiogram. Specific instruments for minimally invasive surgery were used.

Group B - Surgical access through a MS.

The arterial perfusion was obtained by direct cannulation of the ascending aorta. The systemic venous return was obtained with single direct atrial cannulation or two separate caval cannulas. The aortic occlusion was performed with a direct clamp. Usual techniques and instruments were applied for the procedure.

### Statistical analysis

Statistical analysis was performed with the Statistical Package for Social Science software for Windows®, version 18.0. The sample size was calculated assuming that the stay in intensive care unit and hospitalization would be reduced in the group with minithoracotomy. Twenty patients per arm of the study were to provide a power of 80% to the study.

The sample characterization was descriptively analyzed by median and standard deviation. Normal distribution was verified by Kolmogorov-Smirnov test and homogeneity of the variance was assured by the Levene's test. Student t test was used for comparisons of means of parametric data and U Mann-Whitney test was computed for nonparametric data. Continuous variables are summarized by mean ± standard deviation or by median and 15<sup>th</sup> and 85<sup>th</sup> percentiles,

consistent with ± 1 standard deviation. Categorical data are summarized by frequencies and percentages and compared by the z test for two proportions. Significance was attained at p<0.05.

### Results

Twenty-seven women (GA-n=11 and GB-n=16) and thirteen men (GA-n=9 and GB-n=4) were enrolled in this study. Patients were submitted to minithoracotomy (GA) or median sternotomy (GB) for correction of MV (GA-n=15 and GB-n=15) or ASD (GA-n=5 and GB-n=5).

Patients comprised in GA and GB had similar ages (GA= 37±11 y.o.; GB= 37±12 y.o.) (Table 1).

Procedures for mitral correction included 9 replacements (7 bioprosthetic and 2 mechanical) and 6 repairs in GA, and 10 bioprosthetic replacements and 5 repairs in GB.

Mitral repairs in GA consisted of 4 commissurotomies (associated with a papillarotomy in two of them) and 2 partial cuspid resections with annuloplasties (semirigid ring - 1 case and pericardial strip in other one). In GB, 4 commissurotomies (associated with a papillarotomy in one of them) and 1 focal cuspid resection with pericardial reconstruction. In addition to the mitral procedures were done 4 pulmonary vein isolations (box lesion – ultrasound energy), two in each group. In relation to ASD procedures there were 3 suture closure and 2 patch closure in GA and 2 suture closure and 3 patch closure in GB (Table 2).

The mean aortic cross-clamp times were 65.1 ± 29.3 minutes in GA and 50.2 ± 21.4 minutes in GB(p=0.074) (Figure 1). The mean cardiopulmonary bypass times were

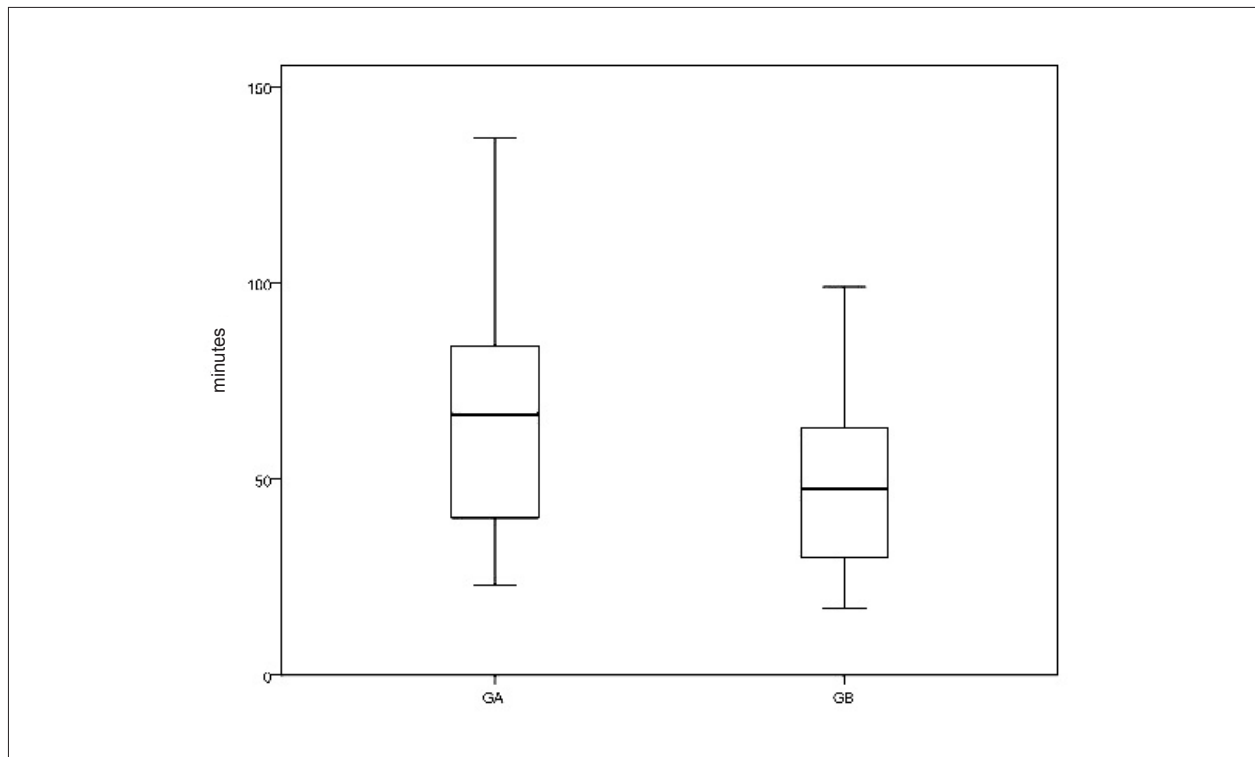
**Table 1 – Clinical variables from patients submitted to surgical correction through a right minithoracotomy (GA) or median sternotomy (GB)**

Characteristic	GA	GB	p
Female (%)	11/20 (55)	16/20 (80)	0.08
Age (y ;mean ± SD)	37 ± 11	37 ± 12	0.93
MV disease (%)	15/20 (75)	15/20 (75)	1
Stenosis (%)	6/15 (30)	6/15 (30)	1
Insufficiency (%)	1/15 (5)	6/15 (30)	0.08
Double lesion (%)	8/15 (40)	3/15 (15)	0.12
ASD (%)	5/20 (25)	5/20 (25)	1
NYHA functional class			
I (%)	1/20 (05)	0/20(0)	1
II (%)	10/20 (50)	9/20 (45)	0.75
III (%)	9/20 (45)	11/20 (55)	0.52
IV (%)	0/20(0)	0/20 (0)	1
AF (%)	4/20 (20)	2/20 (10)	0.66

MV: mitral valve; ASD: atrial septal defect; AF: atrial fibrillation; NYHA: New York Heart Association

**Table 2 – Operative variables from patients submitted to surgical correction through a right minithoracotomy (GA) or median sternotomy (GB)**

Procedures	GA (n = 20)		GB (n = 20)		p
	n	No. (%)	n	No. (%)	
Mitral replacement	20		20		
Bioprosthetic		7 (46,7%)		10 (66,7%)	0.25
Mechanical		2 (13,3%)		0 (0%)	0.48
Mitral Repair	20	6 (40%)	20	5 (33,3%)	1
Additional Procedures	20	2 (10%)	20	5 (25%)	0.4
Suture closure	20	3 (60%)	20	2 (40%)	1
Patch closure	20	2 (40%)	20	3 (60%)	1



**Figure 1 – Mean aortic cross-clamp time comparison between GA and GB [in minutes, 65.1 ± 29.3 in GA and 50.2 ± 21.4 in GB (p=0.074)]**

91.8 ± 35 minutes in GA and 63.7 ± 27.3 minutes in GB (p=0.008) (Figure 2).

The mean intensive care unit times were 51.7 ± 16.3 hours in GA and 55.8 ± 17.5 in GB (p=0.45) (Figure 3). The in hospital stay after the procedure were 5.2 ± 1 days in GA and 6.4 ± 1.5 in GB (p=0.009) (Figure 4).

There were no deaths, strokes or any major complications in group A or B. There was one new atrial fibrillation episode in group B that was pharmacologically reversed. One patient in group A referred transitory thigh paresthesia.

## Discussion

Median sternotomy has rapidly replaced the initial application of the right anterolateral thoracotomy for intracardiac surgical procedures<sup>6</sup> due to the avoidance of peripheral cannulation and because it is a universal incision for treatment of all types of cardiac diseases.

Videoscopic techniques have been progressively established as the preferential method of access for surgical procedures since its introduction in different specialties, including thoracic surgery<sup>7</sup>. Despite worldwide application<sup>8</sup>, there is limited experience with this type of approach for cardiovascular procedures in Brazil<sup>9,10</sup>.

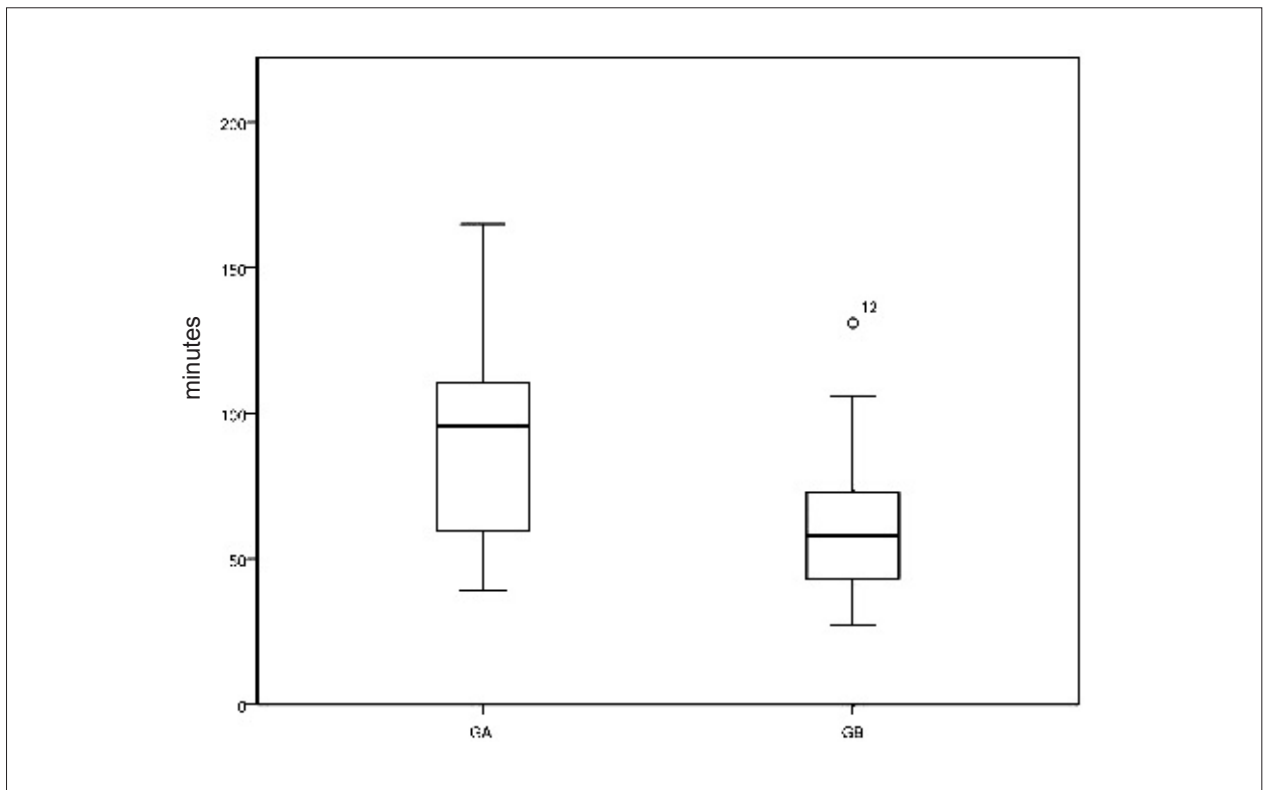


Figure 2 – Mean cardiopulmonary bypass time comparison between GA and GB [in minutes,  $91.8 \pm 35$  in GA and  $63.7 \pm 27.3$  in GB ( $p=0.008$ )]

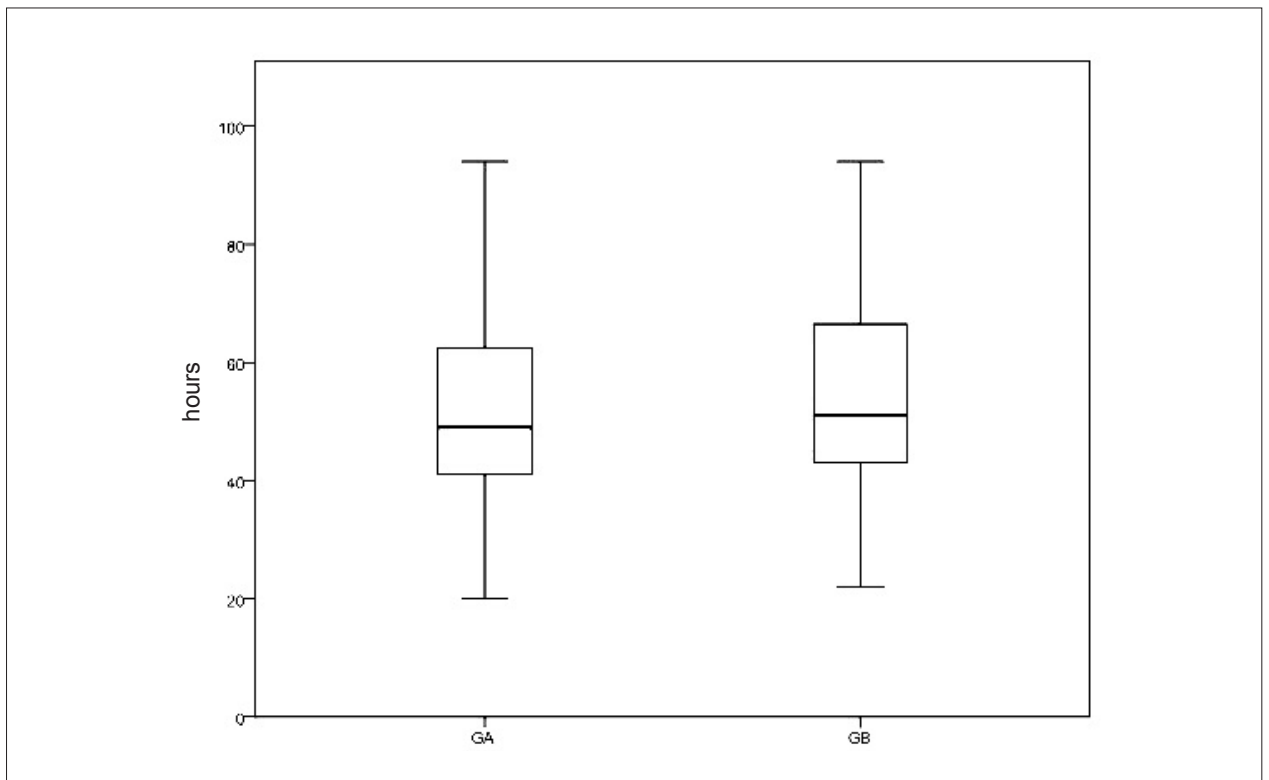


Figure 3 – Mean intensive care unit time comparison between GA and GB [in hours,  $51.7 \pm 16.3$  in GA and  $55.8 \pm 17.5$  in GB ( $p=0.45$ )]

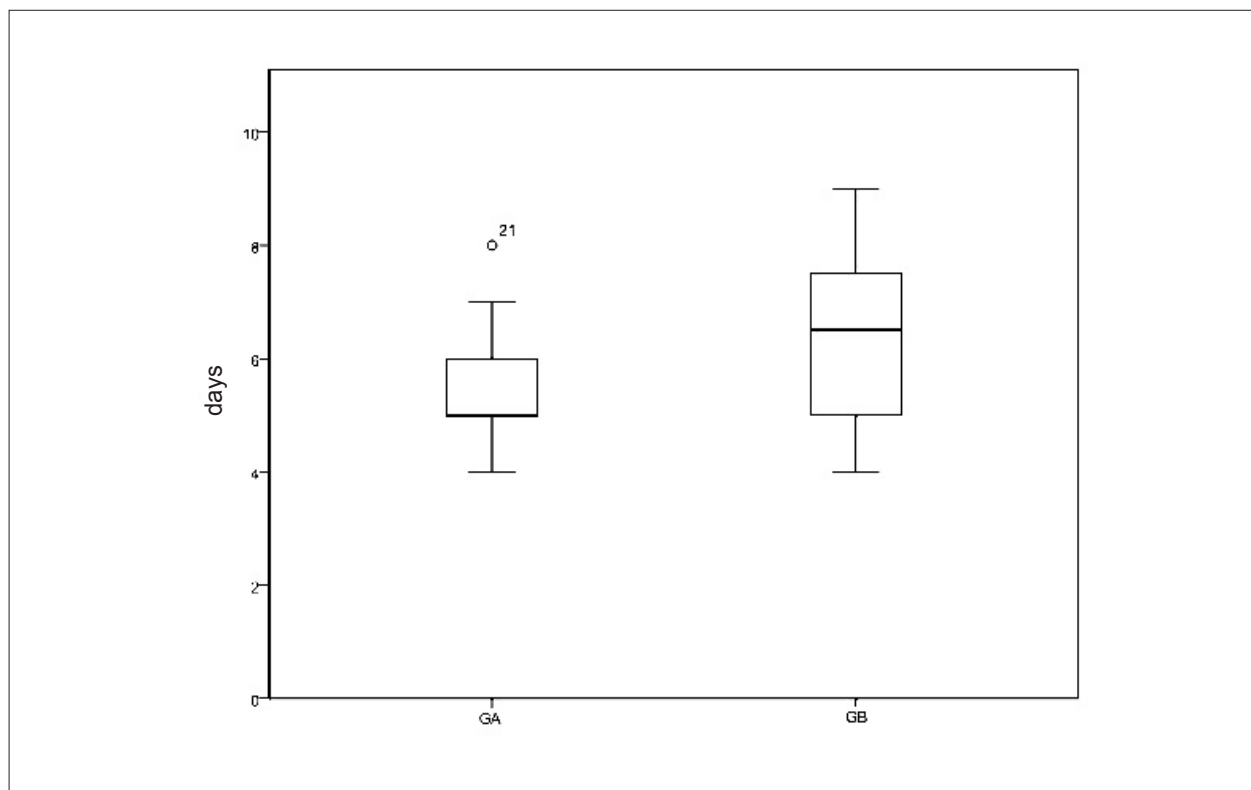


Figure 4 – Comparação das médias de tempo de hospitalização entre GA e GB [em dias,  $5,2 \pm 1$  em GA e  $6,4 \pm 1,5$  no GB ( $p = 0,009$ )]

Some reports compared video-assisted minithoracotomy and sternotomy as the method of accessing selected heart conditions<sup>11-15</sup>; nevertheless, this paper is the first comparison carried out in Brazil. In general, our results were similar to the previous reports, especially those related to a higher pump time and shorter length of stay in the hospital<sup>8</sup>. A recent meta-analysis enclosing different incisions, cannulations and aortic occlusions was not able to find differences in mortality between the MI and the sternotomy approach; however, the MI patients were found to be a lower risk group<sup>15</sup>.

Three large trials<sup>16-18</sup> reported the experience of more than a thousand MI mitral procedures yielding excellent rates of satisfactory mitral valve repairs. Rheumatic disease severely affects the mitral valve and it often transforms the repair in a challenge for the surgeon, despite of this we were able to repair six valves in GA. Most of the repairs were commissurotomies associated or not with pappillarotomies but resections and reconstructions associated with annuloplasties were also performed. The replacement of mitral valves with bioprosthetic substitutes was the elected method in seventeen patients from the entire cohort.

The quality of the surgical repair is a frequent concern regarding MI procedures. In the present study, the use of a MI procedure did not alter the treatment plan and all surgical repairs proposed were done. Thus, it should be inferred that the MI procedure did not impair the result of treatment in this extremely selected group of patients as indicated by a post-operative echocardiogram. Concordantly, a previous

report demonstrated that the rate and the success of mitral repair were not compromised by the use of less invasive operative approaches, even with robotic surgery<sup>19</sup>; which might be related to the selection of patient with favorable mitral anatomy towards minimally invasive procedures.

The traumatic consequence secondary to the sternotomy incision should be an additional core for discussion. The complete division of the sternal bone inherits the separation of the anterior limit of the thoracic gage, which for instance will provoke a process of consolidation. It is now clear that sternotomy will affect at least at a minimal level the pulmonary function after the procedure. One report<sup>20</sup> demonstrated a correlation between pain centered in the surgical site and reduction in forced expiratory volume in one second, peak expiratory flow and maximum inspiratory volume.

Sternotomy complications such as bone marrow and sternal wires bleeding, more dissection for exposure, infective and noninfective complications of sternal healing are eliminated with the limited right intercostal space approach. On the other hand, intercostal approach still means a small amount of muscle dissection, rib spreading and manipulation of long-shafted instruments in a two dimensional operative field<sup>21</sup>. None of the patients assigned to GA had complications at the submammary incision or at the site of femoral puncture. One patient in GA referred transitory thigh disesthesia. Pulmonary complications were not observed in either group of patients.

Duration of aortic cross-clamp and cardiopulmonary bypass times were longer in GA; however, significance was reached

exclusively for cardiopulmonary bypass time. Increase in the duration of aortic cross-clamp and cardiopulmonary bypass times is a common feature previously reported by other groups<sup>8,11-14,19</sup>. In the present study, the increased duration of extracorporeal circulation did not result in longer stay in ICU or longer hospitalization, but whether these findings care higher morbidity is yet to be evaluated through large prospective trials.

Minimally invasive treatment decreased patient's hospitalization. Actually, patients in GA were discharged from the hospital 1.2 days earlier than patients in GB. The decrease in hospital stay might indicate a faster recovery of the patients; however, time to resume daily activities should be considered an important marker of patients' recovery and a post-hospitalization follow up would elucidate whether the decrease in hospitalization duration means a faster recovery.

Minimally invasive cardiac surgery might be associated with permanent stroke<sup>8,15</sup>. Notwithstanding there were no injuries of the nervous system in this study, probably due to the strict criteria for selecting patients to be submitted to the minimally invasive procedure by our team. The possible association, in our view, of MI surgery to stroke events in those previous reports can be attributed to: i) the longer duration of extracorporeal circulation in elderly patients, ii) utilization of endoclamp, iii) performance of redo procedures on a fibrillating heart, and finally iv) de-airing maneuvers could be harmful and should be carefully performed.

Thoracoscopic procedures were initially appointed for the surgical occlusion of patent ductus arteriosus<sup>22</sup>. None of the patients participating in this study had a correction of patent ductus arteriosus, but the thoracoscopy was applied for the suture or plasty of ASD. This technique was an excellent

alternative for this purpose and there were no surgical complications associated; these findings are in agreement with a long-term evaluation of this type of procedure<sup>23</sup>.

Aside of the impact of sternotomy on patient's recovery, it might cause a psychosomatic impact in certain patients. This is a matter of debate between physicians, but the remaining scar might account for the genesis of post-traumatic stress disorders during convalescence<sup>24</sup>.

## Conclusion

Our data indicate that minimally invasive approach for the repair or replacement of mitral valve and correction of atrial septal defect is a safe procedure, when compared with sternotomy approach. Minimally invasive treated patients were discharged from the hospital earlier than median sternotomy treated patients, in spite of longer duration of cardiopulmonary bypass times.

## Potential Conflict of Interest

No potential conflict of interest relevant to this article was reported.

## Sources of Funding

There were no external funding sources for this study.

## Study Association

This study is not associated with any post-graduation program.

## References

- Barbosa PJ, Müller RE, Latado AL, Achutti AC, Ramos AI, Weksler C, et al. Sociedade Brasileira de Cardiologia / Sociedade Brasileira de Pediatria / Sociedade Brasileira de Reumatologia. Diretrizes brasileiras para o diagnóstico, tratamento e prevenção da febre reumática. *Arq Bras Cardiol*. 2009;93(3 supl.4):1-18.
- Lin PJ, Chang CH, Chu JJ, Liu HP, Tsai FC, Chu PH, et al. Video-assisted mitral valve operations. *Ann Thorac Surg*. 1996;61(6):1781-7.
- Chitwood WR Jr, Wixon CL, Elbeery JR, Moran JF, Chapman WH, Lust RM. Video-assisted minimally invasive mitral valve surgery. *J Thorac Cardiovasc Surg*. 1997;114(5):773-82.
- Loulmet DF, Carpentier A, Cho PW, Berrebi A, d'Attellis N, Austin CB, et al. Less invasive techniques for mitral valve surgery. *J Thorac Cardiovasc Surg*. 1998;115(4):772-9.
- Mohr FW, Falk V, Diegeler A, Walther T, van Son JA, Autschbach R. Minimally invasive port-access mitral valve surgery. *J Thorac Cardiovasc Surg*. 1998;115(3):567-76.
- Julian OC, Lopez-Belio M, Dye WS, Javid H, Grove WJ. The median sternal incision in intracardiac surgery with extracorporeal circulation: a general evaluation of its use in heart surgery. *Surgery*. 1957;42(4):753-61.
- Rocco G, Internullo E, Cassivi SD, Van Raemdonck D, Ferguson MK. The variability of practice in minimally invasive thoracic surgery for pulmonary resections. *Thorac Surg Clin*. 2008;18(3):235-47.
- Gammie JS, Zhao Y, Peterson ED, O'Brien SM, Rankin JS, Griffith BP. J. Maxwell Chamberlain Memorial Paper for adult cardiac surgery. Less-invasive mitral valve operations: trends and outcomes from the Society of Thoracic Surgeons Adult Cardiac Surgery Database. *Ann Thorac Surg*. 2010;90(5):1401-8.
- Jatene FB, Pêgo-Fernandes PM, Hayata AL, Arbulu HE, Stolf NA, de Oliveira SA, et al. VATS for complete dissection of LIMA in minimally invasive coronary artery bypass grafting. *Ann Thorac Surg*. 1997; 63(6 Suppl):S110-3.
- Poffo R, Pope RB, Selbach RA, Mokross CA, Fukuti F, da Silva Júnior I, et al. Video-assisted cardiac surgery: results from a pioneer project in Brazil. *Rev Bras Cir Cardiovasc*. 2009;24(3):318-26.
- Grossi EA, LaPietra A, Ribakove GH, Delianides J, Esposito R, Culliford AT, et al. Minimally invasive versus sternotomy approaches for mitral reconstruction: comparison of intermediate-term results. *J Thorac Cardiovasc Surg*. 2001;121(4):708-13.
- Svensson LG, Atik FA, Cosgrove DM, Blackstone EH, Rajeswaran J, Krishnaswamy G, et al. Minimally invasive versus conventional mitral valve surgery: a propensity-matched comparison. *J Thorac Cardiovasc Surg*. 2009;139(4):926-32.
- Suri RM, Schaff HV, Meyer SR, Hargrove WC 3<sup>rd</sup>. Thoracoscopic versus open mitral valve repair: a propensity score analysis of early outcomes. *Ann Thorac Surg*. 2009;88(4):1185-90.

14. Iribarne A, Russo MJ, Easterwood R, Hong KN, Yang J, Cheema FH, et al. Minimally invasive versus sternotomy approach for mitral valve surgery: a propensity analysis. *Ann Thorac Surg*. 2010;90(5):1471-8.
15. Modi P, Hassan A, Chitwood WR Jr. Minimally invasive mitral valve surgery: a systematic review and meta-analysis. *Eur J Cardiothorac Surg*. 2008;34(5):943-52.
16. Seeburger J, Borger MA, Falk V, Kuntze T, Czesla M, Walther T, et al. Minimal invasive mitral valve repair for mitral regurgitation: results of 1339 consecutive patients. *Eur J Cardiothorac Surg*. 2008;34(4):760-5.
17. Modi P, Rodriguez E, Hargrove WC 3rd, Hassan A, Szeto WY, Chitwood WR Jr. Minimally invasive video-assisted mitral valve surgery: a 12-year, 2-center experience in 1178 patients. *J Thorac Cardiovasc Surg*. 2009;137(6):1481-7.
18. Galloway AC, Schwartz CF, Ribakove GH, Crooke GA, Gogoladze G, Ursomanno P, et al. A decade of minimally invasive mitral repair: long-term outcomes. *Ann Thorac Surg*. 2009;88(4):1180-4.
19. Mihaljevic T, Jarret CM, Gillinov MA, Williams SJ, DeVilliers PA, Stewart WJ, et al. Robotic repair of posterior mitral valve prolapsed versus conventional approaches: potential realized. *J Thorac Cardiovasc Surg*. 2011;141(1):72-80.
20. Baumgarten MC, Garcia GK, Frantzeski MH, Giacomazzi CM, Lagni VB, Dias AS, et al. Pain and pulmonary function in patients submitted to heart surgery via sternotomy. *Rev Bras Cir Cardiovasc*. 2009;24(4):497-505.
21. Schroyers P, Wellens F, De Geest R, Degrieck I, Van Praet F, Vermeulen Y, et al. Minimally invasive video-assisted mitral valve surgery: our lessons after a 4-year experience. *Ann Thorac Surg*. 2001;72(3):S1050-4.
22. Laborde F, Noirhomme P, Karam J, Batisse A, Bourel P, Saint Maurice O. A new video-assisted thoracoscopic surgical technique for interruption of patient ductus arteriosus in infants and children. *J Thorac Cardiovasc Surg*. 1993;105(2):278-80.
23. Vistarini N, Aiello M, Mattiucci G, Alloni A, Cattadori B, Tinelli C, et al. Port-access minimally invasive surgery for atrial septal defects: a 10-year single-center experience in 166 patients. *J Thorac Cardiovasc Surg*. 2010;139(1):139-45.
24. Guliemos V, Eller M, Thiele S, Dill HM, Jost T, Tugtekin SM, et al. Influence of median sternotomy on the psychosomatic outcome in coronary artery single-vessel bypass grafting. *Eur J Cardiothorac Surg*. 1999;16(Suppl. 2):S34-8.