

Use of Therapeutic Hypothermia in a Patient with Acute Coronary Heart Disease

Rafael Alves Franco, Natali Schiavo Giannetti, Carlos Vicente Serrano Jr, José Carlos Nicolau

Instituto do Coração (InCor) da Faculdade de Medicina da Universidade de São Paulo, São Paulo, SP – Brazil

Introduction

The use of therapeutic hypothermia (mild to moderate) after cardiorespiratory arrest (CRA) has proved to be beneficial to prevent neurological damage.

The use of therapeutic hypothermia should be considered in situations of CRA in the presence of heart rhythms with indication for electrical cardioversion (pulseless ventricular tachycardia – VT, or ventricular fibrillation - VF), in which the patient remains in coma after recovering spontaneous circulation. That indication can be found in current guidelines¹. However, VT/VF has been proved to be an arrhythmia that affects 10% of hospitalized patients diagnosed with ST segment elevation acute myocardial infarction (STEMI)², gaining importance in the context of candidates for hypothermia. The case reported is an example of the reality of a quaternary cardiac hospital.

Case Report

The patient JG is a 76-year-old, married, retired, hypertensive (inadequate control) male smoker. He arrived at the emergency unit complaining of strong chest pain and nausea for six hours. On ECG, elevation of the ST segment was evidenced on the inferior wall. The patient received isosorbide mononitrate, acetylsalicylic acid, and heparin (without reperfusion therapy), but the pain persisted until the following day.

The patient was transferred to the InCor/HCFMUSP on the fourth day of the STEMI. His ECG showed complete atrioventricular block (CAVB), with narrow QRS and escape heart rate of 35 bpm. The patient was sent to the catheterization laboratory, where a temporary transvenous pacemaker was placed. Then, coronary angiography followed and evidenced diffuse and severe obstructive coronary artery disease as follows: right coronary artery occlusion in its proximal third; anterior descending artery with multiple

stenoses, the largest being 75% in its middle third; circumflex artery with 75% stenosis in its middle third, and an ulcerated plaque; and left marginal artery with 50% ostial stenosis. Left ventriculography showed apical dyskinesia, inferior hypokinesia (3+/4+), and ejection fraction of 30%. Emergency surgical treatment was indicated.

On the subsequent day, at the Coronary Intensive Care Unit (CoICU), while awaiting surgery, which would be performed on the following day, the patient experienced CRA in VF, and was managed according to the American Heart Association guidelines for advanced cardiovascular life support (ACLS), recovering spontaneous circulation in 20 minutes. On the occasion, the patient was comatose, without sedation (score on Glasgow coma scale, 6: eye opening = 1 / verbal response = 1 / motor response = 4). The ECG after CRA evidenced pacemaker rhythm. The patient underwent successful percutaneous coronary intervention (PCI) in the right coronary artery, returning to the CoICU in sinus rhythm.

Because of the comatose state after resuscitation, the therapeutic hypothermia protocol was initiated, the esophageal thermometer positioned, and cooling started by using the following: chilled saline solution infused intravenously and via gastric catheter; thermal blankets; and ice packs on the axillary pits, groins and nape. Mild to moderate hypothermia (32–34°C) was used for 24 hours, with a passive rewarming period of six hours, at a rewarming rate of 0.1 – 0.5°C per hour (Figure 1). During hypothermia, the following serial laboratory tests were performed every six hours to detect changes secondary to hypothermia: CPK; CKMB; troponin I; complete blood count; coagulogram; sodium; potassium; magnesium; calcium; phosphorus; and glycemia.

Two days after rewarming, the patient experienced new VF, which was reversed by the first shock of electrical cardioversion. The patient evolved satisfactorily, being extubated after one week. He underwent treatment for lung infection with antibiotics. Regarding his coronary arteries, the patient underwent elective PCI of the anterior descending and circumflex arteries prior to hospital discharge. Finally, the patient was discharged on the 30th day of the STEMI, asymptomatic, walking, sane, and with no focal deficits (Glasgow coma scale, 15).

Keywords

Hypothermia/therapy; myocardial infarction; cardiac arrest

Mailing Address: Rafael Alves Franco •

Rua Dr. Diogo de Faria, 650, Apto 14. Postal Code 04037-002, Vila Clementino, São Paulo, SP – Brazil

E-mail: rafael.alvesfranco@yahoo.com.br, rapa20@hotmail.com

Manuscript received July 12, 2011; manuscript revised July 12, 2011; accepted October 06, 2011.

Discussion

Therapeutic hypothermia after recovering spontaneous circulation following CRA was initially used in the 1940s³. It was based on the rationale that the lower the brain

metabolism, the greater the brain protection. Initially, extremely low temperatures ($< 30^{\circ}\text{C}$) were used, to provide maximum reduction in brain metabolism, and, thus, greater protection and better neurological outcomes. In that context, frequent and important side effects were observed, from incoercible tremors to bleeding due to coagulation disorders and severe electrolytic changes, such as hypokalemia on induction or hyperkalemia on rewarming⁴⁻¹⁰.

This explains why that therapy was abandoned until the middle 1980s, when experiments with animals shed new light on the subject¹. Subsequent studies have evidenced successively that the improvement in the neurological prognosis was due to the reduction not only in brain metabolism, but in a series of events that generate neurological damage – from the ischemia-reperfusion process to the brain injury cascade⁴. Such cascade, initiated by ischemia, involves the following: mitochondrial dysfunction; proton pump dysfunction in cell wall; free radical formation; increase in vascular permeability; blood-brain barrier disruption; activation of the coagulation cascade and of the immune response; and reperfusion injury.

Therapeutic hypothermia has reemerged with the randomized and multicenter study by Holzer and Sterz⁵, with 275 patients resuscitated after CRA due to VF/VT, and who remained comatose after recovering spontaneous circulation. Moderate hypothermia was randomly compared with standard treatment (normothermia). The major results have shown an important improvement in the neurological prognosis (40% improvement in the hypothermia group, $p = 0.009$) and a reduction in mortality (26% relative risk reduction, $p = 0.02$).

In the context of acute coronary heart disease, STEMI is an important cause of complex ventricular arrhythmias (VT and VF), which can be reversed, and, thus, provides candidates for therapeutic hypothermia.

One of the pillars of the treatment of ischemic heart disease is the inhibition of platelet aggregation⁹. However, in

important hypothermia ($< 30^{\circ}\text{C}$), platelet function is altered, and that has been evidenced in animal models suggesting a reduction in platelet aggregation secondary to the decrease in platelet adhesion mediated by collagen and Von Willebrand factor, in addition to the reduction in the platelet surface and consequent prolongation in the bleeding time⁷. On the other hand, important hypothermia can generate a paradoxical prothrombotic state due to the activation of the platelet glycoprotein IIb/IIIa receptor and the reduction in ADP degradation, which would be ideally treated with P2Y12 receptor inhibitors⁷. In mild to moderate hypothermia, platelet dysfunction is mild, with a possible reduction in platelet count but no repercussion in bleeding⁴, which does not require a change in the antiplatelet treatment of the disease.

Another important point is the safety and adequacy of performing catheterization and PCI in an individual undergoing hypothermia. Batista et al.⁸, comparing patients undergoing hypothermia and PCI with those undergoing only hypothermia, have reported no difference regarding adverse events (arrhythmias, coagulopathy, infections, hypotension, neurological sequelae or mortality)⁸. It is worth noting that mild to moderate hypothermia in the post-CRA setting is recommended by the American Heart Association guidelines for advanced cardiovascular life support (ACLS), and it is equally effective and safe when used concomitantly with PCI¹.

The objective of hypothermia in acute myocardial infarction is to improve the neurological prognosis, and neither to limit the area of necrosis nor to reduce the incidence of cardiovascular outcomes, as it could be assumed by the prevention of ischemia-reperfusion mechanism-induced damage, present in myocardial infarction⁶.

Briefly, the use of mild to moderate hypothermia properly indicated (comatose patients after recovering from CRA, who initially had heart rhythms with indication for electrical cardioversion – pulseless VF/VT) in the context of acute coronary heart disease seems safe and effective, leading to the improvement in neurological outcomes and interfering significantly with neither antiplatelet therapies nor PCI. Those perspectives should be tested in further studies designed for that purpose, so that definitive conclusions on such a relevant subject can be drawn.

Potential Conflict of Interest

No potential conflict of interest relevant to this article was reported.

Sources of Funding

There were no external funding sources for this study.

Study Association

This study is not associated with any post-graduation program.

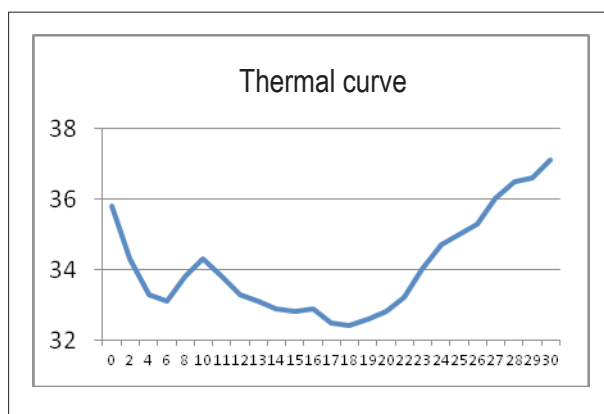


Figure 1 - Thermal curve over 30 hours after initiating hypothermia.

Case Report

References

1. Peberdy MA, Callaway CW, Neumar RW, Glocadin RG, Zimmerman JL, Donnino M, et al. Post-cardiac arrest care: 2010 American Heart Association Guidelines for Cardiopulmonary Resuscitation and Emergency Cardiovascular Care. *Circulation*. 2010;122(18 Suppl 3):S768-S786.
2. Libby P, Bonow RO, Mann DL, Zipes DP. Braunwald's heart disease: A textbook of cardiovascular medicine, 8th edition. Philadelphia; Lippincott; 2008.
3. Fay T. Observations on prolonged human refrigeration. *NY State J Med*. 1940; 40: 1351-4
4. Polderman KH. Mechanisms of action, physiological effects, and complications of hypothermia. *Crit Care Med* 2009; 37[7 Suppl.]:S186 -S202.
5. Holzer M, Sterz F. Mild therapeutic hypothermia to improve the neurologic outcome after cardiac arrest. *N Engl J Med*. 2002;346(8):549-56.
6. Parham W, Edelstein K, Unger B, Mooney M. Therapeutic hypothermia for acute myocardial infarction: Past, present, and future. *Crit Care Med*. 2009; 37[7 Suppl.]:S234 -S237.
7. Staub A, Westein E, Bassler N, et al. Abstract 2322: Mechanisms of Cold-Induced Platelet Dysfunction: P2Y12 Receptor Blockade Protects Platelets during Hypothermia as Employed in Clinical Settings[abstract]. *Circulation*. 2008;118:S706.
8. Batista LM, Lima FO, Januzzi JL Jr, Donahue V, Snyderman C, Greer DM.. Feasibility and safety of combined percutaneous coronary intervention and therapeutic hypothermia following cardiac arrest. *Resuscitation*. 2010; 81(4):398-403.
9. Pesaro AEP, Serrano Jr CV, Nicolau JC. Infarto agudo do miocárdio - síndrome coronariana aguda com supradesnível do segmento ST. *Rev Assoc Med Bras*. 2004;50(2): 214-20.
10. Janata A, Holzer M. Hypothermia after cardiac arrest [review]. *Prog Cardiovasc Dis*. 2009 ;52(2):168-79.