

## Giant Aneurysm of Saphenous Vein Bypass for Right Coronary after Angioplasty

Mauro Guimarães Albuquerque<sup>1</sup>, Jorge Alcântara Farran<sup>1</sup>, Carlos Alberto Pires Pereira<sup>1,2</sup>, Edson Renato Romano<sup>1</sup>, Isabela Neto Macri Brotto<sup>1</sup>, Marcelo Luz Pereira Romano<sup>1</sup>

Hospital do Coração (HCor)<sup>1</sup>; UNIFESP<sup>2</sup>, São Paulo, SP - Brazil

### Case report

Male, 54 years-old with progressive dyspnea associated with weight loss and episodes of fever and diarrhea. Hypertension, dyslipidemia, smoking, three acute myocardial infarctions (AMI) respectively for twelve years, four years and three years. Revascularized in the first AMI (1998) with the following bypasses: Left Anterior Descending Mammary (LADM), Aorta-Radial First Marginal (AoRadMg1), Aorta saphenous Diagonal (AoSapDg), Aorta Saphenous Second Marginal (AoSapMg2), Aorta Right Coronary Saphenous (AoRC). The patient had left ischemic stroke (ICVA) after surgery. In the second IAM (2006) without supra depression of the ST segment that injured the lower wall, showing two lesions on the bypass AoSapRC and the left subclavian artery, being treated off the acute phase percutaneously with success (two pharmacological stents in the bypass, "Taxus" and "Endeavor" and a conventional stent in the subclavian: "Palmaz-genesis"). A year later he had another AMI in the same area, with lesions between stents. Angioplasty was attempted with conventional stent in the acute phase, without success. The patient has remained in clinical treatment so far. Physical examination showed the patient to be tachydyspneic, afebrile, tachycardic, normotensive, with episodes of desaturation. The initial X-ray showed bilateral congestion. The echocardiogram showed an ejection fraction of 52% with mid-basal akinesia of inferior-posterior wall with restricted left atrial filling by extrinsic compression. The cardiac enzymes, atrial natriuretic peptide (BNP), renal function and electrolytes were normal. Leukocyte count of 9,020 cells/mm<sup>3</sup> without deviation, hemoglobin (Hb) of 15.9 g / dL, platelets 181,000 cells/mm<sup>3</sup>, D – dimer 2510. Urinalysis normal with uro and negative blood cultures. ESR 20 mm, AC-125 6.79 U / mL (normal), CA 9.19 8.91 U / mL (normal), CEA 9.31 U / mL (increased). Arterial blood gas analysis

at pH 7.5, PCO<sub>2</sub> 23mmHg, HCO<sub>3</sub>-18 mEq / / L, lactate 14 mg / dL, AST 40 U / L, ALT 25 U / L, GGT 61 U / L, total bilirubin 0, 3 mg / dL (direct 0.04 mg / dL and indirect 0.26 mg / dL), INR 1.4, APTT 40.3 s, TAP 17.3 s and fibrinogen 320 mg / dL, anti-hepatitis A total reagent IgM negative, anti-HBc reactive, indeterminate anti-HBe, HBeAg negative, anti-HBs reagent, reagent HBsAg, anti-HCV negative, anti-HIV-1 reagent (confirmed with Bloot Westen), two anti-HIV negative, RC4 243 cells/mm<sup>3</sup>, viral load 260 copies/mm<sup>3</sup>. Chest CT angiography excluded PTE and PVT, showed ground-glass opacity and sparse aneurysm bypass RAoC measuring 6.7 x 5.5 x 4.7 cm (Figures 1 and 2). It was initiated broad-spectrum antibiotics and trimethoprim-sulfamethoxazole associated with subsequent introduction of antiretroviral regimen. There was clinical improvement, but the patient evolved with multiple hospitalizations in the intensive care unit for pulmonary sepsis and herpes simplex encephalitis, opting for no manipulation of the aneurysm.

### Discussion

Saphenous vein grafts have been commonly used in CABG surgery since its introduction by Favaloro in 1968<sup>4</sup>. Aneurysm of aortocoronary bypasses is a rare and potentially fatal complication of coronary artery bypass grafting surgery<sup>1-4</sup>. Its true incidence is unknown and it is believed to be underestimated. It is known that the dilation of coronary bypass is relatively common (14% in five to seven years)<sup>4</sup>.

It can be classified as true aneurysm or pseudo-aneurysm. And despite some ambiguities in the literature, the first has a late presentation and involves the whole vessel wall, presenting as an enlargement of more than 1.5 times the normal size of the vessel<sup>1,4</sup>. On the other hand, the pseudo-aneurysm is not formed by all the structures of the vascular wall and it can occur earlier<sup>7</sup>, presenting usually near the proximal or distal anastomosis. Several mechanisms are involved in the formation of true aneurysm, such as hyperlipidemia<sup>1</sup>, atherosclerosis, smoking, weakness of the venous endothelium (veins prone to varicose veins). In contrast, the problems with the surgical technique or vein preparation, trauma and infections are related to the pseudoaneurysma<sup>4</sup>. Percutaneous interventions and predisposition to arterial aneurysms may also be involved<sup>4</sup>. In our case, probably his symptoms were more associated with infection than with the aneurysm itself, and the diagnosis was an incident, which confirmed a true aneurysm after coronary angioplasty bypass grafting.

### Keywords

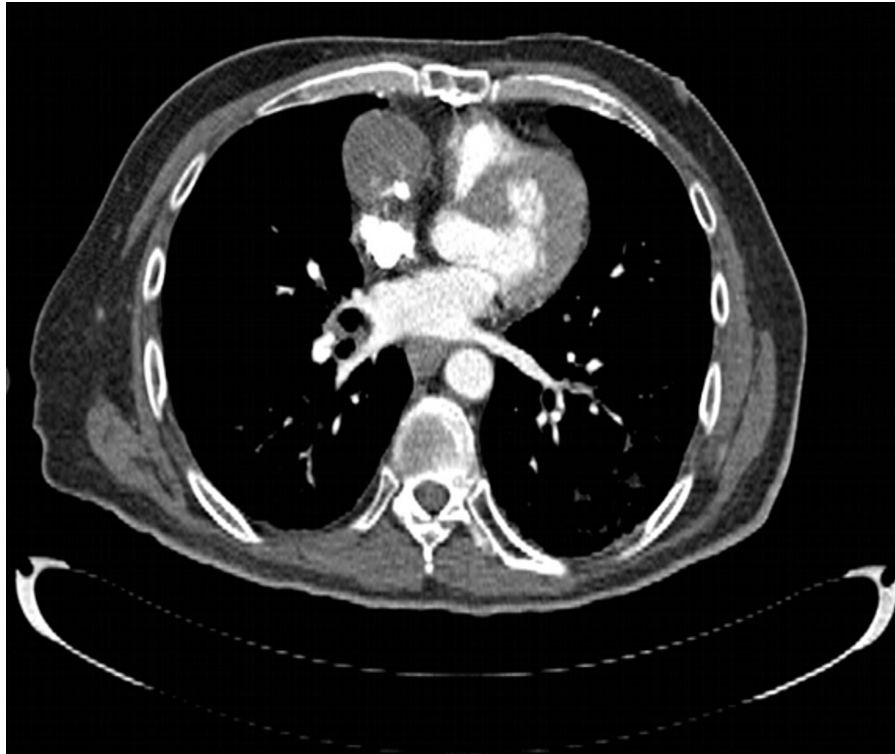
Coronary artery bypass; saphenous vein / surgery; aneurysm / complications; angioplasty.

#### Mailing Address: Mauro Guimarães Albuquerque •

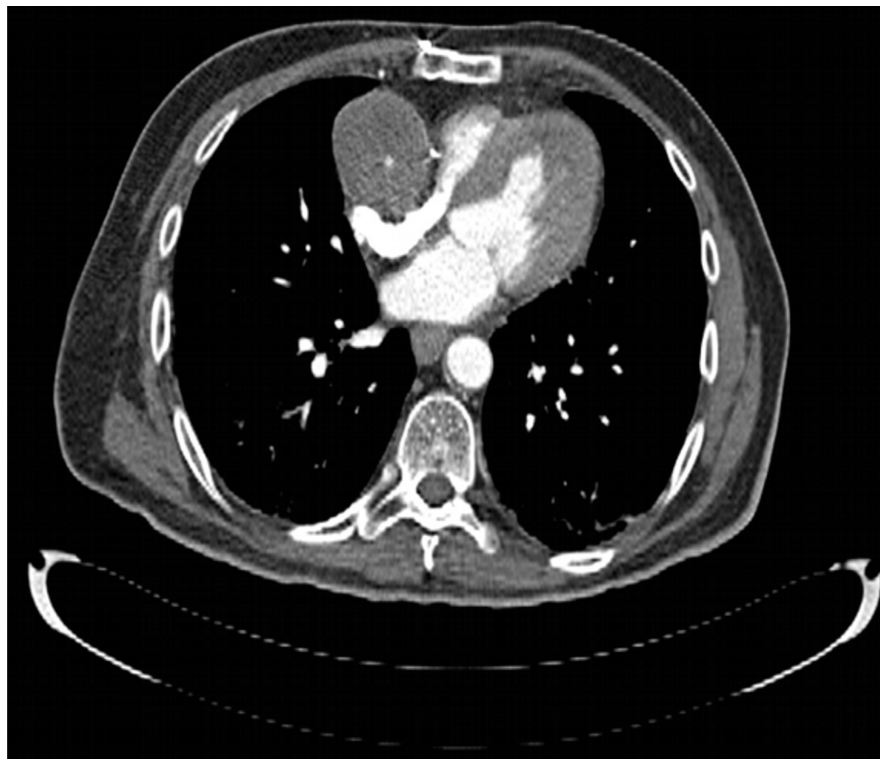
Rua Correia Dias, 476, apart. 54, bloco: B, Paraíso. Postal Code 04104-001, São Paulo, SP - Brazil

E-mail: mgalbuquerque@cardiol.br, mgalbuquerque9@hotmail.com

Manuscript received August 08, 2011; manuscript revised September 14, 2011; accepted September 28, 2011.



**Figure 1** - Giant Aneurysm of right coronary aorta (RCAo) compressing the right ventricle.



**Figure 2** - Giant true aneurysm of Right Aortocoronary Bypass.

## Case Report

The time between diagnosis and surgery can vary from several days to several years, and although the mean was between five and seven years, there are reports of late cases diagnosed up to twenty one years after CABG<sup>8,9</sup>. The clinical presentation is mostly asymptomatic and is diagnosed through routine screening. However, it can present itself with chest pain, dyspnea, abdominal distension, acute myocardial infarction and heart failure. Amongst the complications, the possibilities are: rupture<sup>2,10</sup>, hemothorax, hemopericardium, embolization, fistulization for various structures (lungs, pulmonary artery<sup>4</sup>, atria or ventricles) and compression of cardiac chambers or vascular structures.

The diagnosis may be suspected by the presence of mediastinal extension of the chest X-ray<sup>4,9</sup> and confirmed with computed tomography of chest<sup>4,9</sup>, echocardiogram<sup>4,9</sup>, or MRI<sup>4,8,9</sup>. The reference standard remains coronary angiography<sup>3,4,9</sup>. In this case, the echocardiography and chest CT with contrast (CT angiography) were enlightening; confirming the diagnosis of a giant aneurysm of saphenous vein AoRC with two stents previously implanted compressing the left atrium.

Due to the high mortality associated with the probability of rupture, the resection of the aneurysm associated with new CABG surgery is recommended<sup>4</sup>. Alternatively, in patients

with high surgical risk, it can be attempted hemodynamically by embolization with coils<sup>4</sup> or Amplatzer vascular plug<sup>3</sup>. Some authors report the use of stents and polytetrafluorene<sup>4</sup>. Medical non invasive treatment has shown no positive results<sup>8</sup>, and it should be reserved for patients at high surgical risk and asymptomatic. Periodic follow-up with imaging is mandatory to detect increase in the diameter of the aneurysm and program possible interventions. In the reported patient, we opted for conservative treatment because of the high surgical risk and the high number of comorbidities.

### Potential Conflict of Interest

No potential conflict of interest relevant to this article was reported.

### Sources of Funding

There were no external funding sources for this study.

### Study Association

This study is not associated with any post-graduation program.

## References

1. Kalimi R, Palazzo RS, Graver LM. Giant aneurysm of saphenous vein graft to coronary artery compressing the right atrium. *Ann Thorac Surg.* 1999;68(4):1433-7.
2. Távora FR, Jeudy J, Burke AP. Multiple aneurysms of aortocoronary saphenous vein grafts with fatal rupture. *Arq Bras Cardiol.* 2007;88(5):107-10.
3. Mylonas I, Sakata Y, Salinger MH, Feldman T. Successful closure of a giant true saphenous vein graft aneurysm using the Amplatzer vascular plug. *Catheter Cardiovasc Interv.* 2006;67(4):611-6.
4. Memon AQ, Huang RI, Marcus F, Xavier L, Alpert J. Saphenous vein graft aneurysm: case report and review. *Cardiol Rev.* 2003;11(1):26-34.
5. Kallis P, Keogh BE, Davies MJ. Pseudoaneurysm of aortocoronary vein graft secondary to late venous rupture: case report and literature review. *Br Heart J.* 1993;70(2):189-92.
6. Riahi M, Vasu CM, Tomatis LA, Schlosser RJ, Zimmerman G. Aneurysm of saphenous vein bypass graft to coronary artery. *J Thorac Cardiovasc Surg.* 1975;70(2):358-9.
7. Noiseux N, Mansour S, Prieto I. Images in cardiology: acute chest pain due to ruptured giant aortocoronary saphenous vein graft aneurysm. *Can J Cardiol.* 2009;25(2):78.
8. Mayglothling J, Thomas MP, Nyzio JB, Strong MD, Samuels LE. Aneurysm of aortocoronary saphenous vein graft: case report and literature review. *Heart Surg Forum.* 2004;7(4):317-20.
9. Moukala-Cadet AM, Mitrosky SJ, Miller GD, Swayze DA, Fielding EJ, Hoh MJ, et al. Multiple aortocoronary bypass saphenous vein graft aneurysms in a 77-year-old man. *J Am Osteopath Assoc.* 2006;106(11):663-6. Erratum in: *J Am Osteopath Assoc.* 2006;106(12):688.
10. Murphy JP Jr, Shabb B, Nishikawa A, Adams PR, Walker WE. Rupture of an aortocoronary saphenous vein graft aneurysm. *Am J Cardiol.* 1986;58(6):555-7.