

Accuracy of Chest Radiography plus Electrocardiogram in Diagnosis of Hypertrophy in Hypertension

Sergio Marrone Ribeiro¹, José Morceli¹, Renato Souza Gonçalves², Roberto Jorge da Silva Franco², Francisco Habermann², Domingos Alves Meira¹, Beatriz Bojikian Matsubara²

Departamento de Doenças Tropicais e Diagnóstico por Imagem, Faculdade de Medicina de Botucatu, UNESP – Universidade Estadual Paulista¹; Departamento de Clínica Médica, Faculdade de Medicina de Botucatu, UNESP – Universidade Estadual Paulista², Botucatu, SP – Brazil

Abstract

Background: Chest radiography and electrocardiogram have been criticized due to their low sensitivity for Left Ventricular Hypertrophy diagnosis compared to echocardiogram. This one, however, is not available in primary health care centers to all hypertensive population.

Objective: To evaluate whether the association chest radiography-electrocardiogram provides the accuracy to justify its use in left ventricular hypertrophy detection in hypertensive patients, as well as the usefulness of the cardiothoracic ratio and oblique radiographs in relation to frontal and lateral views in evaluating dimensions of left cardiac chambers.

Methods: This was a prospective study including 177 consecutive hypertensive patients through chest radiography, electrocardiogram and echocardiography. Accuracy test was used to compare these methods using echocardiography as gold standard.

Results: The cardiothoracic ratio showed 17% sensitivity for detection of left ventricular hypertrophy, only indicating cardiac alterations at an advanced stage. Frontal plus lateral views showed sensitivity of 52%, which rose to 54% when chest radiography was associated with electrocardiogram. The oblique views did not significantly improve chest radiography accuracy. Chest radiography presented high specificity and elevated sensitivity for detection of aortal enlargement. Interestingly, this alteration was present in half of the hypertensive patients with left ventricular hypertrophy.

Conclusion: We conclude that the association chest radiography-electrocardiogram is useful for the screening of hypertensive patients for the diagnosis of left ventricular hypertrophy, especially if echocardiogram is unavailable. (Arq Bras Cardiol 2012;99(3):825-833)

Keywords: Chest radiography; electrocardiography; echocardiography; hypertrophy, left ventricular; hypertension.

Introduction

Left ventricular hypertrophy (LVH) is a marker of poor prognosis in hypertensive patients and its detection leads to a more aggressive therapeutic approach. Longitudinal studies in hypertensive patients and the general population have reported that individuals in whom LVH had declined subsequently presented lower morbidity and mortality rates than those whose left ventricular mass had risen. As a result, the prevention or reversal of hypertensive LVH is widely accepted as a desirable objective¹.

The diagnosis of LVH is particularly based on echocardiography. Nevertheless, systemic arterial hypertension is widespread among the population and the echocardiogram

(Echo) exam is not available in all locations, in contrast to chest radiographs and Electrocardiogram (ECG), which are inexpensive exams of easy access. Until 20 years ago LVH diagnosis was based on ECG or chest radiographs, but these methods were found insufficient and of low accuracy². However, we found no study in the literature that sought to evaluate the accuracy of chest radiographs, with at least two views, associated with ECG, defining the actual role of these exams in approaching hypertensive patients at risk for LVH. The main guidelines for the diagnosis and management in arterial hypertension^{3,4} do not clarify whether chest radiograph is necessary in the initial approach to hypertensive patients, neither how it should be done, if with one or two views.

The cost of applying Echo to the whole population of hypertensive patients is excessively high for poor countries with limited funds for public health. Even in developed countries, it has been reported that the availability of such resources for epidemiological studies is still limited^{5,6}. Furthermore, in many countries, specialized physicians perform the exams, thus increasing their costs. For these reasons, it can hardly be

Mailing Address: Sergio Marrone Ribeiro •

Rua Nelo Pedretti, nº 420, Chácara Montagna. Postal Code 18609-030, Botucatu, SP - Brazil

E-mail: sribeiro@fmb.unesp.br, epribeiro@uol.com.br

Manuscript received September 27, 2011; manuscript revised September 27, 2011; accepted April 9, 2012.

employed as a routine exam in public health programs for early detection of LVH in hypertensive patients and for prevention of its serious consequences.

The main objective of this study was to evaluate whether the chest radiograph-plus-ECG association attains an accuracy that justifies its use in the detection of LVH in hypertensive patients. In addition, we sought to verify the usefulness of the cardiothoracic ratio in the detection of hypertrophy or dilation of the left ventricle, compared with the full radiographic study including two or four views of the cardiac area and the utility of oblique views in relation to frontal and lateral views in evaluating enlargement of dimensions in left cardiac chambers.

Methods

This is a cross-sectional, prospective study including subjects recruited at the time of routine follow-up appointments. All patients agreed to participate and the Institution's Ethics Committee approved the procedures.

Study population

One hundred and seventy-seven consecutive patients older than 18 years were included in the study. They had previous diagnosis of arterial hypertension and were referred from primary health care centers for echocardiography examination for LVH screening. The exclusion criteria were

cardiovascular disease other than hypertension, overt heart failure, pregnancy, bundle branch block or atrial fibrillation in ECG, and poor technique exams. Clinical evaluation, chest radiograph, electrocardiogram and echocardiography were performed on the same day.

Clinical evaluation

It was performed by a cardiologist and included a complete history and physical exam. After resting for at least 10 min in supine position, systolic and diastolic blood pressures were determined as the average of three replicate measurements taken 1 min apart using a mercury sphygmomanometer.

Radiographic examination

Four views digitalized chest radiographs (frontal, lateral, right anterior oblique and left anterior oblique) were obtained according to international recommendations and using the equipment Radiological Set MULTIX B – 500 mA, Siemens, Erlangen, Germany. Digitalized images were acquired using the Module ADC COMPACT PLUS, AGFA, Germany, utilizing phosphorus screens and the DRY laser printer STAR 3000, also from AGFA.

The following criteria were used for diagnosis of LVH: cardiothoracic ratio greater than 0.50, signs of left ventricle dilation or rounding of the cardiac silhouette, in frontal and lateral views (Figure 1). This cardiac silhouette rounding is a

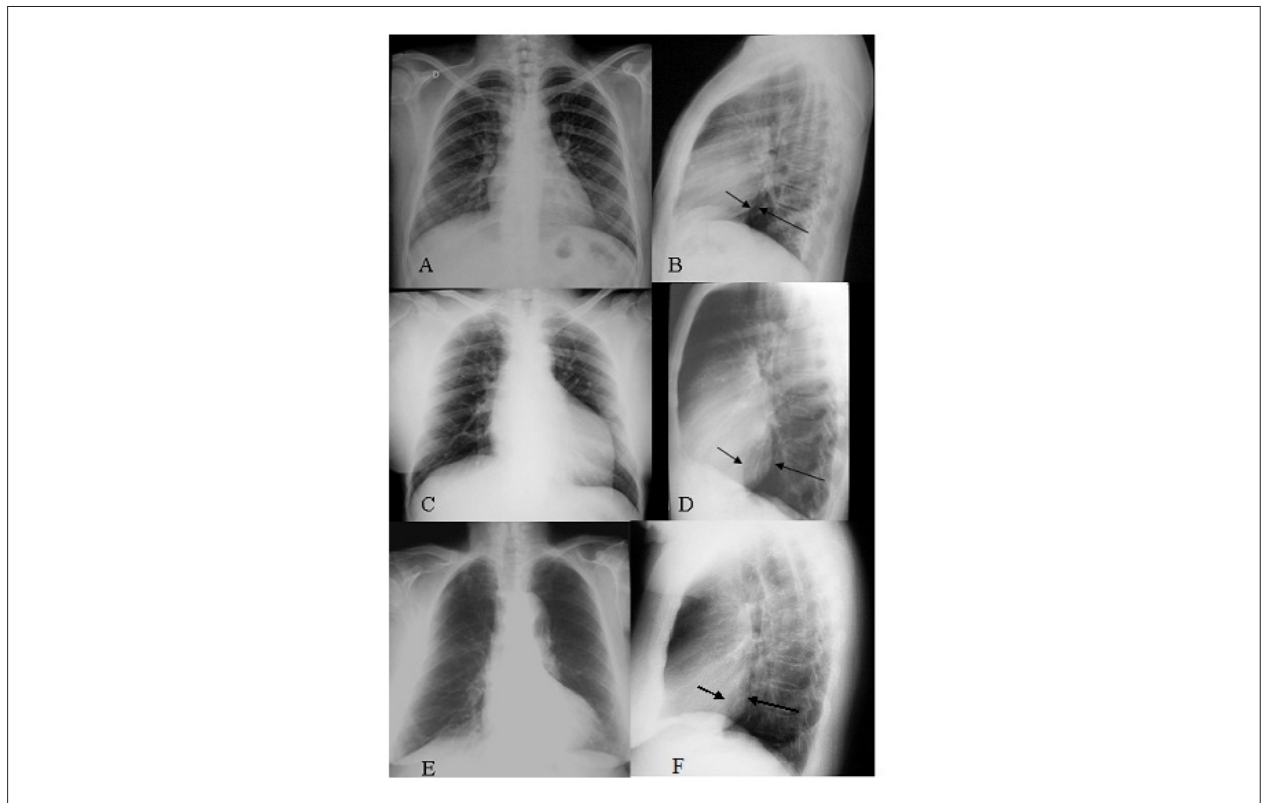


Figure 1 - Frontal and lateral views of normal (A, B) and enlarged (C, D) left ventricle. The arrows indicate normal and altered ratios between the inferior vena cava (smaller arrow) and left ventricle (larger arrow). The round outline of the left ventricle, when identified in both incidences (E, F), is also a sign of left ventricle hypertrophy.

visual subjective criterion reflecting abnormal left ventricular shape, validated for both views, frontal and lateral. The Rigler's measurement⁷ was used as an additional, but not exclusive criterion. LV enlargement identified in at least two views was taken as indicative of LVH. The oblique views were analyzed only after the radiologists had concluded the evaluation of frontal and lateral views, when, thus, it was defined whether or not these views added information or modified the previous cardiac evaluation. In addition, dilation of left atrium and right chambers was evaluated according to the classic criteria established by the literature. Finally, aortic dilation was defined as aortic knob greater than 3.5 cm in the frontal view.

Using Echo as the gold standard, sensitivity, specificity and accuracy were calculated as well as the positive and negative predictive values, utilizing only the frontal and lateral views, which were later associated with the two oblique views.

The radiographs were analyzed by two independent radiologists, blinded as to the ECG and echocardiography results. In cases of disagreement, the exam was evaluated jointly, thereby obtaining a consensus. Using this method, the interobserver variability for LVH diagnosis was 4.52% in our imaging laboratory.

Electrocardiographic evaluation

ECG was accomplished by means of the ECG Acquisition Module on a TEB brand computer, Brazil. Thus, 12 simultaneous derivations were obtained digitally with duration of 8 seconds and the measurements realized with an automatic cursor.

The scoring system of Romhilt and Estes⁸ was applied to evaluate left ventricular overload. Romhilt established that a sum of points greater than or equal to 5 constitutes a diagnosis of left ventricular overload, while a score equal to 4 is suggestive of this condition. We consider patients with a score of at least 4 to be positive for LVH.

Doppler-echocardiography evaluation

All exams were performed by the same cardiologist using a Philips HP Sonnos 2000 apparatus (Bloomfield, CT, USA) equipped with an ultrasonic multifrequency 3.5 MHz/2.25 transducer of 2.0-3.5 MHz, with simultaneous electrocardiographic recording and image registry system. The exams were performed including M-mode measurement of left atrial and left ventricular dimensions according to the recommendations of the American Society of Echocardiography⁹. Aortic valve outflow and mitral valve inflow were analyzed by pulsed wave Doppler from apical five-chamber and four-chamber views, respectively.

Reference upper limit values for LV mass normalized for body surface area (95 g/m² for women and 115 g/m² for men)⁹ were used for echocardiographic diagnosis of LVH. The relative wall thickness (RWT) was calculated as $(IVSd + PWTd)/LVIDd$, where IVSd, PWTd and LVIDd are the diastolic interventricular septum thickness, posterior wall thickness and LV internal dimension, respectively. The reference upper limit for RWT was 0.42. Based on LV morphology, patients were classified into four categories: concentric hypertrophy (LV hypertrophy and increased RWT), eccentric hypertrophy (LV hypertrophy and normal RWT), concentric remodeling

(normal LV mass and increased RWT) and normal geometry (normal LV mass and normal RWT). The criteria used for definition of hypertensive cardiopathy were: presence of LV hypertrophy or concentric remodeling, systolic ventricular dysfunction or LV dilation. The diagnostic criteria for LV dilation, left atrium (LA) enlargement and aorta dilation were¹⁰: LV \geq 5.6 cm (normal from 3.5 to 5.6 cm), LA $>$ 3.8 cm in women and $>$ 4.0 cm in men, aortic root diameter $>$ 3.7 cm.

Statistical analysis

According to the data obtained, frequencies were calculated for the categorized variables and the descriptive statistics for the numeric variables. For Echo morphometric findings, the difference in means was calculated by gender by the Student's t test. Values were calculated for sensitivity, specificity and accuracy as well as positive and negative predictive values for each exam and for associations of exams; in this case LVH was diagnosed if chest radiograph or ECG were positive for hypertrophy. For analysis of some of the differences observed among these measures, the chi-square test was employed. In all tests the significance level was considered 5% ($p < 0.05$).

Results

Clinical and demographic characteristics

Seventy-five male and 102 female patients aged between 20 and 85 years (mean 52.6 years and median 54 years) were included in the study. Mean systolic and diastolic blood pressures were 149 ± 23.8 and 93 ± 16.0 mmHg, respectively. The time course of the disease reported by the patients was 9.5 years. Body mass index and medical history of arterial hypertension, dyslipidemia, diabetes, and tobacco smoking are shown in Table 1. The majority of patients were under treatment with 2 or 3 classes of antihypertensive drugs.

Echocardiographic variables

Table 2 shows the frequencies of normal geometry, concentric remodeling, eccentric and concentric hypertrophy. Hypertensive heart disease was found in 91 cases (51.4%). Table 3 summarizes the main echocardiographic findings in the study population.

Radiological variables

Twenty patients (11%) presented an elevated cardiothoracic ratio, whereas 142 (80%) displayed a normal cardiothoracic ratio. In 15 cases (8%), the chest radiograph was unsuitable for cardiothoracic ratio evaluation due to elevated diaphragmatic domes. These were excluded from the analysis of accuracy of cardiothoracic ratio for diagnosis of LVH. The sensitivity, specificity, positive and negative predictive values as well as accuracy of the cardiothoracic ratio for LVH detection in hypertensive patients are shown in Table 4.

The analysis of cardiac silhouette in the frontal and lateral view for determination of LV alterations, as initially suspected, was much more sensitive than isolated analysis of the cardiothoracic ratio. The chest radiograph findings in relation to LVH and their comparison with Echo are presented in Table 4.

Table 1 - Demographic and clinical characteristics of 177 hypertensive patients

	Mean	n	%
Age	52,6 ± 13,5		
BP			
	Systolic	149 ± 23,8	
	Diastolic	93 ± 16,0	
Sex			
	M	75	42,4
	F	102	57,6
Race			
	White	145	81,9
	Black	12	6,8
	Mixed	15	8,5
	Asian	1	0,5
	WI	4	2,3
Medical history			
	FAAH	111	62,7
	Dyslipidemia	67	37,8
	Diabetes	29	16,4
	Tobacco smoking	18	10,2
BMI			
	≤25	45	25,4
	>25 ≤30 (overweight)	79	44,6
	>30 ≤35 (obesity)	37	20,9
	>35 (morbid obesity)	16	9,1

BP-blood pressure; BMI-body mass index; FAAH-familial antecedent of arterial hypertension; F-female; M-male; WI-without information.

Table 2 - Frequencies of normal geometry, concentric remodeling (CR), eccentric and concentric hypertrophy (LVH) in hypertensive patients

	Normal	CR	Eccentric LVH	Concentric LVH	Total
Geometry					
Male	37(49,3%)	5(6,6%)	19(25,3%)	14(18,7%)	75
Female	46(45,1%)	15(14,7%)	26(25,5%)	15(14,7%)	102
Total	83(46,9%)	20(11,3%)	45(25,4%)	29(16,4%)	177

Table 3 - Morphometric findings of LV in 177 hypertensive patients, expressed as means and standard deviations

Variable	Women	Men	p*
n	102	75	
IVSTd (cm)	0,93 ± 0,13	1,00 ± 0,16	0,0003
LVDD (cm)	4,66 ± 0,43	5,06 ± 0,50	< 0,0001
PWTd (cm)	0,92 ± 0,12	1,00 ± 0,15	< 0,0001
LV mass (g)	148 ± 33	193 ± 52	< 0,0001
LVM/BSA (g/m ²)	85 ± 19	100 ± 29	< 0,0001
RWT	0,40 ± 0,06	0,40 ± 0,07	0,7231

IVSTd-diastolic interventricular septum thickness; LVDD-left ventricular diastolic diameter; PWTd-diastolic posterior wall thickness; LV-left ventricle; LVM/BSA-left ventricular mass/body surface area; RWT-relative wall thickness; (*) The p-value was calculated based on the Student's t test for 2 independent samples.

Tabela 4 - Accuracy of Chest Radiograph and Electrocardiogram in relation to Echocardiogram in detection of LVH in hypertensive patients

Method	Sens	Spec	PPV	NPV	A
CTR	16,7	88,3	33,3	75,2	69,7
C Rad	52,1	67,4	37,3	79,1	63,3
Ao	50,0	63,6	33,8	77,4	59,9
ECG	12,5	92,2	37,5	73,9	70,6
C Rad+ECG	54,2	62,8	35,1	78,6	60,4

A- Accuracy; Ao- Radiological aortic ectasy; C Rad-Chest Radiographs; CTR- Cardiothoracic Ratio; ECG-Electrocardiogram; NPV-Negative Predictive Value; PPV-Positive Predictive Value; Sens-Sensitivity; Spec-Specificity.

The complete study including both right and left oblique anterior radiographs with a suitable technique was obtained in 153 patients. The diagnoses accomplished utilizing only frontal and lateral views were compared with those obtained from the four views. The differences observed did not present the level of statistic significance through the Chi-square test ($p > 0.05$). The p-value calculated was 1 for sensitivity, $p = 0.486$ for specificity and $p = 0.639$ for accuracy. Chest radiographs without oblique projections presented sensitivity of 50.0% and specificity of 67.3%, with accuracy of 62.7% for detection of LVH. The inclusion of oblique views slightly increased sensitivity (52,5%) without significance.

The chest radiographs showed very low sensitivity for detection of left atrial enlargement, independently of the number of views (9.8% for two views and 13.7% for four views). The specificities were, respectively, 90.7% and 83.3%. Chest radiographs showed high sensitivity (72.7%) for detection of increased aortal diameter. Negative predictive value was 97.2% and specificity and accuracy were approximately 62%. Interestingly, half of the patients presenting aortal dilatation also had LVH (Table 4).

Venous congestion was identified in radiographs of 22 patients (12.4%), including 20 in mild form and 2 with signs of blood redistribution. All of them showed preserved systolic function, and 17 presented with diastolic dysfunction in Echo. Despite the low sensitivity of this finding for diastolic dysfunction (13.8%), the specificity was high (90.7%).

Electrocardiographic variables

Sixteen patients presented Romhilt score ≥ 4 (suggestive of or with left ventricular overload) while 161 patients scored < 4 (normal). Despite its high specificity (92.2%), ECG displayed low sensitivity (12.5%) for detection of LVH in hypertensive patients (Table 4).

When patients were separated by gender, we observed that sensitivity was greater in men than in women, being 16.7% and 10.0% respectively. Specificity was 87.7% for men and 95.8% for women. The differences observed did not present level of statistic significance through the Chi-square test ($p > 0.05$), with p-value of 0.8217 for sensibility and 0.1676 for specificity.

Association of chest radiographs with electrocardiogram

Due to the low sensitivity of ECG in LVH detection (12.5%), no significant increase was observed in sensitivity by chest radiographs (52%) when associated with ECG for diagnosis of LVH in hypertensive patients (54%), as shown in Table 4.

Discussion

This study demonstrates the accuracy of chest radiograms associated to conventional ECG compared with echocardiography for LVH diagnosis in hypertensive patients. Echocardiogram was taken as golden standard because of its worldwide use for cardiac evaluation, particularly for LVH screening in hypertensive patients. The prevalence of LVH in this population was in accordance with other authors^{1,11-13}.

The use of two radiological views for analyzing cardiac silhouette and identifying LV size alterations, as initially suspected, was much more sensitive than isolated analysis of the cardiothoracic ratio. The addition of oblique views did not improve the accuracy of posteroanterior and lateral projections for detection of enlargement of the left ventricle and left atrium. These results explain the poor accuracy of chest radiograms found by others that used only the cardiothoracic ratio or measures of cardiac enlargement as a whole for detection of left ventricular enlargement^{5,14-20}. Since the studies of Eyer et al.²¹ and of Hoffman and Rigler²², the importance of lateral radiography has become evident for evaluation of the left ventricle. Preserved cardiothoracic ratio did not exclude augmented LV posterior wall thickness, which occurred in 42% of patients in a study using Echo as the gold standard in hypertensive patients¹⁵.

The subjective/visual evaluation of left ventricular size proved to be as sensitive as any of the used measures²³. This was also observed in the first 50 patients of this study and so we have abandoned these objective measurements.

It is not possible to differentiate, by radiology, hypertrophy from dilation²⁴. Therefore, the patients with any of these alterations were jointly classified as altered, using the term LVH as a means of comparison with Echo.

The radiological finding of altered cardiac silhouette from a single view cannot be exploited since enlargement of the left ventricle can simulate augmentation of the right ventricle and vice versa^{25,26}, so that a minimum of two views is needed to confirm or discard this finding. Enlargement of the right ventricle provokes dislocation of the left ventricle simulating

increase of the latter, a phenomenon initially described by Dinsmore et al. in 1966²⁵.

Chest radiograph is an extremely widespread diagnostic method. In this study, the interpretation of radiographs by specialists must have had a role in the detection of cardiac silhouette alterations, even in the absence of evident cardiomegaly.

We did not observe significant differences in the radiological detection of concentric remodeling and LVH, suggesting that both concentric remodeling and LVH cause change in the left ventricular contour equally detectable by radiology, although with lower sensitivity in the first case.

The slight increase in sensitivity obtained by the use of oblique radiographs in evaluating both left ventricle hypertrophy and left atrial enlargement showed the poor utility of these views in the investigation of hypertensive patients. The sensitivity for detecting left atrial enlargement was very low independently of inclusion of oblique radiographs, despite elevated specificity. These findings are in agreement with previous studies^{26,27}.

Interestingly, we found an important association between augmented aorta in radiograms and echocardiogram, a much closer association than that found for the left ventricle. The aortic knob measured at chest radiographs is performed more distal than in the Echo measurement, which is performed at the aortic valve level. As the effect of hypertension is greater at the aortic knob than the aortic root²⁸ the chest radiograph may have detected cases of true aortic dilation that Echo interpreted as normal. Such cases end up being interpreted as false positives. Therefore, this correlation would be even better if the Echo measures had been taken at the aortic arch. Importantly, there was a close association between LVH and aortal dilation in chest radiography, in accordance with others^{28,29}.

Despite the high specificity of 93%, the sensitivity of ECG for detecting LVH in this study was very low, only 12%. It must be considered that this diagnosis utilized the scoring criterion of Romhilt and Estes⁶ in hypertensive patients under pharmacological treatment. Electrocardiographic criteria for LVH in hypertensive patients have shown sensitivities varying from 12% to 51% and specificities from 69% to 96%^{2,30}.

Considerable controversy exists as to which of the numerous electrocardiographic criteria for LVH have the best sensitivity and specificity. However, the accuracy of these particular criteria depends on the prevalence and severity of LVH in the studied populations³¹. This fact explains the distinct sensitivities found in the FRAMINGHAM Cardiac Study^{32,33} in general population and other studies in patients with cardiac diseases including arterial hypertension. In the first case, ECG presented a very poor sensitivity excluding this one as a cost effective method. On the contrary, in patients with cardiac diseases, ECG despite the low sensitivity has a sufficiently high specificity to recommend its use in routine clinical evaluation of hypertensive patients^{2,30}. Also, it has been suggested that, electrocardiographic-modified criteria for LVH detection would improve accuracy compared to standard criteria^{30,34,35}.

Our findings show that chest radiographs are more sensitive than ECG for LVH detection in hypertensive patients, in

accordance with Kannel et al.¹⁹ On the other hand Drayer and Zegarelli¹⁸ reported that LVH can be more accurately evaluated by ECG than by physical exam or chest radiograph. However, the authors used only the cardiothoracic ratio.

Most of studies using radiographic exam limited to a single view for evaluation of the cardiothoracic ratio, have indicated that chest radiograph and ECG, separately, present very limited value in LVH diagnosis^{12,13,15-17,36-38}. However, the combination of both could constitute a good method for LVH diagnosis at the primary level of health care, which was demonstrated in this study.

Echo provides numerous additional parameters on cardiac geometry and performance without the disadvantage of ionizing radiation, which despite of being very low is present on chest radiograph. However, echocardiograms are not available for every patient with arterial hypertension. This matter is pertinent not only in underdeveloped countries but also, as has been reported in developed ones^{4,30,39}. Echo presents some limitations in patients with inadequate acoustic window as observed in some cases of Chronic Obstructive Pulmonary Disease or obesity. Magnetic Resonance Imaging does not present such limitations, and is, nowadays, the best method to evaluate LVH. However, it is too expensive for routine use or in public health programs for early detection of LVH in hypertensive patients.

The high sensitivity in detection of aortal enlargement is a finding that should receive greater priority in the hypertensive patient, even when without any other radiological alteration, given its association with LVH in about half of them. Thus, an augmented aorta in the chest radiograph of a hypertensive patient might be considered an important marker of hypertensive heart disease. This would constitute a situation where Echo would be prioritized. Furthermore, radiological standardization of normal aortal dimensions, according to age and gender, and its validation with other gold standard image method would make chest radiograph even more sensitive for detection of aortal dilatation and even as a radiological marker of LVH in hypertensive patients.

Simone et al.⁴⁰ claimed that the generalized use of Echo to detect LV hypertrophy would double the cost of the initial work-up for arterial hypertension (including ECG), a burden that needs to be proven useful and of additional value in terms of information needed to guide physicians' decisions for patient management. With present knowledge, the Echo does not add critical information for decision-making when other information on cardiovascular risk factors and target organ damage already mandates classification of patients in the high or very high-risk rank.⁴⁰ Therefore, if LVH is detected by chest radiography or ECG it should be assumed as an indication of cardiac damage, even before accomplishing Echo.

Conclusions

We conclude that the accuracy of chest radiography plus ECG for diagnosis of LVH is sufficient to justify its use in the initial evaluation of hypertensive patients. The cardiothoracic ratio presents very low sensitivity for detecting LVH. Radiographic cardiac examination must always be accomplished with at least two basic views, frontal and lateral. The addition of oblique views does

not improve the accuracy of the exam for detection of enlarged dimensions in the left ventricle and left atrium, and aorta dilatation is an important marker of LVH in chest radiographs. Therefore, because these exams are inexpensive and easily available in primary care centers, it is our opinion that two-view chest radiograph along with the 12-lead electrocardiogram should be included in the routine initial approach to hypertensive patients. Thus, it should be valorized mainly the sensibility of chest radiography related to the direct signs of left ventricle hypertrophy/enlargement and the enlargement of the aorta and the high specificity of the cardiothoracic ratio and Electrocardiogram.

References

1. Devereux RB, Bella J, Boman K, Gerds E, Nieminen MS, Rokkedal J, et al. Echocardiographic left ventricular geometry in hypertensive patients with electrocardiographic left ventricular hypertrophy: The LIFE Study. *Blood Press*. 2001;10(2):74-82.
2. Kristensen BO. Assessment of left ventricular hypertrophy by electrocardiography, chest roentgenography and echocardiography, a review. *Scand J Clin Lab Invest Suppl*. 1989;196:42-7.
3. Cifkova R, Erdine S, Fagard R, Farsang R, Heagerty AM, Kiowski W, et al. Practice guidelines for primary care physicians: 2003 ESH/ESC hypertension guidelines. *J Hypertens*. 2003;21(10):1779-86.
4. 1999 World Health Organization – International Society of Hypertension Guidelines for the Management of Hypertension. Guidelines Subcommittee. *J Hypertens*. 1999;17(2):151-83.
5. Rautaharju PM, LaCroix AZ, Savage DD, Haynes SG, Madans JH, Wolf HK, et al. Electrocardiographic estimate of left ventricular mass versus radiographic cardiac size and the risk of cardiovascular disease mortality in the epidemiologic follow-up study of the First National Health and Nutrition Examination Survey. *Am J Cardiol*. 1988;62(1):59-66.
6. Gabás JLD, Abad AA, Aznar TL, Tirado AF, Santamaría MTA, Pomar CI. Valor del electrocardiograma y de la radiografía de tórax para el diagnóstico de la hipertrofia ventricular izquierda en pacientes con hipertensión arterial. *Hipertensión*. 1992;9(8):326-30.
7. Keats TE. Atlas of roentgenographic measurement. 6th ed. St Louis: Mosby Year Book; 1990.
8. Romhilt DW, Estes EH Jr. A point-score system for the ECG diagnosis of left ventricular hypertrophy. *Am Heart J*. 1968;75(6):752-8.
9. Lang RM, Bierig M, Devereux RB, Flachskampf FA, Foster E, Pellikka PA, et al. ASE committee recommendations. Recommendations for chamber quantification: a report from the American Society of Echocardiography's Guidelines and standards committee and the chamber quantification writing group, developed in conjunction with the European Association of Echocardiography, a branch of the European Society of Cardiology. *J Am Soc Echocardiogr*. 2005;18(12):1440-63.
10. Feigenbaum H, Armstrong WF, Ayan T. Evaluation of systolic and diastolic function of the left ventricle. In: Feigenbaum H, Armstrong WF, Ayan T (eds). *Feigenbaum's echocardiography*. Philadelphia: Lippincott Williams & Wilkins; 2005. p. 138-90.
11. Levy D, Anderson KM, Savage DD, Kannel WB, Christiansen JC, Castelli WP. Echocardiographically detected left ventricular hypertrophy: prevalence and risk factors. The Framingham Heart Study. *Ann Intern Med*. 1988;108(1):7-13.
12. Hammond IW, Devereux RB, Alderman MH, Lutas EM, Spitzer MC, Crowley JS, et al. The prevalence and correlates of echocardiographic left ventricular hypertrophy among employed patients with uncomplicated hypertension. *J Am Coll Cardiol*. 1986;7(3):639-50.
13. Roman MJ, Pickering TG, Schwartz JE, Pini R, Devereux RB. Relation of arterial structure and function to left ventricular geometric patterns in hypertensive adults. *J Am Coll Cardiol*. 1996;28(3):751-6.
14. Osborn LA, Abrams J. Pseudocardiomegaly: causes, diagnosis and management. *Internal Medicine*. 1987;8:45-8.
15. Pisarczyk MJ, Ross AM. Cardiac measurements in hypertension: echocardiogram, electrocardiogram and X-ray comparison. *Am J Cardiol*. 1976;37:162-5.
16. Iacovino JR. Underwriting left ventricular hypertrophy – a review of the medical literature with an emphasis on mortality and morbidity. *J Insur Med*. 1992;24(4):256-61.
17. Ungerleider HR, Clark CP. A study of the transverse diameter of the heart silhouette with predictive tables based on the teleroentgenogram. *Trans Assoc Life Insur Med Dir Am*. 1938;25:84-103.
18. Drayer JL, Zegarelli EC. Echocardiographic detection of left ventricular hypertrophy: its usefulness as a prognostic tool in hypertensive patients. *Chest*. 1987;92(5):923-5.
19. Kannel WB, Gordon T, Offutt D. Left ventricular hypertrophy by electrocardiogram: prevalence, incidence, and mortality in the Framingham study. *Ann Intern Med*. 1969;71(1):89-101.
20. Kannel WB, Danenberg AL, Levy D. Population implications of electrocardiographic left ventricular hypertrophy. *Am J Cardiol*. 1987;60(17):851-931.
21. Eyer WR, Wayne DL, Rhodenbaugh JE. The importance of the lateral view in the evaluation of left ventricular enlargement in rheumatic heart disease. *Radiology*. 1959;73(1):56-61.
22. Hoffman RB, Rigler LG. Evaluation of left ventricular enlargement in the lateral projection of the chest. *Radiology*. 1965;85:93-100.
23. Rose CP, Stolberg HO. The limited utility of the plain chest film in the assessment of left ventricular structure and function. *Invest Radiol*. 1982;17(2):139-44.
24. Chikos PM, Figley MM, Fisher L. Correlation between chest film and angiographic assessment of left ventricular size. *AJR Am J Roentgenol*. 1977;128(3):367-73.
25. Dinsmore RE, Goodman DJ, Sanders CA. Some pitfalls in the evaluation of cardiac chamber enlargement on chest roentgenograms. *Radiology*. 1966;87(2):267-73.

Potential Conflict of Interest

No potential conflict of interest relevant to this article was reported.

Sources of Funding

This study was funded by Fundação de Amparo à Pesquisa do Estado de São Paulo - FAPESP 2004/ 09460-5].

Study Association

This article is part of the doctoral thesis submitted by Sergio Marrone Ribeiro, from Faculdade de Medicina de Botucatu - UNESP.

26. Chikos PM, Figley MM, Fisher L. Visual assessment of total heart volume and specific chamber size from standard chest radiographs. *AJR Am J Roentgenol.* 1977;128(3):375-80.
27. Levin AR, Frand M, Baltaxe HA. Left atrial enlargement: correlation of left atrial volume with cardiac series, ciné-esophagography, and electrocardiography. *Radiology.* 1972;104(3):615-21.
28. Kim M, Roman MJ, Cavallini MC, Schwarts JE, Pickering TG, Devereux RB. Effect of hypertension on aortic root size and prevalence of aortic regurgitation. *Hypertension.* 1996;28(1):47-52.
29. Rayner BL, Goodman H, Opie LH. The chest radiograph: a useful investigation in the evaluation of hypertensive patients. *Am J Hypertens.* 2004;17(6):507-10.
30. Ang D, Lang C. The prognostic value of the ECG in hypertension: where are we now? *J Hum Hypertens.* 2008;22(7):460-7.
31. Reichek N, Devereux RB. Left ventricular hypertrophy: Relationship of anatomic, echocardiographic and electrocardiographic findings. *Circulation.* 1981;63(6):1391-407.
32. Levy D, Labib SB, Anderson KM, Christiansen JC, Kannel WB, Castelli WP. Determinants of sensitivity and specificity of electrocardiographic criteria for left ventricular hypertrophy. *Circulation.* 1990;81(3):815-20.
33. Levy D, Savage DD, Garrison RJ, Anderson KM, Kannel WB, Castelli WP. Echocardiographic criteria for left ventricular hypertrophy: the Framingham Heart Study. *Am J Cardiol.* 1987;59(9):956-60.
34. Casale PN, Devereux RB, Kligfield P, Eisenberg RR, Miller DH, Chaudhary BS, et al. Electrocardiographic detection of left ventricular hypertrophy: development and prospective validation of improved criteria. *J Am Coll Cardiol.* 1985;6(3):572-80.
35. Devereux RB, Casale PN, Eisenberg RR, Miller DH, Kligfield P. Electrocardiographic detection of left ventricular hypertrophy using echocardiographic determination of left ventricular mass as the reference standard: Comparison of standard criteria, computer diagnosis and physician interpretation. *J Am Coll Cardiol.* 1984;3(1):82-7.
36. Nunez BD, Garavaglia GE, Messerli FH. Noninvasive diagnosis of left ventricular hypertrophy. *Pract Cardiol.* 1987; 13:62-75.
37. Kannel WB, Cobb J. Left ventricular hypertrophy and mortality: results from the Framingham Study. *Cardiology.* 1992;81(4-5):291-8.
38. Miller JT, O'Rourke RA, Crawford MH. Left atrial enlargement: an early sign of hypertensive heart disease. *Am Heart J.* 1988;116(4):1048-51.
39. Cía P, Rodés PM, Poncel A, Blasco M, Altisent R, Remacha PPO, et al. Prevalencia de hipertensión arterial en Aragón. *Hipertension.* 1990;7:59-65.
40. de Simone G, Schillaci G, Palmieri V, Devereux RB. Should all patients with hypertension have echocardiography? *J Hum Hypertens.* 2000;14(7):417-21.

